

# $\beta$ -amyloid (A $\beta$ ) deposition in cognitively normal brain, dementia with Lewy bodies, and Alzheimer's disease: a study using principal components analysis

Richard A. Armstrong

Vision Sciences, Aston University, Birmingham B4 7ET, UK

*Folia Neuropathol* 2012; 50 (2): 130-139

## Abstract

The densities of diffuse, primitive, and classic  $\beta$ -amyloid (A $\beta$ ) deposits were studied in the temporal lobe in cognitively normal brain, dementia with Lewy bodies (DLB), familial Alzheimer's disease (FAD), and sporadic AD (SAD). Principal components analysis (PCA) was used to determine whether there were distinct differences between groups or whether A $\beta$  pathology was more continuously distributed from group to group. Three principal components (PC) were extracted from the data accounting for 56% of the total variance. Plots of cases in relation to the PC did not result in distinct groups but suggested overlap in A $\beta$  deposition between the groups. In addition, there were linear correlations between the densities of A $\beta$  deposits and the distribution of the cases along the PC in specific brain regions suggesting continuous variation from group to group. PC1 was associated with the degree of maturation of A $\beta$  deposits, PC2 with differences between FAD and SAD, and PC3 with the degree of spread of A $\beta$  pathology into the hippocampus. Apolipoprotein E (APOE) genotype was not associated with variation in A $\beta$  deposition between cases. PCA may be a useful method of studying the pathological interface between closely related neurodegenerative disorders.

**Key words:** cognitively normal brain, dementia with Lewy bodies (DLB), Alzheimer's disease (AD),  $\beta$ -amyloid (A $\beta$ ) deposits, principal components analysis (PCA).

## Introduction

Studies have suggested a significant degree of 'overlap' or 'interface' between cognitively normal brain, dementia with Lewy bodies (DLB), and Alzheimer's disease (AD) [6,11,23,24]. Hence, several aspects of AD pathology can be observed in normal aged brain. There is an age-related reduction in brain volume and weight, enlargement of ventricles, and loss of synapses and dendrites in selected areas of normal brain [35]. These changes are accompanied by

many of the histological features of AD, viz., senile plaques (SP) and neurofibrillary tangles (NFT) [1,5]. The major molecular constituent of the SP is  $\beta$ -amyloid (A $\beta$ ) [23] and hence, A $\beta$  deposition in the form of diffuse ('pre-amyloid'), primitive ('neuritic') [27,28], and classic ('dense-cored') deposits is often regarded as a 'signature' pathological feature of AD [20,30]. Nevertheless, studies have also demonstrated an overlap in A $\beta$  deposition between AD and normal brain [2,21,40].

## Communicating author:

Dr. R.A. Armstrong, Vision Sciences, Aston University, Birmingham B4 7ET, UK, phone 0121-359-3611, fax 0121-333-4220, e-mail: R.A.Armstrong@aston.ac.uk

Lewy bodies presents with early frontal dementia, cognitive fluctuations, visual hallucinations, syncope, delusions, and rapid eye movement disorder [37]. The clinical and pathological features of DLB may also overlap with AD [24,38] and this potential interface may give rise to difficulties in clinical diagnosis. For example, in a study of 27 clinically diagnosed cases of AD, six were found to have DLB by subsequent pathological examination [43]. An essential feature of the pathological diagnosis of DLB is the presence of α-synuclein-immunoreactive Lewy bodies (LB) in the cerebral cortex and/or brain stem [41]. In addition, many cases of DLB exhibit AD pathology including the presence of SP and NFT [9,22,26,34]. In some DLB cases, the density of SP may be sufficient for a diagnosis of AD using ‘Consortium to Establish a Registry for Alzheimer’s disease’ (CERAD) criteria [42] and these cases are often regarded as examples of ‘mixed’ or ‘multiple pathologies’ [50].

The present study compared the densities of diffuse, primitive, and classic Aβ deposits in regions of

the temporal lobe in cognitively normal brain, DLB, familial AD (FAD), and sporadic AD (SAD). The specific objectives were: (1) to determine whether there were distinct differences between groups or whether Aβ pathology was more continuously distributed from group to group and (2) to identify the most important sources of variation in Aβ pathology between patient groups.

## Material and methods

### Cases

Cases (*N* = 36, details in Table I) were obtained from the Brain Bank, Department of Neuropathology, Institute of Psychiatry, King’s College, London. Informed consent was given for the removal of all tissue and followed the principles embodied in the 1964 Helsinki declaration (as modified Edinburgh, 2000). Post-mortem delay was less than 20 hours in each case. The control cases (*N* = 8) had no neurological or psychiatric his-

**Table I.** Demographic data, cause of death, and apolipoprotein E (APOE) genotype of the cases studied

| Case | Group   | Sex | Age | Onset | Cause of death               | APOE |
|------|---------|-----|-----|-------|------------------------------|------|
| 1    | Control | M   | 64  | –     | Pulmonary oedema             | 2/3  |
| 2    | Control | F   | 71  | –     | Bronchopneumonia             | 3/3  |
| 3    | Control | M   | 72  | –     | Gastrointestinal haemorrhage | 3/3  |
| 4    | Control | M   | 80  | –     | Ischaemic heart disease      | 3/4  |
| 5    | Control | F   | 80  | –     | Postoperative haemorrhage    | 3/3  |
| 6    | Control | F   | 83  | –     | Right femur fracture         | 4/4  |
| 7    | Control | M   | 84  | –     | Peritonitis                  | 3/3  |
| 8    | Control | M   | 85  | –     | Ischaemic heart disease      | 3/3  |
| 9    | DLB*    | M   | 70  | 65    | NA                           | 3/3  |
| 10   | DLB     | M   | 72  | ND    | Shock/Hypothermia            | –    |
| 11   | DLB*    | M   | 68  | ND    | Bronchopneumonia             | 3/3  |
| 12   | DLB*    | M   | 77  | 74    | Bronchopneumonia             | –    |
| 13   | DLB     | M   | 69  | ND    | Bronchopneumonia             | –    |
| 14   | DLB     | M   | 58  | 51    | Bronchopneumonia             | 3/4  |
| 15   | DLB     | M   | 71  | 68    | Myocardial infarction        | 3/3  |
| 16   | FAD     | F   | 93  | 91    | NA                           | –    |
| 17   | FAD     | F   | 85  | 76    | Bronchopneumonia             | 3/4  |
| 18   | FAD     | F   | 79  | 68    | Bronchopneumonia             | –    |

Table I. Cont.

| Case | Group       | Sex | Age | Onset | Cause of death        | APOE |
|------|-------------|-----|-----|-------|-----------------------|------|
| 19   | FAD         | F   | 77  | 72    | Bronchopneumonia      | 3/4  |
| 20   | FAD         | F   | 86  | 80    | Bronchopneumonia      | 3/3  |
| 21   | FAD (PSEN1) | F   | 40  | 35    | NA                    | –    |
| 22   | SAD         | F   | 93  | 91    | Bronchopneumonia      | 3/4  |
| 23   | SAD         | F   | 91  | 85    | Bronchopneumonia      | –    |
| 24   | SAD         | M   | 86  | 83    | Bronchopneumonia      | –    |
| 25   | SAD         | F   | 88  | 72    | Bronchopneumonia      | –    |
| 26   | SAD         | F   | 81  | 77    | Bronchopneumonia      | 3/4  |
| 27   | SAD         | F   | 85  | 80    | Bronchopneumonia      | 3/3  |
| 28   | SAD         | F   | 64  | 59    | Bronchopneumonia      | 2/3  |
| 29   | SAD         | F   | 80  | 77    | Bronchopneumonia      | –    |
| 30   | SAD         | F   | 70  | 64    | Bronchopneumonia      | 3/4  |
| 31   | SAD         | F   | 66  | 59    | Bronchopneumonia      | –    |
| 32   | SAD         | F   | 82  | 75    | Bronchopneumonia      | –    |
| 33   | SAD         | F   | 87  | 82    | Myocardial infarction | 3/3  |
| 34   | SAD         | M   | 73  | 66    | Bronchopneumonia      | –    |
| 35   | SAD         | M   | 82  | 78    | Bronchopneumonia      | 3/4  |
| 36   | SAD         | F   | 91  | 83    | Bronchopneumonia      | –    |

DLB – dementia with Lewy bodies, FAD – familial Alzheimer's disease, SAD – sporadic Alzheimer's disease, PSEN1 – Presenilin 1, M – Male, F – Female, NA – data not available

\* Indicates 'pure' DLB with little associated AD pathology, (–) indicates not determined

tories and were matched as closely as possible for age to the AD and DLB cases. The AD cases ( $N = 21$ ) were clinically assessed and all fulfilled the 'National Institute of Neurological and Communicative Disorders and Stroke' and 'Alzheimer's Disease and Related Disorders Association' (NINCDS/ADRDA) criteria for probable AD [49]. The histological diagnosis of AD was established by the presence of widespread neocortical senile plaques (SP) consistent with the 'Consortium to Establish a Registry for Alzheimer's Disease' (CERAD) criteria [42]. In addition, neurofibrillary tangles (NFT) were abundant in the cerebral cortex and hippocampus [5]. Six of the AD cases were familial [7], with two or more generations affected, one of which was linked to a mutation of the *presenilin* (*PSEN*) gene *PSEN1* [45]. The remaining FAD cases were not associated with mutations of either amyloid precursor protein (*APP*) or

*PSEN* genes [7,19,31,45]. DLB cases ( $N = 7$ ) were diagnosed according to the 'Consortium on Dementia with Lewy bodies' (CDLB) guidelines [41]. Three of these cases had significantly less A $\beta$  deposits than the others and were diagnosed as 'pure' DLB [22,26,34]. Apolipoprotein (*APOE*) genotype, which also influences A $\beta$  deposition [16,18,25], was determined for 22/36 cases studied.

### Tissue preparation

A block of the temporal lobe, at the level of the lateral geniculate body, was taken from each case and it included the inferior temporal gyrus (ITG), the parahippocampal gyrus (PHG), hippocampus (HC), and dentate gyrus (DG). Tissue was fixed in 10% phosphate buffered formal-saline and embedded in paraffin wax. 7  $\mu$ m coronal sections were stained with a rab-

bit polyclonal antibody (Gift of Prof. B.H. Anderton, Institute of Psychiatry, King's College London) raised to the 12-28 amino acid sequence of the A $\beta$  protein [46]. The antibody was used at a dilution of 1 in 1200 and the sections incubated at 4°C overnight. Sections were pretreated with 98% formic acid for 6 minutes which enhances A $\beta$  immunoreactivity. A $\beta$  was visualised using the streptavidin-biotin horseradish peroxidase procedure with diaminobenzidine as the chromogen. Sections were also stained with haematoxylin. The three most common morphological subtypes of A $\beta$  deposit were identified in the sections using previously defined criteria [4,21]. Hence, diffuse deposits were 10-200  $\mu$ m in diameter, irregular in shape with diffuse boundaries, and lightly stained. Large confluent patches of A $\beta$  immunostaining, which could be a variant of diffuse deposit, were not quantified. Primitive deposits were 20-60  $\mu$ m, well demarcated, more symmetrical in shape, and strongly stained and may be analogous to neuritic plaques, the predominant type of plaque in AD [27,28]. Classic deposits were 20-100  $\mu$ m, had a distinct central 'core' surrounded by a 'corona' of dystrophic neurites.

### Morphometric methods

In the ITG and PHG, a strip of cortex 17600 to 25600  $\mu$ m in length, and which included a sulcus and a gyrus, was studied using 1000  $\times$  200  $\mu$ m contiguous sample fields, the short dimension of the field being aligned with the surface of the pia mater. Hence, the plot included laminae I, II, and most of III, the region containing the highest densities of A $\beta$  deposits in AD [3]. Between 64 and 128 contiguous sample fields were used to sample each gyrus. A micrometer grid with grid lines at intervals of 10  $\mu$ m was used as the sample field. In the HC, the sample fields were arranged parallel to the alveus to sample sectors CA1, CA2, and CA3. Sampling was then continued into sector CA4 using a guideline marked on the slide and which ceased approximately 400  $\mu$ m from the DG granule cell layer. In the DG, the lower edge of the sample field was aligned with the top of the granule cell layer as most A $\beta$  deposits were located within the molecular layer. The number of diffuse, primitive, and classic A $\beta$  deposits was counted manually in each field.

### Data analysis

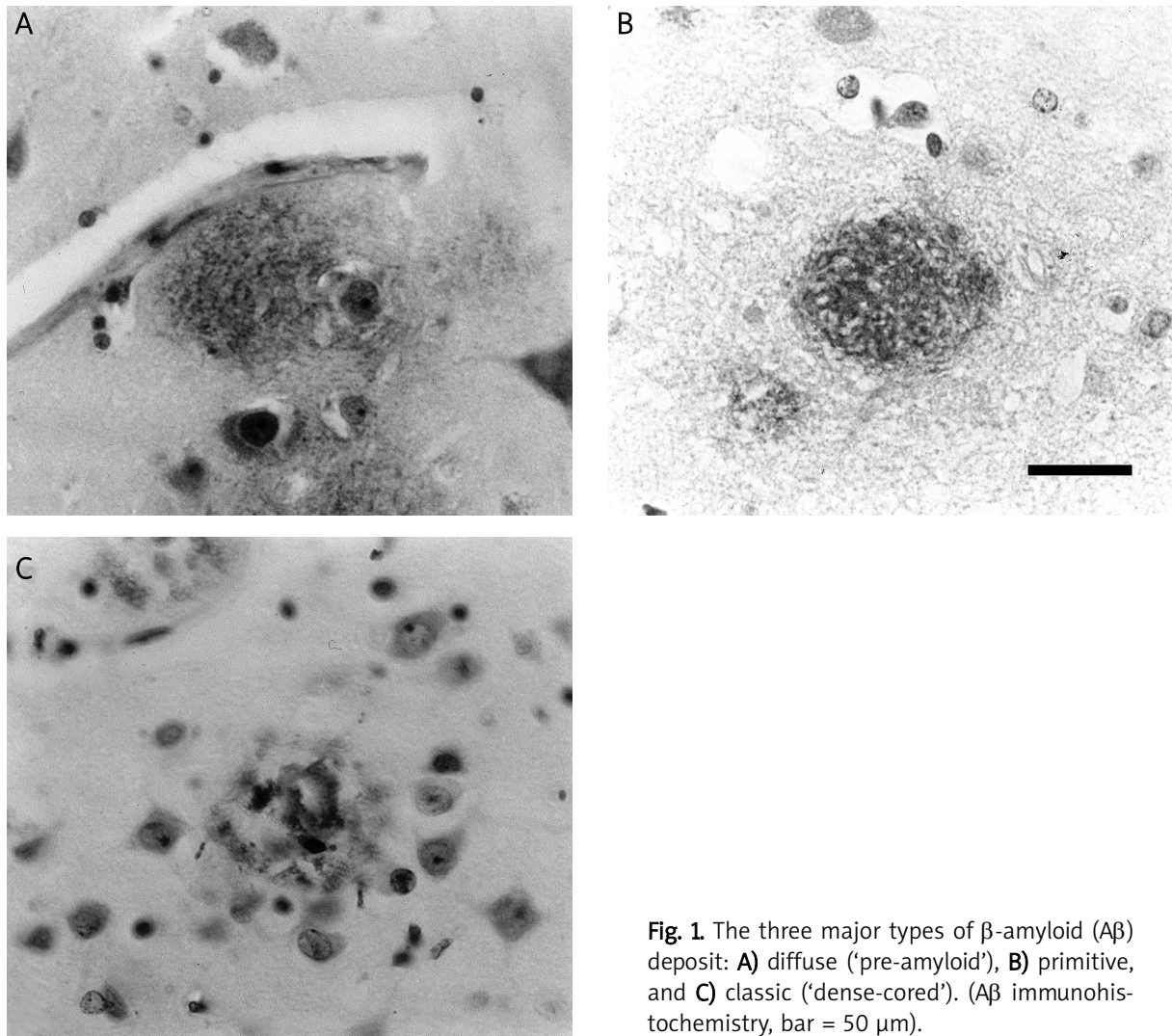
Variations in the density and distribution of A $\beta$  deposits in the temporal lobe of the 36 cases were analysed

using PCA. PCA measures the degree of similarity between cases (the variables) based on their neuropathological characteristics [10,12,13]. Hence, each case is defined by the density of diffuse, primitive, and classic A $\beta$  deposits in seven regions of the temporal lobe (viz., ITG, PHG, CA1, CA2, CA3, CA4, DG). Preliminary analysis suggested a degree of skew and kurtosis was present indicating a degree of non-normality in the data. Hence, PCA was carried out on the original data and on the data transformed to logarithms [12]. Initially, all PC were extracted which had eigenvalues ( $\lambda$ ) > 1 but usually in a PCA, only the first three PC account for significant proportions of the original variance [10]. The result of each PCA is a scatter plot of the 36 cases in relation to the extracted PC in which the distance between cases reflects their degree of similarity or dissimilarity. Hence, if there were distinct differences in A $\beta$  pathology between groups, discrete clusters of cases would be present whereas a more continuous distribution of cases suggests overlapping pathology or a continuum. The PC account for significant proportions of variance in the data, PC1 for the most significant source of variation and PC2 and PC3 for diminishing proportions of the remaining variance. Hence, to identify those aspects of A $\beta$  deposition which may account for this variance, correlations (Pearson's 'r') were calculated between the 'loadings' (the coordinates of the case in relation to the PCs) of each case on the PC and A $\beta$  deposit density, age at death, disease duration, and *APOE* genotype 'score' (the sum of the two alleles) in each region.

### Results

Examples of diffuse, primitive, and classic A $\beta$  deposits are shown in Fig. 1. Typically, diffuse deposits (Fig. 1A) are irregular in shape with diffuse boundaries, and lightly stained. In contrast, primitive deposits (Fig. 1B) are well demarcated, more symmetrical in shape, and strongly stained while classic deposits (Fig. 1C) have a distinct central 'core', usually incorporating one or more neuronal perikarya, and are surrounded by a 'corona' of dystrophic neurites.

Similar PCA results were obtained using untransformed and transformed data and only the results of the analysis of the original data are reported here. The first three PC extracted from the data accounted for 55.6% of the total variance (PC1 = 27.56%, PC2 = 15.07%, PC3 = 12.97%). The loadings of the cases in relation to PC1 and PC2 and PC2 and PC3 are shown in Figs. 2 and 3, respectively. No distinct groupings

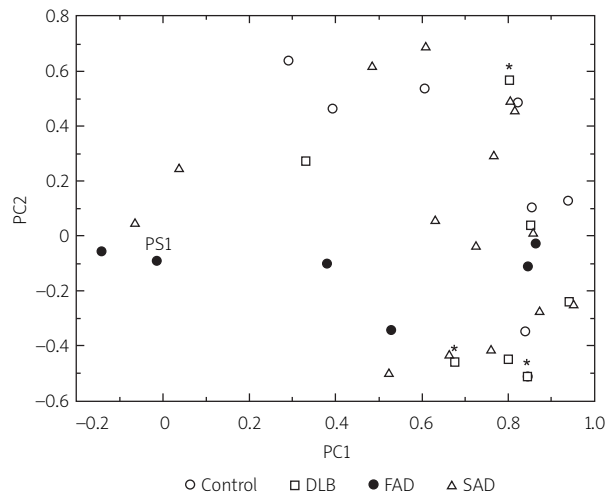


**Fig. 1.** The three major types of  $\beta$ -amyloid ( $A\beta$ ) deposit: **A)** diffuse ('pre-amyloid'), **B)** primitive, and **C)** classic ('dense-cored'). ( $A\beta$  immunohistochemistry, bar = 50  $\mu$ m).

of cases were evident on either plot suggesting considerable overlap in  $A\beta$  deposition between cognitively normal cases, DLB, and AD. In the PC1/2 plot (Fig. 2), the control and DLB cases, especially those designated as 'pure' DLB, exhibited high loadings on PC1 but overlapped extensively with the AD cases, which showed a wide distribution over the plot. In addition, the FAD and SAD cases did not appear to cluster in relation to PC1 and PC2, but the FAD cases as a group had consistently lower loadings on PC2 compared with the SAD cases which appear more heterogeneous. FAD cases also exhibited relatively low loadings on PC2 (Fig. 3) including the case linked to a *PSEN1* mutation. A proportion of the FAD cases also exhibited high loadings on PC3.

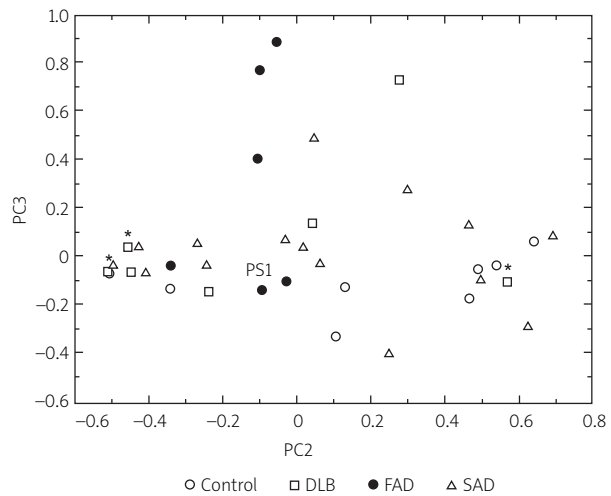
Linear correlations between the extracted PC and the neuropathological variables are shown in Table II.

The density of diffuse  $A\beta$  deposits in the ITG ( $r = 0.44$ ,  $P < 0.01$ ) and PHG ( $r = 0.36$ ,  $P < 0.05$ ) were positively correlated with PC1 while the densities of primitive deposits in sector CA3 ( $r = -0.48$ ,  $P < 0.01$ ) and classic deposits in sector CA4 ( $r = -0.48$ ,  $P < 0.01$ ) were negatively correlated with PC1. The densities of the primitive deposits in the ITG ( $r = 0.55$ ,  $P < 0.001$ ) and PHG ( $r = 0.59$ ,  $P < 0.001$ ) and classic deposits in the PHG ( $r = 0.35$ ,  $P < 0.05$ ) were positively correlated with PC2. The density of the diffuse deposits in sector CA1 was positively correlated with PC3 ( $r = 0.36$ ,  $P < 0.05$ ) while the densities of the primitive deposits in sectors CA1 ( $r = 0.72$ ,  $P < 0.001$ ) and CA2 ( $r = 0.58$ ,  $P < 0.001$ ) and DG ( $r = 0.62$ ,  $P < 0.001$ ) were positively correlated with PC3. The density of the classic deposits was negatively correlated with PC3 in the ITG ( $r = -0.35$ ,  $P < 0.05$ ) and



PS1 – Familial AD case linked to presenilin 1 mutation. \* Indicates ‘pure’ DLB cases with relatively little AD pathology.

**Fig. 2.** Principal components analysis of β-amyloid (Aβ) deposition in the temporal lobe in cognitively normal cases, dementia with Lewy bodies, and Alzheimer’s disease. A plot of the cases in relation to PC1 and PC2.



PS1 – Familial AD case linked to presenilin 1 mutation. \* Indicate ‘pure’ DLB cases with relatively little AD pathology.

**Fig. 3.** Principal components analysis of β-amyloid (Aβ) deposition in the temporal lobe in cognitively normal cases, dementia with Lewy bodies, and Alzheimer’s disease. A plot of the cases in relation to PC2 and PC3.

positively correlated with PC3 in sector CA2 ( $r = 0.43$ ,  $P < 0.01$ ). In addition, disease duration was positively correlated with PC3 ( $r = 0.40$ ,  $P < 0.05$ ). No significant correlations were observed between the extracted PC and APOE score (PC1:  $r = 0.30$ ,  $P > 0.05$ ; PC2:  $r = 0.09$ ,  $P > 0.05$ ; PC3:  $r = -0.05$ ,  $P > 0.05$ ).

### Discussion

The objective of this study was to determine whether cognitively normal cases, DLB, FAD, and SAD could be easily distinguished based on the densities of Aβ deposits in the temporal lobe. The PCA suggested: (1) no clear separation of cases into groups and (2) linear correlations in specific regions between the densities of Aβ deposits and the distribution of cases in relation to the PCA. These data suggest continuous change in Aβ density from group to group rather than distinct differences between groups.

Previous studies have reported overlaps in SP or Aβ deposit density between cognitively normal brain and AD. Hence, the distribution of SP was studied in 60 normal elderly cases [39] and it was concluded that it was not possible to distinguish the early stages of AD from

normal aging on the basis of SP density alone. Similarly, Bergeron *et al.* [17] observed SP in 60% of normal elderly cases, albeit at a lower density than in AD. Moreover, Arrigada *et al.* [14] reported SP in most normal individuals older than 55 years and concluded there may be a ‘continuum’ of pathological change between elderly non-demented brains, early stage AD, and more advanced AD. Aβ deposits are also present in non-demented individuals older than 60 years but are rare before this age [27,40]. In 14 non-demented elderly cases [2], for example, Aβ deposits were present in the temporal lobe in eight cases, with a considerable variation in the density of deposits in control cases and significantly overlapping with AD. By contrast, Gibson [29] studied 119 cases of aging and AD and found amyloid deposits in greater numbers in AD than in normal aging.

The PCA also suggested overlap in Aβ deposition between DLB, cognitively normal brain, and AD. DLB exists in a multiplicity of forms including neocortical, limbic, cerebral, and brainstem types, the neocortical type being the most prevalent [36]. In addition, many cases of DLB exhibit AD pathology including the presence of SP and NFT [22,26,34] with sufficient densi-

**Table II.** Correlations (Pearson's '*r*') between the densities of A $\beta$  deposits in the temporal lobe, age at death, disease duration, and apolipoprotein E (APOE) score (sum of the two alleles) and the first three principal components (PC)

| Region | Deposit   | PC1     | PC2     | PC3     |
|--------|-----------|---------|---------|---------|
| ITG    | Diffuse   | 0.44**  | -0.20   | 0.14    |
| ITG    | Primitive | 0.24    | 0.55*** | 0.15    |
| ITG    | Classic   | -0.08   | 0.24    | -0.35*  |
| PHG    | Diffuse   | 0.36*   | -0.14   | -0.11   |
| PHG    | Primitive | 0.24    | 0.59*** | 0.02    |
| PHG    | Classic   | -0.03   | 0.35*   | -0.31   |
| CA1    | Diffuse   | 0.08    | 0.04    | 0.36*   |
| CA1    | Primitive | -0.23   | 0.04    | 0.72*** |
| CA1    | Classic   | 0.13    | 0.08    | 0.04    |
| CA2    | Diffuse   | 0.09    | -0.10   | 0.17    |
| CA2    | Primitive | -0.16   | -0.11   | 0.58*** |
| CA2    | Classic   | -0.15   | -0.07   | 0.43**  |
| CA3    | Diffuse   | -0.15   | -0.15   | 0.25    |
| CA3    | Primitive | -0.48** | -0.22   | 0.10    |
| CA3    | Classic   | -0.08   | -0.24   | -0.13   |
| CA4    | Diffuse   | -0.20   | 0.06    | -0.22   |
| CA4    | Primitive | -0.20   | -0.27   | -0.01   |
| CA4    | Classic   | -0.48** | -0.10   | 0.29    |
| DG     | Diffuse   | 0.04    | -0.27   | -0.12   |
| DG     | Primitive | -0.22   | 0       | 0.62*** |
| DG     | Classic   | 0       | 0.07    | -0.07   |

ITG – inferior temporal gyrus, PHG – parahippocampal gyrus, CA1-4 – sectors of the hippocampus, DG – dentate gyrus  
Significant correlations \**P* < 0.05, \*\**P* < 0.01, \*\*\**P* < 0.001

ties of SP in some cases for a diagnosis of AD [42]. A $\beta$  deposition has also been recorded in DLB [9] and may be present at levels similar to 'pure' AD. There are specific alterations in the ratio of APP isoforms common to both DLB and AD suggesting that alternate splicing of APP mRNA may play a role in both disorders [15] and which could explain this overlap. The presence of LB in some cases of AD has blurred further the distinction between DLB and AD [33,47]. In a family with

a mutation of the *APP* gene at codon 717 (*APP*<sub>717</sub>), one individual had limbic-type DLB, two had neocortical DLB, while LB were absent in the other family members although all exhibited extrapyramidal features [43]. To date, 53% of post-mortems of individuals with the *APP*<sub>717</sub> mutation have revealed the presence of LB suggesting a direct link between APP and Lewy body formation [43].

PCA identified three axes of variation in A $\beta$  deposition. Hence, PC1 is correlated with variations in density of diffuse deposits in the ITG and PHG, primitive deposits in sector CA3, and classic deposits in sector CA4. Hence, cases with high loadings on PC1, which include the majority of cognitively normal, DLB, and some AD cases, are characterized by diffuse deposits in the ITG and PHG and low densities of primitive and classic deposits in sectors CA3/4. A $\beta$  deposit subtypes could represent different stages in the maturation of a single deposit type [4]. Hence, diffuse deposits may represent the earliest stage of A $\beta$  pathology and evolve into the primitive and classic A $\beta$  deposits as the disease progresses, the primitive ('neuritic') type deposit being the most common in AD [27,28]. Hence, PC1 may be associated with the degree of maturation of A $\beta$  deposits [4], the density of diffuse deposits being greater in control and DLB and more mature deposits in AD [27,28].

PC2 is correlated with variations in density of primitive deposits in the ITG and PHG and classic deposits in the PHG. Hence, cases with high loadings on PC2, which include several SAD, some DLB, and cognitively normal cases, are characterized by high densities of primitive and classic deposits in the ITG and PHG. By contrast, FAD cases exhibit lower densities of primitive and classic deposits in these regions. Hence, PC2 may be associated largely with variation in A $\beta$  deposition between SAD and FAD cases [7].

PC3 is correlated with variations in density of A $\beta$  deposits in sectors CA1/2 of the HC and the DG, cases with low loadings on this axis, which include most control and DLB cases, having zero or low densities of A $\beta$  deposits in these regions. Hence, PC3 is associated with variation in the spread of A $\beta$  pathology into the HC [8]. Disease duration was positively correlated with PC3, i.e., longer duration cases were more likely to have A $\beta$  deposits in the HC and DG, suggesting that this spread may occur later in the disease process. In consequence, control and DLB cases are more likely not to have A $\beta$  deposits in these regions although deposits may be present in gyri adjacent to the HC.

*APOE* genotype was not associated with the PC. *APOE* genotype has been identified as a major risk factor in AD, individuals with AD having 2-3 times the frequency of allele E4 compared with non-demented elderly controls [48]. Allele E4 appears to accelerate the development of AD pathology within the aged brain and hence, is often associated with an earlier onset of the disease [32]. The relationship between the deposition of A $\beta$  deposits and *APOE* genotype is controversial but the majority of studies report increased deposition in individuals expressing allele E4 [16,18,25]. Although the present data suggest some increased A $\beta$  deposition in cases expressing *APOE* allele E4, this source of variation is small compared with that associated with maturation of A $\beta$  deposits, differences between FAD and SAD, and the spread of A $\beta$  deposits into the hippocampus.

In conclusion, changes in the density and distribution of A $\beta$  deposits in the temporal lobe are unlikely to provide a basis for a clear pathological separation of cognitively normal cases, DLB, and AD. Instead, A $\beta$  deposition is more continuously distributed between these groups and cases and three axes of variation were identified: (1) the maturation of diffuse deposits, (2) variation between FAD and SAD, and (3) the spread of A $\beta$  deposits into the HC. *APOE* genotype was not identified as having a significant influence on A $\beta$  deposition in this study. PCA may be a valuable statistical method of studying pathological changes especially in the interface between closely related neurodegenerative disorders [6,11].

## Acknowledgements

The assistance of the Brain Bank, Institute of Psychiatry, King's College London, UK, in providing tissue sections for this study is gratefully acknowledged. We would like to thank Mr Andrew Chadwick and Mrs Mavis Kibble for their excellent technical assistance.

## References

- Anderton BH. Ageing of the brain. *Mech Ageing Dev* 2002; 123: 811-817.
- Armstrong RA. Beta-amyloid deposition in the medial temporal lobe in elderly non-demented brains and in Alzheimer's disease. *Dementia* 1995; 6: 121-125.
- Armstrong RA.  $\beta$ -amyloid (A $\beta$ ) deposits and blood vessels: laminar distribution in the frontal cortex of patients with Alzheimer's disease. *Neurosci Res Commun* 1996; 18: 19-28.
- Armstrong RA.  $\beta$ -amyloid plaques: stages in life history or independent origin? *Dement Geriatr Cogn Disord* 1998; 9: 227-238.
- Armstrong RA. Plaques and tangles and the pathogenesis of Alzheimer's disease. *Folia Neuropathol* 2006; 44: 1-11.
- Armstrong RA. The interface between Alzheimer's disease, normal aging and related disorders. *Current Aging Science* 2008; 1: 122-132.
- Armstrong RA. Spatial patterns of  $\beta$ -amyloid (A $\beta$ ) deposits in familial and sporadic Alzheimer's disease. *Folia Neuropathol* 2011; 49: 153-161.
- Armstrong RA, Myers D, Smith CUM. Alzheimer's disease: size class frequency distribution of senile plaques: do they indicate when a brain tissue was affected? *Neurosci Lett* 1991; 127: 223-226.
- Armstrong RA, Cairns NJ, Lantos PL.  $\beta$ -amyloid (A $\beta$ ) deposition in the medial temporal lobe of patients with dementia with Lewy bodies. *Neurosci Lett* 1997; 227: 193-196.
- Armstrong RA, Nochlin D, Bird TD. Neuropathological heterogeneity in Alzheimer's disease: A study of 80 cases using principal components analysis. *Neuropathology* 2000; 20: 31-37.
- Armstrong RA, Lantos PL, Cairns NJ. Overlap between neurodegenerative disorders. *Neuropathology* 2005; 25: 111-124.
- Armstrong RA, Ellis W, Hamilton RL, Mackenzie IRA, Hedreen J, Gearring M, Montine T, Vonsattel J-P, Head E, Lieberman AP, Cairns NJ. Neuropathological heterogeneity in frontotemporal lobar degeneration with TDP-43 proteinopathy: a quantitative study of 94 cases using principal components analysis. *J Neural Transm* 2010; 117: 227-239.
- Armstrong RA, Hilton A. *Statistical Analysis in Microbiology: Statnotes*. Wiley-Blackwell, Hoboken, New York 2011.
- Arriagada PV, Marzloff K, Hyman BT. Distribution of Alzheimer-type pathologic changes in non-demented elderly individuals matches the pattern in Alzheimer's disease. *Neurology* 1992; 42: 1681-1688.
- Barrachina M, Dalfo E, Ping B, Vidal N, Freixes M, Castano E, Ferrer I. Amyloid-beta deposition in the cerebral cortex in DLB is accompanied by a relative increase in AbetaPP mRNA isoforms containing the Kunitz protease inhibitor. *Neurochem Int* 2005; 46: 253-260.
- Beffert U, Poirier J. Apolipoprotein E, plaques, tangles and cholinergic dysfunction in Alzheimer's disease. *Anns NY Acad Sci* 1996; 777: 166-174.
- Bergeron C, Ranalli PJ and Miceli PN. Amyloid angiopathy in Alzheimer's disease. *Can J Neurol Sci* 1987; 14: 564-569.
- Berr C, Hauw JJ, Delaere P, Duyckaerts C, Amouyel P. Apolipoprotein E allele e4 is linked to increased deposition of the amyloid  $\beta$ -peptide (A $\beta$ ) in cases with or without Alzheimer's disease. *Neurosci Lett* 1994; 178: 221-224.
- Chartier-Harlin MC, Crawford F, Houlden H, Warren A, Hughes D, Fidani L, Goate A, Rossor M, Rocques P, Hardy J, Mullan M. Early onset Alzheimer's disease caused by mutations at codon 717 of the  $\beta$ -amyloid precursor protein gene. *Nature* 1991; 353: 844-846.
- Delaere P, Duyckaerts C, He Y, Piette F, Hauw JJ. Subtypes and differential laminar distribution of  $\beta$ /A4 deposits in Alzheimer's disease: Relationship with the intellectual status of 26 cases. *Acta Neuropathol* 1991; 81: 328-335.
- Delaere P, He Y, Fayet G, Duyckaerts C, Hauw J.  $\beta$ A4 deposits are constant in the brains of the oldest old: An immunocytochemical study of 20 French Centenarians. *Neurobiol Aging* 1993; 14: 191-194.



22. Dickson DW, Ruan D, Crystal H, Mark MH, Davies P, Kress Y, Yen SH. Hippocampal degeneration differentiates diffuse Lewy body disease (DLBD) from Alzheimer's disease: Light and electron microscope immunocytochemistry of CA2-3 neurites specific to DLBD. *Neurology* 1991; 41: 1402-1409.
23. Feany MB, Dickson DW. Neurodegenerative disorders with extensive tau pathology: a comparative study and review. *Ann Neurol* 1986; 40: 139-148.
24. Forstl H. The Lewy body variant of Alzheimer's disease: clinical, pathophysiological and conceptual issues. *Eur Arch Psych Clin Neurol* 1999; 249: 64-67.
25. Gearing M, Schneider JA, Robins RS, Hollister RD, Mori H, Games D, Hyman BT, Mirra SS. Regional variations in the distribution of Apolipoprotein E and A $\beta$  in Alzheimer's disease. *J Neuropath Exp Neurol* 1995; 54: 833-841.
26. Gibb WR, Luthert PJ, Janota I, Lantos PL. Cortical Lewy body dementia: Clinical features and classification. *J Neurol Neurosurg Psychiatr* 1989; 52: 185-192.
27. Gibson PH. Form and distribution of senile plaques seen in silver impregnated sections in the brains of intellectually normal elderly people and people with Alzheimer-type dementia. *Neuropathol Appl Neurobiol* 1983; 9: 379-389.
28. Gibson PH. Relationship between numbers of cortical argentophilic and congophilic senile plaques in the brains of elderly people with and without senile dementia of the Alzheimer type. *Gerontology* 1985; 31: 321-324.
29. Gibson PH. Ultrastructural abnormalities in the cerebral neocortex and hippocampus associated with Alzheimer's disease and aging. *Acta Neuropathol* 1987; 73: 86-91.
30. Glenner GG, Wong CW. Alzheimer's disease and Down's syndrome: sharing of a unique cerebrovascular amyloid fibril protein. *Biochem Biophys Res Commun* 1984; 122: 1131-1135.
31. Goate R, Chartier-Harlin M-C, Mullan M, Brown J, Crawford F, Fidani L, Giuffra L, Haynes A, Irving N, James L, Mant R, Newton P, Rooke K, Roques P, Talbot C, Pericak-Vance, Roses A, Williamson R, Rossor M, Owen M, Hardy J. Segregation of a missense mutation in the amyloid precursor protein gene with familial Alzheimer's disease. *Nature (London)* 1991; 349: 704-706.
32. Gomez-Isla T, West HL, Rebeck GW, Harr SD, Growdon JH, Lacascio JJ, Perls TT, Lipsitz LA, Hyman BT. Clinical and pathological correlates of apolipoprotein E e4 in Alzheimer's disease. *Ann Neurol* 1996; 39: 62-70.
33. Hansen LA, Salmon D, Galasko D, Masliah E, Katzman R, deTeresa R, Thal L, Pay MM, Hofstetter R, Klauber M, Rice V, Butters VN, Alford M. The Lewy body variant of Alzheimer's disease: a clinical and pathological entity. *Neurology* 1990; 40: 1-8.
34. Harrington CR, Perry RH, Perry EK, Hurt J, McKeith JG, Roth M, Wischik CM. Senile dementia of the Lewy body type and Alzheimer type are biochemically distinct in terms of paired helical filaments and hyperphosphorylated tau proteins. *Dementia* 1994; 5: 215-228.
35. Imhof A, Kovari E, von Gunten A, Gold G, Rivara CB, Herrmann FR, Hof PR, Bouras C, Glanakiopoulos P. Morphological substrates of cognitive decline in nonagenarians and centenarians: A new paradigm? *J Neurol Sci* 2007; 257: 72-79.
36. Iseki E, Marin W, Kosaka K, Kato M, Yamamoto T, Ueda K. Clinicopathological multiplicity of dementia with Lewy bodies. *Neuropathol* 1999; 19: 386-394.
37. Lauterbach EC. The neuropsychiatry of Parkinson's disease and related disorders. *Psych Clin N Am* 2004; 27: 801.
38. Lobotesis K, Fenwick JD, Phipps A, Ryman A, Swann A, Ballard C, McKeith IG, O'Brien JT. Occipital hypoperfusion on SPECT in dementia with Lewy bodies but not Alzheimer's disease. *Neurol* 2001; 56: 643-649.
39. Mann DMA, Tucker CM, Yates PO. Topographic distribution of senile plaques, neurofibrillary tangles in the brains of non demented persons of different age. *Neuropath App Neurobiol* 1987; 13: 123-139.
40. Mann DMA, Jones D. Deposition of amyloid A4 protein within the brains of persons with dementing disorders other than Alzheimer's disease and Down's syndrome. *Neurosci Lett* 1990; 109: 68-75.
41. McKeith IG, Galasko D, Kosaka K, Perry EK, Dickson DW, Hansen LA, Salmon DP, Lowe J, Mirra SS, Byrne EJ, Lennox G, Quinn NP, Edwardson JA, Ince PG, Bergeron C, Burns A, Miller BL, Lovestone S, Collerton D, Jansen ENH, Ballard C, de Vos RAI, Wilcock GK, Jellinger KA, Perry RH. Consensus guidelines for the clinical and pathological diagnosis of dementia with Lewy bodies (DLB): Report of the consortium on DLB international workshop. *Neurology* 1996; 47: 1113-1124.
42. Mirra SS, Heyman A, McKeel D, Sumi SM, Crain BJ, Brownlee LM, Vogel FS, Hughes JP, van Belle G and Berg L. The consortium to establish a registry for Alzheimer's disease (CERAD). Part II Standardization of the neuropathologic assessment of Alzheimer's disease. *Neurology* 1991; 41: 479-486.
43. Perneczky R, Mosch D, Neumann M, Kretschmar H, Muller U, Busch R, Forstl H and Kurz A. The Alzheimer variant of Lewy body disease: A pathologically confirmed case-control study. *Demen Ger Cog Dis* 2005; 20: 89-94.
44. Rosenberg CK, Pericak-Vance MA, Saunders AM, Gilbert JR, Gaskell PC and Hulette CM. Lewy body and Alzheimer pathology in a family with the amyloid-beta precursor protein APP717 gene mutation. *Acta Neuropathol* 2000; 100: 145-152.
45. Sherrington R, Rogaev E, Liang Y, Rogaeva E, Levesque G, Ikeda M, Chi H, Lin C, Li G, Holman K, Tsuda T, Mar L, Foncin J, Bruni A, Moulese M, Sorbi S, Rainero I, Pinessi L, Nee L, Chumakov I, Pollen D, Brookes A, Sauseau P, Polinski R, Wasco R, Dasilva H, Haines J, Pericak-Vance M, Tanzi R, Roses A, Fraser P, Rommens J, St George-Hyslop P. Cloning of a gene bearing missense mutations in early onset familial Alzheimer's disease. *Nature* 1993; 375: 754-760.
46. Spargo E, Luthert PJ, Anderton BH, Bruce M, Smith D, Lantos PL. Antibodies raised against different proteins of A4 protein identify a subset of plaques in Down's syndrome. *Neurosci Lett* 1990; 115: 345-350.
47. Szpak GM, Lewandowska E, Lechowicz W, Bertrand E, Wierzba-Bobrowicz T, Gwiazda E, Pasennik E, Kosno-Kruszewska E, Lipczynska-Lozkowska W, Bochynska A, Fiszler U. Lewy body variant of Alzheimer's disease and Alzheimer's disease: a comparative immunocytochemical study. *Folia Neuropathol* 2001; 39: 63-71.
48. Strittmatter WJ, Weisgraber KH, Huang DY, Dong LM, Salvasan GS, Pericak-Vance M, Schmechel D, Saunders AM, Goldgaber D, Roses AD. Binding of human apolipoprotein E to synthetic amyloid- $\beta$  peptide: isoform-specific effects and implications for late-onset Alzheimer's disease. *Proc Natl Acad Sci USA* 1993; 90: 8098-8102.

49. Tierney MC, Fisher RH, Lewis AJ, Zorzitto ML, Snow WG, Reid DW, Nieuwstraten P. The NINCDS-ADRDA work group criteria for the clinical diagnosis of probable Alzheimer's disease. *Neurology* 1988; 38: 359-364.
50. Woodward M, Mackenzie IRA, Hsiung GYR, Jacova C, Feldman H. Multiple brain pathologies in dementia are common. *Eur Ger Med* 2010; 1: 259-265.