

The cerebral form of toxocarosis in a seven-year-old patient

Beata Kazek¹, Ewa Jamroz¹, Marek Mandra², Grażyna Bierzyńska-Macyszyn³, Ewa Kluczevska⁴, Elżbieta Marszał⁴

¹Department of Child Neurology, ²Division of Child Neurosurgery, ³Department of Pathomorphology, ⁴Department of Child Neurology, Medical University of Silesia, Katowice, Poland

Folia Neuropathol 2006; 44 (1): 72-76

Abstract

Introduction: *Toxocarosis is a consequence of human infection by *Toxocara canis* larvae. There are symptomatic (visceral, ocular) and asymptomatic courses of toxocarosis. The cerebral form is very rare.*

Case report: *We present a seven-year-old patient who developed a cerebral form of toxocarosis. She demonstrated focal neurological symptoms (epilepsy) confirmed by neuro-imaging and histopathological examinations. A positive test for toxocarosis essentially completed the other outcomes. On the basis of the clinical picture and the conducted tests a diagnosis of a cerebral form of toxocarosis was established. Mebendazole was applied in treatment.*

Key words: *Toxocara canis, helminthose, larva migrans, cerebral toxocariasis, symptomatic epilepsy, treatment, diagnosis.*

Introduction

The infection of humans by larvae of *Toxocara canis* (dog roundworm) leads to a clinical syndrome called toxocarosis [1-3], one of the most commonly found ascarioses. Its prevalence in people, as determined on the basis of serological examinations, ranges between 1.4% of adult population in Western Europe and 60% of children in developing countries [1,2]. In most humans, *Toxocara canis* infestation takes the asymptomatic course (covert toxocarosis); less frequently it assumes the form of visceral *larva migrans* (VLM) or ocular *larva migrans* (OLM) syndromes [2]. The larvae may invade different tissues and organs including the brain. Symptoms of a cerebral form of toxocarosis are either focal or general, manifested as encephalitis [1]. What accounts

for an occurrence of symptoms is the very presence of the larvae, immune reaction against the parasite antigen, or complications following the treatment applied [2,3]. Here we present a seven-year-old patient who developed a cerebral form of toxocarosis.

Case report

A seven-year-old girl with a negative family history, born from the first pregnancy and normally developed, started reporting abdominal pain. We observed the child's weakness and recurrent irritation. Additional investigations such as complete blood count, aminotransferase, kidney activity test and examinations for parasitic diseases did not reveal any anomalies. The symptoms subsided spontaneously.

Communicating author:

Beata Kazek, Department of Child Neurology, Medical University of Silesia, 40-752, Katowice, ul. Medyków 16, Poland, tel. +48 32 207 16 00, e-mail: neurdziec@slam.katowice.pl

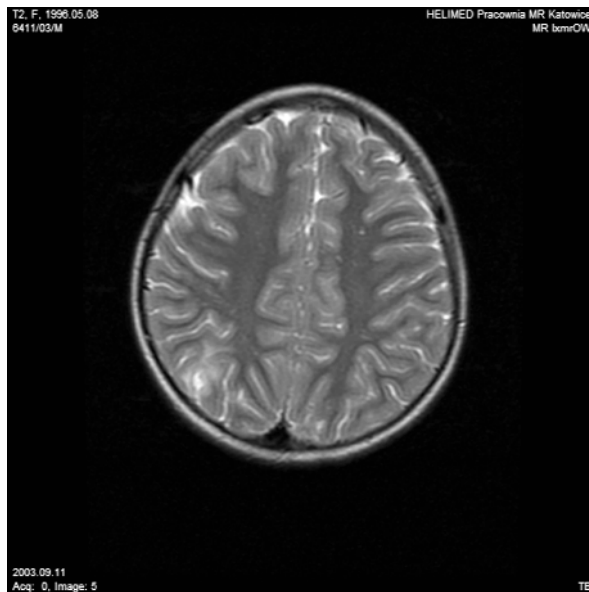


Fig. 1. Axial SE/4340/80 image shows the parenchymal toxocarosis (high signal intensity lesion) and surrounding vasogenic edema in the right parieto-occipital lobe

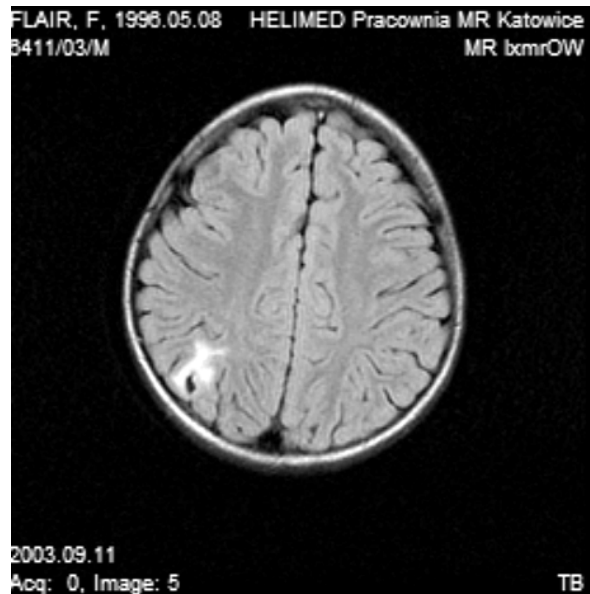


Fig. 2. Axial FLAIR image shows not clearly the toxocarosis lesion but clearly the surrounding vasogenic edema

Two months later there twice occurred a left-side focal epileptic seizure with secondary generalization, leading to paresis of the upper left limb. A physical examination did not reveal any deviations, yet a neurological test showed slight flaccid paresis of the upper left extremity. Epileptic changes, both generalized and localized in the right centrum temporo-occipital region, were visible. CT scan and MRI of the head revealed a heterogeneous low-density area within the white matter and cortex in the right posterior parietal lobe. On the level of this area, the cortical layer was slightly thickened. The contrast medium having been administered, the change under discussion, especially within the cortical layer, became a little intensified; the picture suggested proliferation in progress (Fig. 1-3).

The optic fundus was normal. Laboratory examinations of the peripheral blood attested to the presence of eosinophilia (9%); results of the examination of feces for the presence of eggs and larvae of parasites were negative. The child was thus qualified for a surgery. In anti-epileptic treatment we applied carbamazepine *per os*; there were no further seizures.

The girl was operated on in the Division of Child Neurosurgery. The procedure performed included a right-side parietal craniotomy and a tumor evacuation.

The tumor, morphologically removed from the parietal lobe, had a form of a grey lump 5 mm in diameter, was elastic and had a cavernous space inside. The pathomorphological test conducted in the Diagnostic Laboratory of Histopathology, Institute of

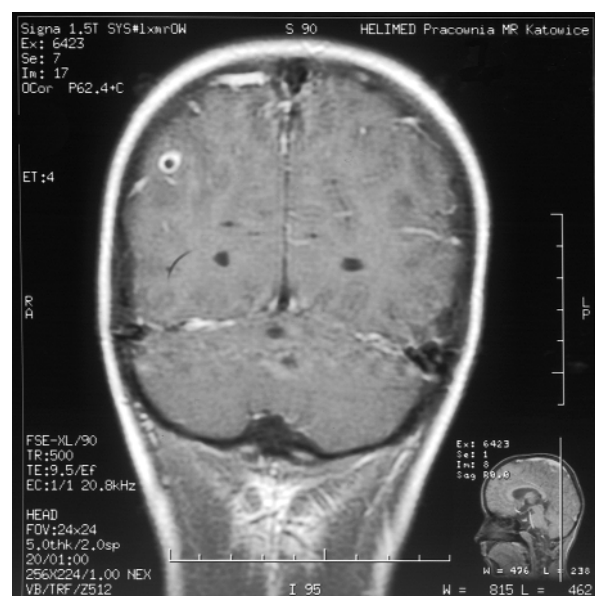

Fig. 3. Coronal image MR - after infusion of intravenous paramagnetic contrast, the parenchymal cisticercus is seen as a rim-enhancing lesion

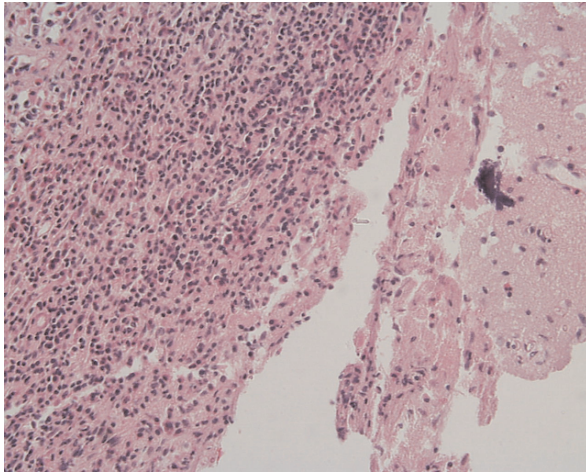


Fig. 4. The cross-sections of parasitic larva structures – surrounding glial tissue forming a “capsule” was characterized by a massive inflammatory infiltration with eosinophilia, granuloma formation, absorption and necrotic remainder of calcified matter – H-E stain, original magnification x 120

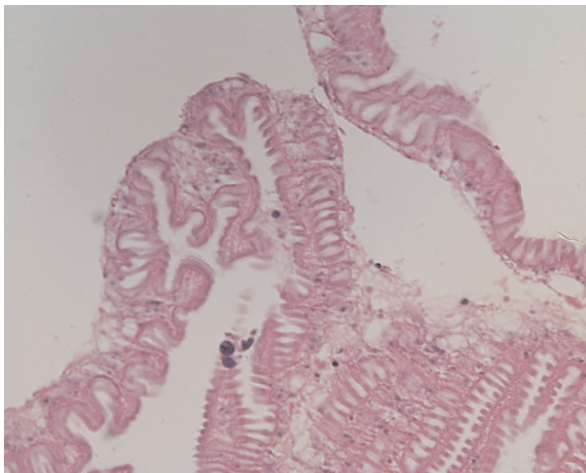


Fig. 5. The cross-sections of parasitic larva structures with necrotic remainder of calcified matter – H-E stain, original magnification x 200

Pathomorphology, Silesian Medical Academy, disclosed an hourglass-shaped pseudocystic cavity (Fig. 4).

In the center there were numerous cross-sections of parasitic larva-like structures and the necrotic remainder of the calcified matter. The surrounding glial tissue forming a capsule was characterized by a massive inflammatory infiltration with eosinophilia, granuloma formation and absorption. In the brain

tissue, close to the parasitic capsule, some calcifications and region of gliosis were found (Fig. 5).

The patient was referred to the Department of Child Neurology. The neurological examination carried out on her admission did not show any features of a focal damage of the CNS. The check-up MRI of the head revealed a slight postoperative malacia within the right parietal lobe of the brain. A psychological test showed a normal intellectual development (IQ=103). The optic fundus was normal. The picture of the abdominal cavity organs was correct as well. Additional investigations disclosed deviations such as eosinophilia (23%) and a positive enzyme linked immunosorbent assay (ELISA) for toxocarosis. A possibility of the presence of other parasitic diseases, including enterobiosis, ascariasis and taeniosis (*Taenia solium* and *Echinococcus granulosus*), was denied.

On the basis of the clinical picture and the conducted tests a diagnosis of a cerebral form of toxocarosis was established; mebendazole was applied in treatment. Moreover, to prevent convulsions, the application of carbamazepine was continued. The child is still in the care of the Outpatient Clinic of Neurology and Neurosurgery. At the present moment her condition is stable and she does not report any complaints. Besides, we no longer observe epileptic seizures.

Discussion

Toxocarosis is a consequence of human infection by *Toxocara canis* larvae. What constitutes life environment of the mature form of the helminth is a dog's digestive tract; it is in this part that they produce eggs, which are then excreted with a host's feces. The commonest source of infection is young puppies as these suffer from helminthoses more frequently than older dogs [4]. Another important risk factor is geophagia. In view of the fact that the eggs may be transferred to humans by mouth together with dirt, among those most susceptible to the disease there are children, persons with dementia, and farmers [1,6]. Our patient likes pets and is eager to be in contact with them; besides, she often spent her time in the park and played in sandboxes in her district. In Australian towns, a study was performed examining soil samples from public parks for *Toxocara canis* larvae. The findings of the study, surprising as they were for the researchers, show that public parks do not create a

serious risk of contracting toxocarosis, which is connected with the habit of regularly treating dogs with antihelminthic drugs [4]. To the best of our knowledge, a study of this kind has not been conducted in Poland. This theory seems to be reflected in the existence of a considerable difference between the disease prevalence in developed and developing countries, which, in the case of children, amounts to 20% and 60%, respectively [2]. The infection is a result of ingesting the parasite larvae, which penetrate walls of the digestive tract, and migrate to different somatic tissues actively, or passively, by the bloodstream. Since a human is not a natural host of *T. canis*, it is impossible for the mature form of the parasite to develop in people [1-3].

A large number of the infections are symptom-free. In most cases these are not recognized.

Symptoms of visceral *larva migrans* (VLM) syndrome are mostly general ones, including mood deterioration and high temperature. Most frequently, the larvae settle in the liver, where after some time they die. They can settle in other organs as well, e.g. in the lungs, heart muscle, or skeletal muscles. A histopathological test usually reveals the presence of granulomata comprised of acid-absorbing, lymphoid and giant cells. Therefore, in the course of massive toxocarosis, hepatomegaly may be noted. The parasite's death entails self-limiting and, subsequently, a partial remission of the changes. What attracts attention in this commonest symptomatic form of VLM syndrome is continuous eosinophilia, which, when accompanied by the enlargement of parenchymatous organs of the abdominal cavity and/or of lymph nodes of this region, by recurrent bronchitis, chronic cough, or subcutaneous granulomata, should make us watchful for a possibility of toxocarosis [3].

Ocular *larva migrans* (OLM) syndrome takes the form of blindness, mostly monocular; this occurs in children and clinically corresponds to uveitis, retinal vasculitis, chorioretinitis, maculopathy, retinal lesion and other disorders [4]. The process of diagnosing monocular visual impairment in children is frequently started relatively late, as children are not able to signal the problem. Another diagnostic difficulty consists in the lack of eosinophilia in OLM syndrome [4].

A cerebral form of toxocarosis, in the cases reported so far, has taken the course of neuropsychiatric disorders such as encephalitis, myelitis, behavioral changes, epileptic seizures and meningitis. *T. canis* is

regarded as one of the major infectious agents causing epilepsy (the odds ratio is 18.2, compared with 16.2 for viral encephalitis and 4.2 for bacterial encephalitis), amounting to the value 6 times as high as that noted for taeniosis (*T. solium*) [5]. Only some patients demonstrate the symptoms of the focal damage of the CNS resulting from the presence of the larvae; more often than not clinical symptoms are due to immune processes that might result from ineffective mechanisms of the parasite load clearance or of IgE-dependent hypersensitivity (type III hypersensitivity) [2]. Like other parasitic diseases, toxocarosis may lead up to immune vasculitis. Importantly, vasculitis may result in permanent neurological deficits even if a course of the underlying disease is benign [3].

In all likelihood, in neurotoxocarosis we observe intracerebral production of antibodies of IgG class. Moreover, while examining the cerebrospinal fluid in the patients with neurotoxocarosis, Magnasval et al. noted an elevated protein level (>4 g) in 50% of the patients and an enhanced cell-mediated reaction in 70% of their number [1].

In patients with cerebral toxocarosis, when manifested by focal symptoms, there were low-density areas made visible by CT scan and T2-weighted images by MRI. This needs to be differentiated from growth changes [1], which took place in the case of our patient.

Based on histopathological examinations of the CNS of the persons with cerebral toxocarosis, there appeared descriptions of changes in the forms of eosinophil granulomata as well as vasculitis, both of them localized mainly in the white matter of the brain and the cerebellum [7].

Two months before the incidence of symptomatic epilepsy, in our patient we observed a range of symptoms such as transient deterioration of mood, irritation, abdominal pains, and increasing percentage of acid-absorbing cells in the peripheral blood, which, retrospectively, might have suggested VLM syndrome. Afterwards there occurred cerebral symptoms: epilepsy with focal seizures and subsequent paresis of the upper left limb.

Diagnosing of toxocarosis remains difficult. For one thing, some infections take a symptom-free course; for another, some atypical symptoms may occur in response to migration or settling of the larvae, or as a consequence of the immune reaction being directed not only against the parasite, but also against the tissues of a host [2]. A standard

laboratory enzyme linked immunosorbent assay for antibodies of IgG anti-*T. canis* class proves to be a decisive diagnostic method [1].

Nowadays, a serological test for toxoplasmosis is becoming more and more easily available. We should bear in mind that despite deliberate treatment and clinical improvement IgG antibodies may be retained for a long time (several months or even years). Although Obwaller et al. have claimed a relation between IgE and IgG anti-IgE antibodies against *T. canis* on the one side and symptomatic periods of OLM and VLM syndromes on the other, this kind of determination is not routine in diagnosing [2].

Anthelmintic drugs used in *T. canis* treatment include diethylcarbamazine, albendazole, mebendazole and thiabendazole. Sommer et al. suggest the application of immunosuppressants as a means of preventing vasculitis in patients with cerebral toxocarosis [3]. Apart from that, to avoid Herxheimer's reaction, it is advisable to simultaneously apply steroids while early in treatment [7].

Our patient demonstrated organic symptoms, focal neurological symptoms confirmed by neuro-imaging and histopathological examinations, and progressing eosinophilia; a positive test for toxocarosis essentially completes the other outcomes, allowing us to recognize a cerebral form of toxocarosis.

References

1. Carden SM, Meusemann R, Walker J, Stawell RJ, MacKinnon JR, Smith D, Stawell AM, Hall AJ. *Toxocara canis*: egg presence in Melbourne parks and disease incidence in Victoria. *Clin Experiment Ophthalmol* 2003; 31: 143-146.
2. Goffette S, Jeanjean AP, Duprez TP, Bigaignon G, Sindic CJ. Eosinophilic pleocytosis and myelitis related to *Toxocara canis* infection. *Eur Jour Neurol* 2000; 7: 703-707.
3. Magnaval JF, Galindo V, Glickman LT, Clanet M. Human *Toxocara* infection of the central nervous system and neurological disorders: a case control study. *Parasit* 1997; 115: 357-543.
4. Obwaller A, Jensen-Jarolim E, Auer H, Huber A, Kraft D, Aspöck H. *Toxocara* infestations in humans: symptomatic course of toxocarosis correlates significantly with levels of IgE/anti-IgE immune complexes. *Parasite Immunol* 1998; 20: 311-320.
5. Sander JW, Perucca E. Epilepsy and comorbidity: infections and antimicrobials usage in relation to epilepsy management. *Acta Neurol Scand* 2003; 108: 16-22.
6. Sommer C, Ringelstein EB, Biniek R, Glockner WM. Adult *Toxocara canis* encephalitis. *J Neurol Neurosurg Psychiatry* 1994; 57: 229-231.
7. Tomaso H, Dierich MP, Allerberger F. Helminthic infestations in the Tyrol, Austria. *Clin Microbiol Infect Dis* 2001; 7: 639-641