

(17) **Acute retinal necrosis – a case report*****Ostra martwica siatkówki – opis przypadku*****Ewa Kuźmicz¹, Anna Fizia-Orlicz², Anna Turno-Kręcicka², Maria Pomorska², Marta Misiuk-Hojło², Anna Mec-Słomska³**¹ Department of Ophthalmology ALDEMED Medical Center, Zielona Góra, Poland
Head: Ewa Kuźmicz, MD² Department of Ophthalmology, Wrocław Medical University, Poland
Head: Professor Marta Misiuk-Hojło, MD, PhD³ Department of Ophthalmology, WCSKJ, Jelenia Góra, Poland
Head: Leszek Joński**Summary:** Acute retinal necrosis (ARN) is a rare but very severe form of retinitis. In contrast to progressive outer retinal necrosis acute retinal necrosis typically affects immunocompetent individuals. Herpes Simplex and Varicella-zoster viruses play the main role in the development of the disease.

We report a case study of a healthy, young male who presented to the ophthalmologist with unilateral visual acuity decrease and eye irritation. The acute retinal necrosis was diagnosed and a therapy was started including both systemic and local anti-viral agents, as well as an oral anticoagulant. Additional systemic steroid therapy was introduced a week later. The regression of retinal inflammatory changes and the improvement of visual acuity were observed. The polymerase chain reaction assay for the presence of viral DNA in serum was negative. The IgM antibody assay for potential causal pathogens was negative, but the level of Varicella-zoster virus IgG antibodies was markedly elevated. During the follow-up, the patient developed retinal detachment and pars plana vitrectomy with silicone oil endotamponade was performed. Although the surgery resulted in the successful retinal reattachment, the final visual acuity remained decreased. Six months after the surgery, the eye was free of the intraocular inflammation and the visual acuity slightly improved.

Key words: acute retinal necrosis (ARN), *herpes simplex virus* (HSV), *varicella-zoster virus* (VZV), pars plana vitrectomy (PPV).**Streszczenie:** Ostra martwica siatkówki jest rzadką, lecz bardzo ciężką postacią martwiczego zapalenia siatkówki. W przeciwieństwie do postępującej zewnętrznej martwicy siatkówki diagnozowana jest zazwyczaj u osób immunokompetentnych. Główną rolę w rozwoju choroby pełnią wirusy: *Herpes simplex* i *Varicella-zoster virus*.

Opisujemy przypadek młodego zdrowego mężczyzny, który zgłosił się do lekarza z powodu pogorszenia ostrości wzroku i zaczerwienienia oka lewego. Po rozpoznaniu ostrej martwicy siatkówki niezwłocznie włączono dożylnie i miejscowe leczenie przeciwwirusowe i doustne leczenie przeciwzakrzepowe. Po tygodniu dołączono również ogólną steroidoterapię. Zaobserwowano wycofywanie się zmian zapalnych siatkówki i poprawę ostrości wzroku. Oznaczenie w osoczu materiału DNA metodą reakcji łańcuchowej polimerazy oraz miana przeciwciał w klasie IgM potencjalnych wirusowych patogenów dało wynik negatywny. Otrzymano jedynie wysokie miano przeciwciał anty-*Varicella-zoster virus* w klasie IgG. Po około 2 miesiącach od postawienia rozpoznania stwierdzono odwarstwienie siatkówki i przeprowadzono zabieg pars plana witektonii z olejem silikonowym, po którym pomimo dobrego efektu anatomicznego uzyskano niską ostrość wzroku. W obserwacji półrocznej obserwowano stabilny obraz dna oka i nieznaczną poprawę ostrości wzroku.

Słowa kluczowe: ostra martwica siatkówki, wirus *Herpes Simplex*, wirus *Varicella-zoster*, pars plana witektonia.**Introduction**

Acute retinal necrosis (ARN), first described in 1971 by Aki-ura Urayama in Japan, poses high risk of visual loss in otherwise healthy individuals of both sexes, regardless of race or origin (1). The most common causative pathogens are herpes viruses, such as varicella zoster virus (VZV), which is responsible for 50–80% of cases, and herpes simplex virus types 1 and 2 (HSV) (1, 2). The disease seldom can be caused by cytomegalovirus (CMV) or Epstein-Barr virus (EBV) (1–3).

The ocular infection is associated with the reactivation of the virus remaining dormant in sensory ganglia after primary infection. Risk factors include systemic steroid therapy, history

of herpetic encephalitis and neurosurgical procedures, history of herpes zoster infection including its ocular manifestation, as well as history of chickenpox and herpetic infection (4).

The diagnosis is usually based on clinical features. The most common primary symptoms include: decreased visual acuity, photophobia, floaters, pain and eye irritation (4). The increased intraocular pressure (IOP) in the early stages of the disease is characteristic for herpetic infection. On examination the signs of granulomatous anterior uveitis may be present. In posterior segment marked vitritis and peripheral retinal abnormalities such as occlusive arteritis with white-yellow infiltrates and subsequent full-thickness necrotizing retinitis spreading

circumferentially are observed (5, 6). The posterior pole involvement is extremely uncommon. If the posterior pole is affected, the VZV etiology can be suspected (1).

The aim of our report is to present a case of a healthy, young male with unilateral acute retinal necrosis, complicated with retinal detachment treated with pars plana vitrectomy.

A case report

A 33-year-old man with irrelevant medical history was referred by the outpatient ophthalmology service to the Department of Ophthalmology at WCKJ Hospital in Jelenia Góra with clinical signs of anterior uveitis, in his left eye (LE), which was unresponsive to treatment. The symptoms had been present for two weeks and the patient had been treated with topical anti-inflammatory and antibacterial agents without improvement. On admission, the uncorrected visual acuity (UCVA, Snellen) was 1.0 and 0.3 in the right (RE) and left eye (LE), respectively, with no subsequent improvement on correction. The slit-lamp examination of RE revealed no abnormalities. In LE, the signs of anterior and posterior uveitis were observed: mutton-fat keratic precipitates, anterior chamber (AC) flare and cells and marked vitritis. The ophthalmoscopy of the LE revealed optic disc edema (Fig. 1), periarteritis (Fig. 2)

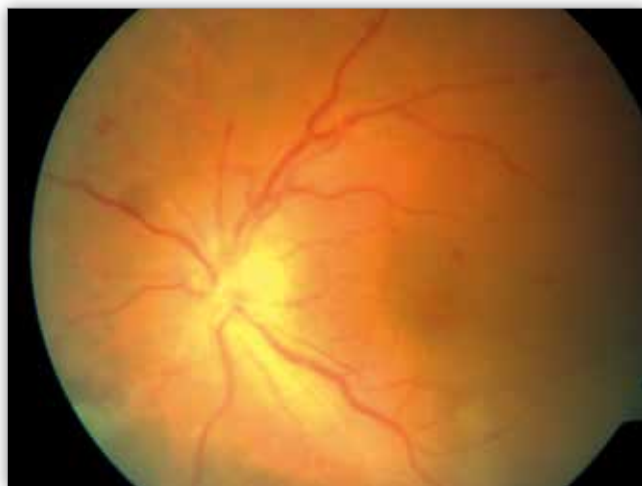

Fig. 1. The left eye fundus – papilloedema.

Ryc. 1. Dno oka lewego – obrzęk tarczy nerwu wzrokowego.

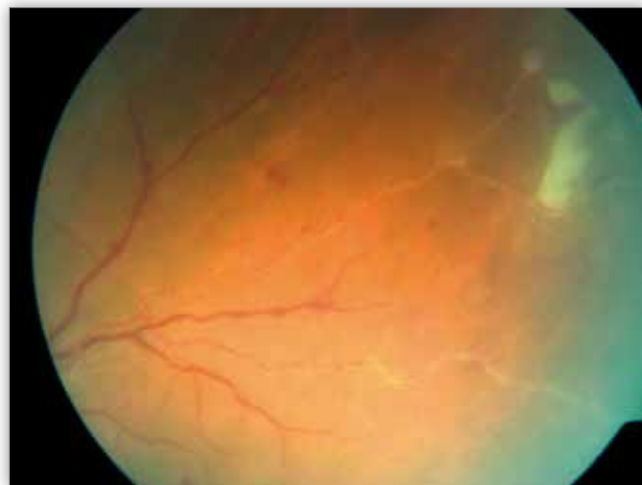

Fig. 2. The left eye fundus– periarteritis.

Ryc. 2. Dno oka lewego – zapalenie tętnic.

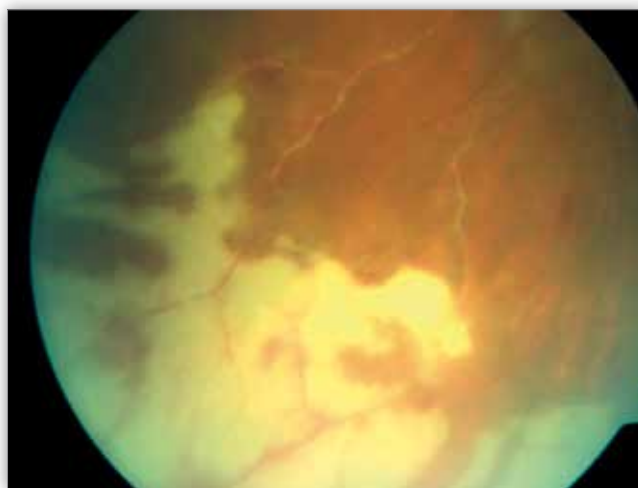

Fig. 3. The left eye fundus – confluent, creamy, sharply demarcated, circumferential infiltrates involving the retinal periphery.

Ryc. 3. Dno oka lewego – zlewne, kremowe, ostro ograniczone zmiany zapalne siatkówki obejmujące okężnie cały daleki obwód.

and confluent, creamy, sharply demarcated circumferential infiltrates within the retinal periphery (Fig. 3). The clinical diagnosis of acute retinal necrosis was established and the patient was referred to the Department of Ophthalmology at the University Hospital in Wrocław.

Numerous laboratory tests were performed. The complete blood cell count, erythrocyte sedimentation rate, electrolytes, glucose, C-reactive protein and procalcitonin levels were within normal limits. The serology tests for human immunodeficiency virus (HIV), syphilis and Lyme disease were negative. The varicella-zoster virus, herpes simplex virus and cytomegalovirus IgG and IgM antibodies levels in serum were tested. All the IgM antibodies were negative, but the serum levels of VZV, HSV and CMV IgG antibodies were increased. The serum titer of VZV IgG was markedly elevated (3253.3 mU/ml). The polymerase chain reaction (PCR) assays for serum HSV and CMV DNA were negative. The chest X-ray was normal. The fundus fluorescein angiography revealed disseminated vasculitis with a delayed arterial flow and the patchy staining in the peripheral areas of retinal necrosis.

The diagnosis of ARN was established based on clinical features. The intravenous antiviral treatment was started with 750 mg of acyclovir administered three times daily and 75 mg of oral aspirin administered twice daily. The topical medications included acyclovir, dexamethasone and atropine. After two weeks, the intravenous treatment with acyclovir was replaced by 800 mg of acyclovir administered orally five times a day.

The treatment caused gradual resolution of optic disc oedema and regression of the inflammatory retinal and vascular lesions. Nodular and segmental arteritis with Kyrileis plaques still persisted (1) (Fig. 4) and a significant increase of vitritis (Fig. 5) was observed as well. Therefore the systemic steroidotherapy of oral prednisone with the starting dose of 65 mg was initiated after one week of antiviral treatment. The patient was discharged from the hospital with UCVA of 0.4 (Snellen) in the affected eye. The topical and systemic antiviral and anti-inflammatory treatment were continued.

The UCVA in the LE improved to 0.7 at a follow-up visit 2 weeks later. The examination showed further resolution of re-

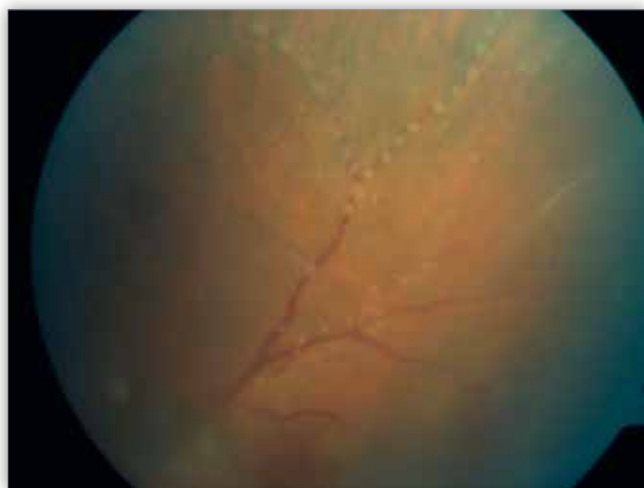

Fig. 4. The left eye fundus – gradual resolution of the optic disc oedema and regression of retinitis and vasculitis after treatment.

Ryc. 4. Dno oka lewego – po leczeniu ustępowanie obrzęku tarczy nerwu wzrokowego oraz zmian zapalnych siatkówki i naczyń krwionośnych.

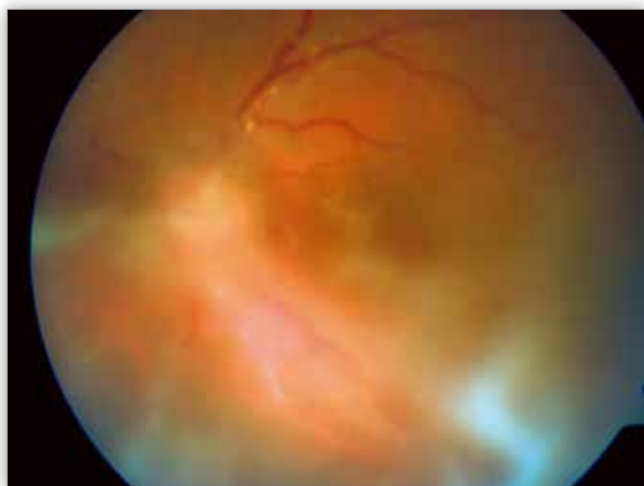


Fig. 5. The left eye fundus – progression of vitritis.

Ryc. 5. Dno oka lewego – nasilenie wysięku zapalnego w ciele szklistym.

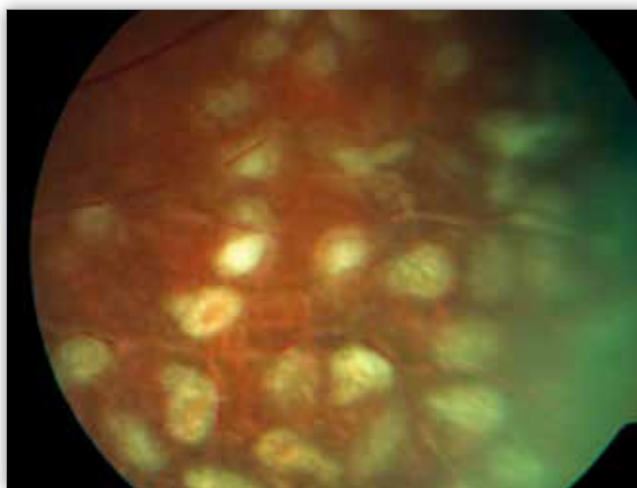


Fig. 6. The left eye fundus – successful retinal reattachment after 25 G pars plana vitrectomy.

Ryc. 6. Dno oka lewego – widoczne przyłożenie siatkówki po zabiegu 25 G witrektomii przez pars plana.

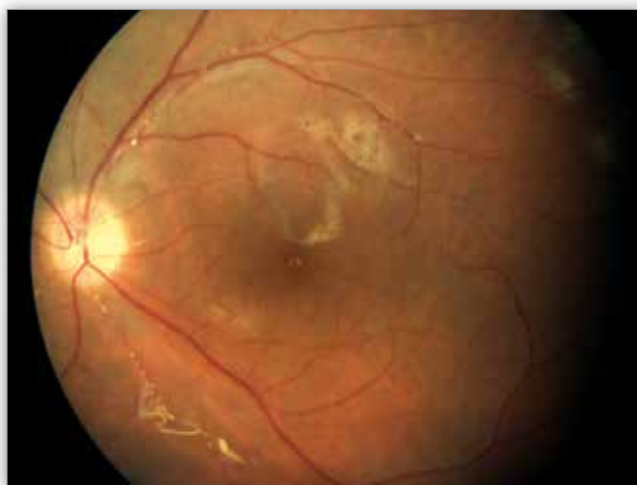

Fig. 7. 25 G pars plana vitrectomy for retinal detachment in the left eye.

Ryc. 7. Operacja przyłożenia odwarstwienia siatkówki oka lewego – 25 G witrektomia przez pars plana.

tinal and vascular inflammation with decreased vitritis. Two weeks later, the patient was admitted to the ophthalmic emergency department with a sudden vision worsening in his LE. The visual acuity in the LE was limited to seeing hand movements and light perception. The patient was diagnosed with retinal detachment in his LE and he underwent the 25G pars plana vitrectomy with 1000 silicone oil tamponade, combined with intraoperative endolaser coagulation, which ultimately led to the successful retinal reattachment (Fig. 6, 7).

The patient is regularly monitored by the outpatient service at the Department of Ophthalmology, Wrocław Medical University. Six months after the surgery, the UCVA of RE was 1.0 and BCVA of LE – 0.2 (Snellen chart). The oral acyclovir dose is gradually tapered. Due to the recurrences of anterior uveitis with posterior synechiae formation, topical dexamethasone and atropine were periodically introduced leading to the successful symptoms resolution. Six months after surgery, there was no evidence of active intraocular inflammation.

Discussion

ARN is a rare but very severe necrotizing retinitis. Despite the characteristic symptoms, there are cases of atypical clinical manifestation. The differential diagnosis should include: progressive outer retinal necrosis (PORN), syphilitic retinitis, ocular toxoplasmosis, endogenous enophthalmitis and Behcet's disease (1–3).

In 1994, the Executive Committee of the American Uveitis Society has introduced standard diagnostic criteria for the acute retinal necrosis syndrome, which they are valid up to date and include:

- single or multiple areas of peripheral retinal necrosis with distinct borders,
- rapid disease progression if antiherpetic treatment not instituted,
- extension of foci of retinal necrosis in a circumferential fashion,
- presence of occlusive vasculopathy with arteriolar involvement,
- prominent anterior chamber and vitreous inflammation.

The characteristics that support but are not required for the diagnosis include optic neuropathy or atrophy, scleritis and ocular pain (7).

Laboratory tests are very helpful in determining the etiology of the disease. In recent years PCR testing has been playing an increasingly important role in the viral DNA detection. AC fluid or vitreous samples can be tested in the laboratories equipped with appropriate kits for PCR assay. A small amount of tested sample (>0.05 ml) is sufficient to detect the presence of HSV, VZV, CMV or EBV DNA (8, 9).

The early diagnosis of ARN followed by the prompt antiviral treatment are of paramount importance. The goal of treatment is to stop active inflammation and minimize the risk of complications. It has been demonstrated in clinical studies that, if started early, the treatment reduces the incidence of symptoms in the fellow eye (1, 3).

The topical, systemic and intravitreal antiviral therapy is generally accepted, although there is no single treatment strategy as a standard of care (10). Other therapeutic options include: steroid therapy, antithrombotic therapy, preventive laser retinopexy and vitreoretinal procedures if needed. Acyclovir is the recommended antiviral treatment for adults administered intravenously at the dose of 10–15 mg/kg every 8 hours for 10–14 days, followed by an oral dose of 800 mg 5 times a day for 6–14 weeks (8,10). Clinical studies have shown that acyclovir stops the inflammatory process within 48 hours following the intravenous administration, and the disease symptoms resolve after 4 days of treatment (11). The long-term oral use of acyclovir protects from recurrences and fellow eye involvement. The alternative medications, which can only be administered orally due to their high bioavailability, are valacyclovir (at the dose of 2.0 mg TID) and famciclovir (at the dose of 500 mg TID) (1, 8). If the inflammatory lesions do not resolve, drug resistance or CMV etiology are very likely and intravenous ganciclovir at the dose of 900 mg BID should be administered. Intravenous foscarnet or cidofovir can be used in severe cases of refractory ARN. Intravitreal administration of foscarnet (2.4 mg/0.1 ml once a week) or ganciclovir (2.0 mg/0.1 ml 2–3 times a week) should be considered in patients who do not respond to systemic antiviral treatment, or as an adjunct therapy (8, 11–14). In ARN cases with CMV etiology in HIV-positive patients the intravitreal ganciclovir dose can be increased to 5.0 mg/0.1 ml once a week. The intravitreal sustained-release ganciclovir implant releasing the active substance for 8 months is also available. Once the effective antiviral treatment is started, the anti-inflammatory treatment should also be considered. 0.5 mg/kg of prednisone is a commonly used regimen (1, 8). Intravitreal administration of steroids (400 mcg/0.1 ml of dexamethasone) adjunctive to intravitreal ganciclovir has been reported in some studies, especially in ARN cases of VZV etiology (15).

Even after the regression of vitreal and retinal inflammation, there is still a very high risk of complications, which also occurred in our patient two months after the diagnosis. The rhegmatogenous retinal detachment is the most common complication which occurs in 50–75% of cases, typically within the first six months. The most common location of retinal tears is the borderline of the necrotic and healthy retina. The preventive barrier laser retinopexy was shown to reduce the risk of retinal

detachment, however its rate still remains high even in eyes after previous laser treatment (6, 16, 17). Most published reports suggest that preventive barrier laser retinopexy should be performed in cases with limited vitritis and the ability to visualize the retina, however the common agreement is yet to be reached (6, 10, 17). Severe vitritis with poor fundus view precluded the preventive retinal laser therapy prior to retinal detachment in our patient. Pars plana vitrectomy with silicone oil endotamponade enables retinal stabilization, protecting it from secondary detachment.

The vision prognosis is poor, only in 30% of individuals with ARN achieve the final visual acuity over 0.1 (Snellen chart). It is mainly due to complications such as retinal detachment and ischemic optic neuropathy resulting from thrombotic arteriole closure (18).

Conclusions

The presented patient was diagnosed with ARN two weeks following the onset of symptoms. ARN is often associated with anterior uveitis, so ophthalmoscopy with peripheral retinal evaluation is obligatory in all cases of anterior uveitis. Despite the use of intensive antiviral treatment, frequent complications, such as retinal detachment, occurred. Vitrectomy with silicone oil endotamponade enabled a successful retinal reattachment but the final visual acuity remained decreased due to optic neuropathy.

References:

1. Wong RW, Jumper JM, McDonald HR, Johnson RN, Fu A, Lujan BJ, et al.: *Emerging concepts in the management of acute retinal necrosis*. Br J Ophthalmol. 2013; 97: 545–552.
2. Tam P MK, Hooper CY, Lightman S: *Antiviral selection in the management of acute retinal necrosis*. Clinical Ophthalmology. 2010; 4: 11–20.
3. Rautenberg P, Hillenkamp J, Grančičova L, Nölle B, Roeder J, Fickenscher H: *Virus Diagnostics and Antiviral Therapy in Acute Retinal Necrosis (ARN), Antiviral Drugs - Aspects of Clinical Use and Recent Advances*. Dr. Arbuthnot P 2012 (Ed.), ISBN: 978-953-51-0256-4.
4. Muthiah MN, Michaelides M, Child CS, Mitchell SM: *Acute retinal necrosis: a national population-based study to assess the incidence, methods of diagnosis, treatment strategies and outcomes in the UK*. Br J Ophthalmol. 2007; 91: 1452–1455.
5. Kezuka T, Atherton SS: *Acute Retinal Necrosis*. In: Niederkorn JY, Kaplan HJ: *Immune Response and the Eye*. Chem Immunol Allergy. 2000; 92: 244–253.
6. Lau CH, Missotten T, Salzmann J, Lightman SL: *Acute Retinal Necrosis features, management and outcomes*. Ophthalmology. 2007; 114: 756–762.
7. Holland GN: *Standard diagnostic criteria for the acute retinal necrosis syndrome*. Executive Committee of the American Uveitis Society. Am J Ophthalmol. 1994; 117: 663–667.
8. Wong RW, Cunningham ET: *Diagnosing and Managing Acute Retinal Necrosis, A variety of treatment options exist for this rare but troubling condition*. Retinal Physician. 2013; 10: 38–45.
9. Tran THC, Rozenberg F, Cassoux N, Rao NA, LeHoang P, Bodaghi B: *Polymerase chain reaction analysis of aqueous humour samples in necrotising retinitis*. Br J Ophthalmol. 2003; 87: 79–83.

10. Tibbets MD, Shah CP, Young LH, Duker JS, Maguire JI, Morley MG: *Treatment of acute retinal necrosis*. Ophthalmology. 2010; 117: 818–824.
11. Druker JS, Blumenkranz MS: *Diagnosis and management of the acute retinal necrosis syndrome*. Surv Ophthalmol. 1991; 35: 327–343.
12. Tran THC, Cassoux N, Bodaghi B, Lehoang P: *Successful treatment with combination of systemic antiviral drugs and intravitreal ganciclovir injections in the management of severe necrotizing herpetic retinitis*. Ocular Immunology and Inflammation. 2003; 2: 141–144.
13. Li J, Chen H, Yang X: *Therapeutic effects of ganciclovir with different injection methods on experimental retinal necrosis*. Chinese Journal of Ocular Fundus Diseases. 2008; 24(6): 418–421.
14. Marrocos de Aragao RE, Barreira IMA, Arrais BLA, Pereira LA, Ramos CS: *Good visual outcome in an immunocompromised patient with bilateral acute retinal necrosis syndrome: A case report*. Saudi J Ophthalmol. 2014; 28: 243–246.
15. Kishore K, Jain S, Zarbin MA: *Intravitreal ganciclovir and dexamethasone as adjunctive therapy in the management of acute retinal necrosis caused by varicella zoster virus*. Ophthalmic Surgery, Lasers and Imaging Retina. 2011; 42: 87–90.
16. *Siatkówka i ciało szkliste: Basic and Clinical Science Course*. Cz. 12. Wyd. 1. polskie, red. K. Pecold. Wyd. Med. Urban i Partner. Wrocław 2007.
17. Sims J, Yeoh J, Stawell RJ: *Acute retinal necrosis: a case series with clinical features and treatment outcomes*. Clin Experiment Ophthalmol. 2009; 37: 473–477.
18. Kański JJ: *Okulistyka Kliniczna*. Wyd.1. polskie. Wyd. Med. Urban i Partner. Wrocław 1997.

The study was originally received 10.08.2014 (1481)/
Praca wpłynęła do Redakcji 10.08.2014 r. (1481)
Accepted for publication 28.05.2015/
Zakwalifikowano do druku 28.05.2015 r.

Adres do korespondencji (Reprint requests to):
lek. Ewa Kuźmicz
ul. Chopina 5
68-300 Lubsko
e-mail: ewakuzmicz@tlen.pl



STOWARZYSZENIE ZWYRODNIENIA PLAMKI
ZWIĄZANEGO Z WIEKIEM (AMD) zaprasza na

XI SYMPOZJUM STOWARZYSZENIA AMD

Termin: 21 listopada 2015 r.

Miejsce: Hotel InterContinental
Warszawa, ul. Emilii Plater 49

Temat główny: SYTUACJA PACJENTA Z AMD
I CUKRZYCOWYM OBRZĘKIEM PLAMKI DME

SESJA I: PROGRAM LEKOWY W WYSIĘKOWYM AMD
Medyczne i praktyczne aspekty programu lekowego

SESJA II: CUKRZYCOWY OBRZĘK PLAMKI – JAK NOWOCZEŚNIE LECZYĆ?
Aktualne strategie terapeutyczne w leczeniu DME

SESJA III: CO NOWEGO W SUCHYM AMD?
Możliwości terapeutyczne we wczesnych fazach AMD i retinopatii cukrzycowej;
Zagrożenia suplementacją diety w suchym AMD; Quiz

Szczegółowe informacje i rejestracja
uczestników na stronie internetowej
www.amd.org.pl
Liczba miejsc ograniczona,
decyduje kolejność zgłoszeń.

Stowarzyszenie AMD
Al. Waszyngtona 146/206, 04-076 Warszawa
tel./fax (22) 515 80 01
tel. kom. (+48) 516 062 843
e-mail: stoamd@op.pl, www.amd.org.pl

nr konta bankowego Deutsche Bank o/Warszawa: 52 1910 1048 2214 9923 9402 0001

Prof. dr hab. n. med.
Andrzej Stankiewicz

Przewodniczący Komitetu
Organizacyjnego i Naukowego