

(41)

The effect of corneal tunnel length in patients after standard phacoemulsification through a 2.75 mm incision on surgically induced astigmatism, corneal thickness and endothelial cell density

Wpływ długości tunelu rogówkowego po fakoemulsyfikacji zaćmy przez cięcie o szerokości 2,75 mm na astygmatyzm indukowany chirurgicznie, grubość rogówki i gęstość komórek śródbłonka

Michał Wilczyński, Ewa Supady, Tomasz Wierzchowski, Marcin Zdzeszyński, Wojciech Omulecki

Department of Ophthalmology, Medical University of Łódź
Head: Professor Wojciech Omulecki, PhD, MD

Abstract:

Purpose: The purpose was to determine the effect of the corneal tunnel length in the 2.75 mm wide clear corneal incision, created during phacoemulsification on surgically induced astigmatism, central corneal thickness and corneal endothelial cell loss.

Material and methods: The study comprised 27 eyes (27 patients) who underwent phacoemulsification through 2.75 mm temporal clear corneal incision. Patients were examined preoperatively, 1 day, 7 days and 1 month postoperatively. Exclusion criteria were: previous intraocular surgery, corneal disorders and previous ocular trauma.

Best corrected distance visual acuity, keratometry, slit-lamp examination, anterior segment optical coherence tomography and corneal endothelial cell density measurement were performed. Surgically induced astigmatism was calculated with vector method. Statistical analysis was done using non-parametric tests: Wilcoxon test, Mann-Whitney U test and Spearman correlation coefficient.

Results: Mean best-corrected distance visual acuity was 0.30 ± 0.24 preoperatively and 0.94 ± 0.18 postoperatively ($p < 0.05$). Mean corneal incision length 1 day postoperatively was 1.84 ± 0.36 mm. Surgically induced astigmatism was 0.51 ± 0.41 D one month postoperatively. Clear corneal incision length and surgically induced astigmatism were positively correlated ($p < 0.05$).

Mean central corneal thickness was 0.51 ± 0.05 mm preoperatively, 0.56 ± 0.09 mm one day and 0.51 ± 0.05 mm one month postoperatively ($p < 0.05$). Clear corneal incision length and central corneal thickness 30 days postoperatively were not correlated ($p = 0.27$).

Mean corneal endothelial cell density was 2483 ± 417 cells/mm² preoperatively and 2325 ± 410 cells/mm² postoperatively. The difference was significant ($p < 0.05$). Clear corneal incision length and corneal endothelial cell loss were not correlated ($p > 0.05$).

Conclusions: The results suggest that the length of the 2.75 mm clear corneal incision influences the surgically induced astigmatism, but it doesn't influence the central corneal thickness and corneal endothelial cell loss. Shorter clear corneal incisions induce smaller surgically induced astigmatism in comparison with longer incisions of the same width and localization. Unequivocal confirmation of the influence of clear corneal incision length on surgically induced astigmatism requires further investigation on a larger group of patients. Using laser techniques could help, as it would enable to examine patients in groups with different predefined clear corneal incision lengths.

Key words:

phacoemulsification, clear corneal incision, incision length, astigmatism, corneal thickness.

Abstrakt:

Cel: celem współczesnej chirurgii zaćmy jest nie tylko uzyskanie najlepszej skorygowanej ostrości wzroku, lecz także umożliwienie pacjentom jak najwcześniejszego powrotu do aktywnego trybu życia. Astygmatyzm indukowany chirurgicznie istotnie pogarsza nieskorygowaną ostrość wzroku i wymaga pooperacyjnego zastosowania korekcji, a to może zmniejszyć satysfakcję pacjentów z zabiegu.

Szerokość cięcia rogówkowego wykonywanego do zabiegu fakoemulsyfikacji zaćmy jest znanym czynnikiem istotnie wpływającym na integralność rany operacyjnej i astygmatyzm indukowany chirurgicznie. Długość tunelu rogówkowego nie jest uważana za czynnik o istotnym znaczeniu i nie jest mierzona rutynowo.

Celem pracy jest ocena wpływu długości tunelu rogówkowego wykonanego podczas standardowej fakoemulsyfikacji zaćmy przez cięcie o szerokości 2,75 mm na grubość centralnej części rogówki, astygmatyzm indukowany chirurgicznie, a także na ubytek komórek śródbłonka rogówki.

Materiał i metody: grupa badana liczyła 27 chorych (27 oczu), u których wykonano fakoemulsyfikację zaćmy przez skroniowe cięcie w przezierniej rogówce o szerokości 2,75 mm, z wszczepieniem soczewki zwijalnej. Pacjentów badano w 1. dniu od zabiegu, w 7. dniu od zabiegu i w 1. miesiącu od zabiegu. Oceniano: ostrość wzroku z najlepszą korekcją na standardowych tablicach Snellena do dali, keratometrię, badano odcinek przedni i dno oka w lampie szczelinowej, mierzono gęstość komórek śródbłonka rogówki. Astygmatyzm indukowany obliczono metodą analizy wektorowej. Za pomocą badania optycznej koherentnej tomografii przedniego odcinka w skanie horyzontalnym (na godzinach 3–9 gałki ocznej) wykonano pomiary długości tunelu rogówkowego i grubości rogówki w centrum.

Do testowania istotności różnic wartości średnich zmiennych ilościowych w dwóch próbach niezależnych stosowano test U Manna-Whitney'a, a w celu testowania istotności różnic wartości średnich w dwóch próbach zależnych zaś stosowano test kolejności par Wilcoxon. W celu oceny korelacji między badanymi wartościami obliczono współczynnik korelacji Spearmana oraz dokonano analizy regresji.

Wyniki: średnia przedoperacyjna ostrość wzroku do dali z najlepszą korekcją wyniosła $0,30 \pm 0,24$. Po zabiegu nastąpiła istotna poprawa ostrości wzroku do dali z najlepszą korekcją ($p < 0,05$). Średnia pooperacyjna ostrość wzroku z najlepszą korekcją wyniosła $0,83 \pm 0,27$ po 1. dniu od zabiegu, $0,941 \pm 0,18$ po 7. dniu od zabiegu oraz $0,938 \pm 0,18$ po 1. miesiącu od zabiegu. Średnia długość tunelu rogówkowego wyniosła $1,84 \pm 0,36$ po 1. dniu od zabiegu, $1,72 \pm 1,59$ po 7. dniu od zabiegu oraz $0,31 \pm 0,32$ po 1. miesiącu od zabiegu. Zmiany były istotne statystycznie ($p < 0,05$).

Astygmatyzm indukowany chirurgicznie obliczony metodą wektorową wyniósł $0,73 \pm 0,58$ po 1. dniu od zabiegu, $0,50 \pm 0,31$ po 7. dniu od zabiegu oraz $0,51 \pm 0,41$ po 1. miesiącu od zabiegu. Zmiany były istotne statystycznie ($p < 0,05$). Korelacja między długością tunelu rogówkowego a astygmatyzmem indukowanym chirurgicznie po 30 dniach od zabiegu była dodatnia i istotna statystycznie (współczynnik korelacji Spearmana wyniósł $0,4$, $p = 0,03$).

Średnia grubość centralnej części rogówki wyniosła: $0,51 \pm 0,05$ przed zabiegiem, $0,56 \pm 0,09$ po 1. dniu od zabiegu, $0,53 \pm 0,06$ po 7. dniu od zabiegu oraz $0,51 \pm 0,05$ po 1. miesiącu od zabiegu. Zmiany były istotne statystycznie po 1. dniu od zabiegu i po 7. dniu od zabiegu ($p < 0,05$). Korelacja między długością tunelu rogówkowego a grubością centralnej części rogówki po 30 dniach od zabiegu nie była istotna statystycznie (współczynnik korelacji Spearmana wyniósł $0,21$, $p = 0,27$).

Średnia gęstość komórek śródbłonka rogówki wyniosła: 2483 ± 417 przed zabiegiem, 2419 ± 340 po 1. dniu od zabiegu, 2330 ± 456 po 7. dniu od zabiegu oraz 2325 ± 410 po 1. miesiącu od zabiegu. Zmiana była istotna statystycznie po 7. i 30. dniu od zabiegu ($p < 0,05$). Średni ubytek komórek śródbłonka rogówki po 30. dniu od zabiegu wyniósł $5,77\%$. Korelacja między długością tunelu rogówkowego a gęstością komórek śródbłonka rogówki po 30 dniach od zabiegu nie była istotna statystycznie (współczynnik korelacji Spearmana wyniósł $0,06$, $p > 0,05$).

Wnioski: wyniki sugerują, że po niepowikłanej fakoemulsyfikacji zaćmy długość tunelu rogówkowego istotnie wpływa na finalny astygmatyzm indukowany chirurgicznie, nie wpływa natomiast na grubość rogówki oraz ubytek komórek śródbłonka rogówki. Krótsze tunele rogówkowe indukują mniejszy astygmatyzm w porównaniu z dłuższymi tunelami o tych samych szerokości i lokalizacji. Jednoznaczne potwierdzenie hipotezy o wpływie długości cięcia rogówkowego na astygmatyzm indukowany chirurgicznie wymaga dalszych badań z udziałem większej grupy pacjentów. Zastosowanie techniki laserowej mogłoby pomóc w rozwiązaniu tego zagadnienia, umożliwiłoby bowiem zbadanie pacjentów z wyjściowo zaplanowaną różną długością tunelu rogówkowego.

Słowa kluczowe: fakoemulsyfikacja, długość cięcia, astygmatyzm, grubość rogówki.

Introduction

Life expectancy has increased rapidly in the developed countries. As a result, the incidence of cataract has risen appropriately in the aging population. The goal of contemporary cataract surgery is not only to achieve the optimum best-corrected distance visual acuity (BCDVA) but also to enable patients to return to their normal, active lifestyle as early as possible. Therefore, surgically induced astigmatism (SIA) challenges this goal, as it impairs the uncorrected visual acuity and implies using refractive correction, which prolongs visual rehabilitation and decreases patient satisfaction.

In this context, it is crucial to constantly develop new, improved surgical approaches. Evolution of surgical incisions plays an important role in the development of cataract surgery. Although cataract microsurgery is gaining popularity, phacoemulsification through a clear corneal incision of 2.2 mm to 2.75 mm is currently regarded as „the global standard” in surgical management of cataract.

The width of corneal incision created during phacoemulsification is known to affect corneal wound integrity and surgically induced astigmatism. The length of clear corneal incision

is not considered an important factor to affect SIA, so it is not routinely measured (Fig. 1).

The purpose of the study was to determine the effect of the length of the 2.75 mm wide clear corneal incision created during standard phacoemulsification, on surgically induced astigmatism, central corneal thickness and corneal endothelial cell loss.

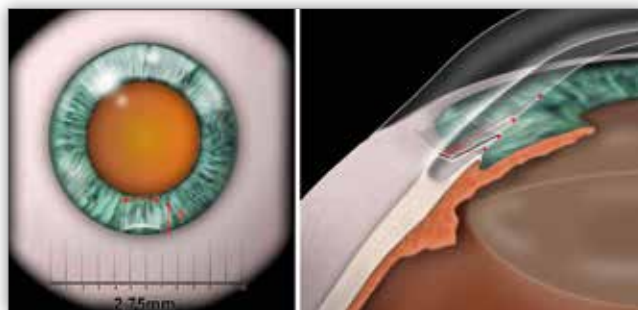


Fig. 1. Schematic representation of various chord lengths of corneal tunnels in 2.75 mm wide clear corneal incisions used for standard phacoemulsification (illustration by Dr. M. Wilczyński).

Ryc. 1. Schemat różnej długości cięciwy tuneli w czystej rogówce o szerokości 2,75 mm wykonywanych podczas standardowej fakoemulsyfikacji (rysunek: dr M. Wilczyński).

Material and methods

The study protocol was compliant with the stipulations of Declaration of Helsinki. All patients expressed their informed consent to participate in the study. The study protocol was approved by the Internal Review Board at the Medical University of Łódź.

We carried out a non-randomised, prospective study of consecutive case series. The study cohort consisted of 27 eyes of 27 patients: 21 women (78%) and 6 men (22%), aged from 55 to 88 years old (mean age = 78.2, SD = ± 7.4 years). All patients underwent uneventful phacoemulsification through a 2.75 mm temporal clear corneal incision with a single-piece foldable IOL implantation. The width of the corneal incision was the same in all patients and its length was not pre-planned. All patients had a similar degree of nuclear opacification (NO2 or NO3) and a similar degree of cortical opacification (C2 or C3) assessed using the LOCS III scale (1). We excluded individuals after previous intraocular surgery, with corneal disorders and a history of ocular trauma.

All procedures were performed by two experienced surgeons (M.W. and W.O.) under local, topical anaesthesia—proxymetacaine hydrochloride (Alcaine) eyedrops, 2% Lidocaine gel and 1% intracameral Lidocaine solution. All patients had their pupil dilated preoperatively, using a 1% solution of tropicamide and phenylephrine (NeoSynephrine). Hydroxypropyl methylcellulose 2% (Celoftal, Alcon) was used as an ophthalmic viscosurgical device (OVD) and balanced salt solution (BSS) was used as the infusion fluid. All procedures were performed using the burst mode for phacoemulsification and “stop and chop” technique for dividing the nucleus, at the same phaco machine settings. The sculpt settings were: aspiration flow of 25 cm³/min and vacuum of 90 mmHg. For quadrant removal the aspiration flow was set at 35 cm³/min and vacuum at 400 mmHg.

The same surgical technique was used in all eyes. First, a self-sealing 2.75 mm wide curved single-plane clear corneal incision was created temporally with a 2.75 mm ClearCut™ Dual Bevel (Alcon) metal slit knife, near the internal margin of the limbus. The same type of metal keratome was used for all procedures with all incisions being sutureless and self-sealing. A continuous curvilinear capsulorrhexis was done with Utrata forceps under the OVD protection. Two side-ports were created with a 20-gauge MVR blade in the clear cornea, 90 degrees apart from the main incision. Next, phacoemulsification and aspiration were performed and after filling the anterior chamber with an OVD, a single-piece acrylic foldable lens was implanted with an injector through the main incision. No additional astigmatic correction (e.g. arcuate incisions) was used at the time of the surgery.

Postoperative management was the same in all patients and included topical combination of tobramycin–dexamethasone (Tobradex) eyedrops 4 times daily for 3 weeks after the surgery. Patients were examined preoperatively as well as on day 1, day 7, and 1 month postoperatively. The following parameters were evaluated: best corrected distance visual acuity (BCDVA) using standard Snellen charts, keratometry, the anterior and posterior segment of the eye and the corneal endothelial cell density. Surgically induced astigmatism was calculated using the vector method. Corneal thickness and the length of the clear corneal

incision (the chord length) were measured using the anterior segment OCT (slit lamp adapted optical coherent tomography, SL-OCT, Heidelberg Engineering) on horizontal scans (Fig. 2). Endothelial cell count was measured in central cornea using Topcon SP-2000P specular microscope.

Statistical analysis was performed using the nonparametric tests: Wilcoxon test, Mann-Whitney U test and Spearman correlation coefficient. Regression analysis was calculated in order to determine the association between surgically induced astigmatism and the length of the clear corneal tunnel. All calculations were performed for the significance level $\alpha = 0.05$ using Microsoft Excel and AddinsoftXLStat 2008 software. A P value below 0.05 was considered statistically significant.

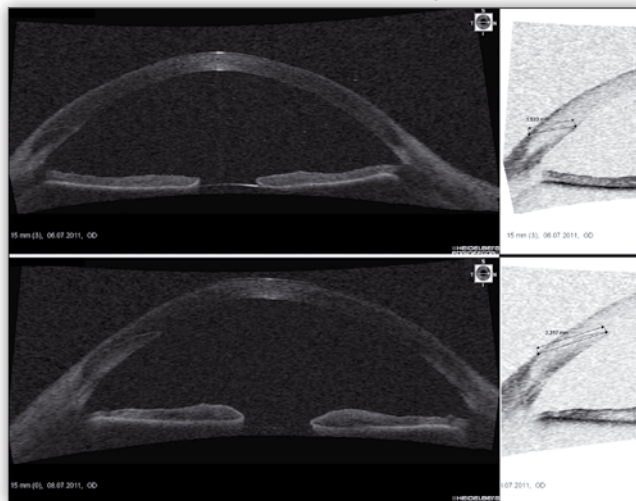


Fig. 2. Visualization of various chord lengths of corneal tunnels in 2.75 mm wide clear corneal incisions, used for standard phacoemulsification, with anterior segment OCT. The incision presented in the upper scan is 1.533 mm long, whereas the incision shown in the lower scan is 2.317 mm long.

Ryc. 2. Wizualizacja różnej długości cięciwy tuneli w czystej rogówce o szerokości 2.75 mm wykonywanych podczas standardowej fakoemulsyfikacji za pomocą OCT przedniego odcinka. Na górnym skanie jest widoczny tunel o długości 1,533 mm, na dolnym skanie zaś tunel ma długość 2,317 mm.

Results

All procedures were uneventful. We did not observe corneal burns or any other complications. SL-OCT confirmed adequate apposition of the epithelial and endothelial edges between the corneal anterior and posterior lips of the incision in all eyes at all examinations. There was no leakage or gaping.

The mean preoperative best corrected distance visual acuity (BCDVA) of 0.30 ± 0.24 improved to 0.94 ± 0.18 one month after the surgery. This difference was statistically significant ($p < 0.05$) (Fig. 3).

We observed a gradual reduction in the mean length of the clear corneal tunnel with time over the first month. The mean corneal tunnel length dropped from 1.84 ± 0.36 mm on day 1 to 1.72 ± 0.31 mm on day 7 postoperatively, and decreased even further to 1.59 ± 0.32 mm 1 month postoperatively (Fig. 4, 5). The observed differences were statistically significant ($p < 0.05$).

The mean preoperative corneal astigmatism in the examined group was 0.72 ± 0.39 D. It increased to 0.96 ± 0.7 D on day 1 and then dropped to 0.8 ± 0.44 D at 1 month postope-

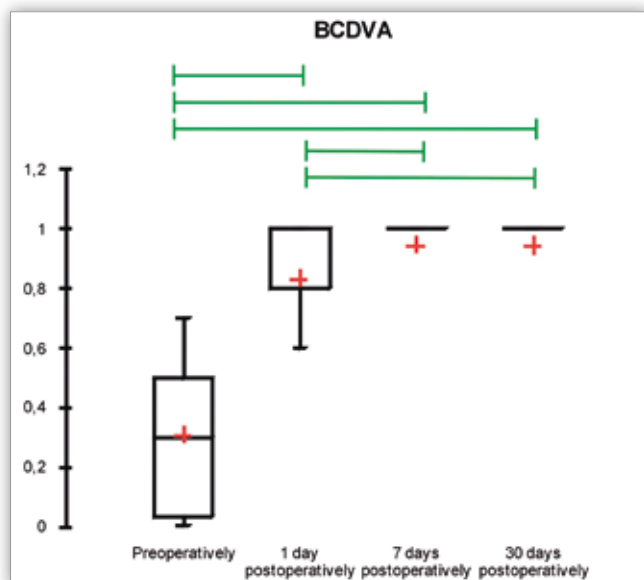


Fig. 3. BCDVA changes in the study cohort. Green lines indicate statistically significant differences.

Ryc. 3. Zmiany skorygowanej ostrości wzroku do dali u pacjentów z badanej grupy. Różnice istotne statystycznie zaznaczono zielonymi liniami.

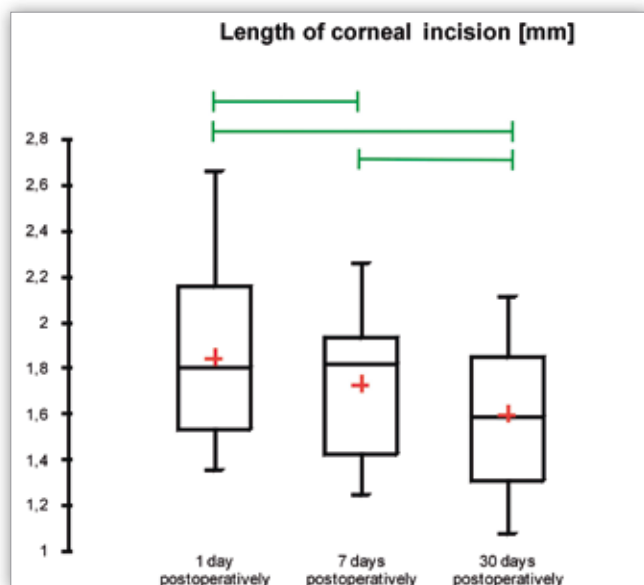


Fig. 4. Changes in the length of the 2.75 mm wide clear corneal incision. Green lines indicate statistically significant differences.

Ryc. 4. Zmiany długości cięcia rogówkowego o szerokości 2.75 mm. Różnice istotne statystycznie zaznaczono zielonymi liniami.

rately. However, comparisons of raw astigmatism values lack precision, as it disregards the changes of the cylinder angle, so it should not be used for corneal curvature assessment. That is why we calculated SIA using the vector analysis method, which precisely reflects changes in astigmatism (2). The mean SIA calculated using the vector method was 0.73 ± 0.58 D on day 1 and decreased to 0.51 ± 0.41 D at 1 month postoperatively (Fig. 6). The difference was statistically significant ($p < 0.05$).

We found a significant positive correlation between the chord length of corneal tunnel and SIA calculated with using vector analysis method at 1 month postoperatively (Spearman coefficient = 0.4, $p < 0.05$, Regression analysis $R^2 = 0.229$)

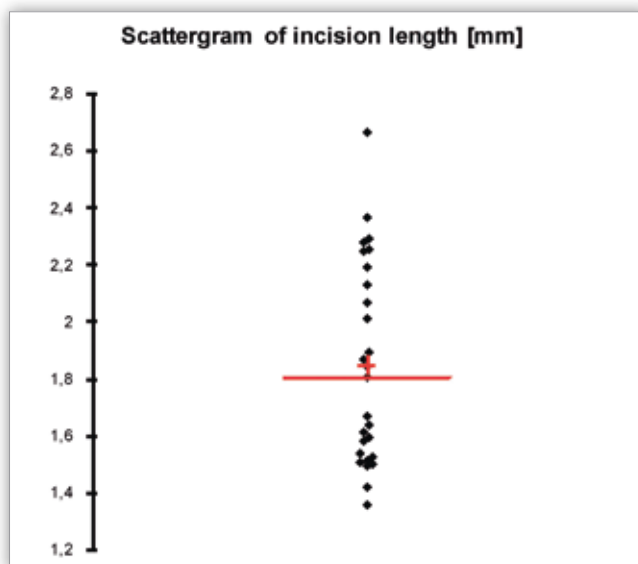


Fig. 5. Scatter plot presenting the length of 2.75 mm wide clear corneal tunnels at 1 month postoperatively.

Ryc. 5. Pomiary długości tunelu w przezierniej rogówce o szerokości 2.75 mm – wykonano je po miesiącu od zabiegu.

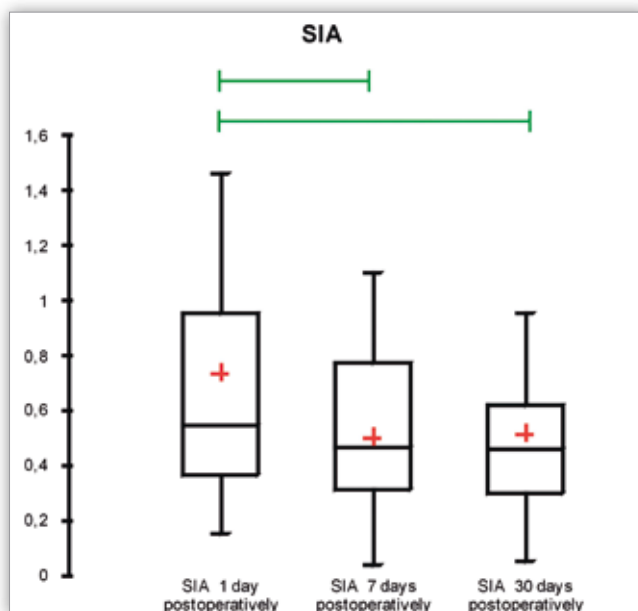


Fig. 6. Surgically induced astigmatism in the study cohort, assessed using vector method. Green lines indicate statistically significant differences.

Ryc. 6. Astygmatyzm indukowany chirurgicznie obliczony metodą wektorową u pacjentów z badanej grupy. Różnice istotne statystycznie zaznaczono zielonymi liniami.

(Fig. 7, Tab. I). Shorter tunnels were shown to induce lower astigmatism.

Mean central corneal thickness (CCT) was 0.51 ± 0.05 mm preoperatively, 0.56 ± 0.09 mm on day 1 and 0.51 ± 0.05 mm at 1 month postoperatively. The difference in CCT on day 1 postoperatively from baseline was statistically significant ($p < 0.05$), whereas the difference in CCT at 1 month postoperatively from baseline was statistically insignificant ($p > 0.05$) (Fig. 8). No correlation was found between the length of the tunnel and central corneal thickness at 1 month postoperatively (Spearman coefficient was 0.21, $p = 0.27$).

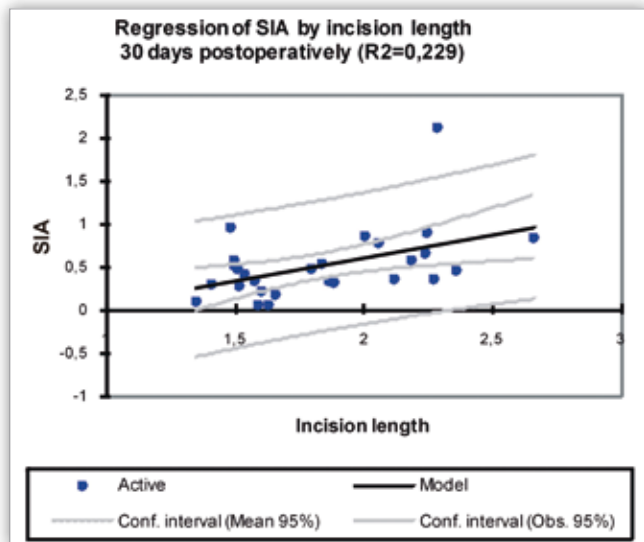


Fig. 7. Regression analysis for the association between SIA and corneal tunnel length at 1 month postoperatively.

Ryc. 7. Analiza regresji SIA w stosunku do długości tunelu rogówkowego przeprowadzona po 30 dniach od zabiegu.

Correlation/ Korelacja	P
Correlation between the chord length of CCI and SIA calculated using vector analysis/ Korelacja między długością tunelu rogówkowego i SIA obliczonym metodą wektorową	< 0.05
Correlation between the chord length of CCI and central corneal thickness/ Korelacja między długością tunelu rogówkowego a centralną grubością rogówki	> 0.05
Correlation between the chord length of CCI and corneal endothelial cell loss/ Korelacja między długością tunelu rogówkowego a gęstością komórek śródbłonka	> 0.05

Tab. I. Statistical analysis of correlations.

Tab. I. Wyniki analizy statystycznej korelacji.

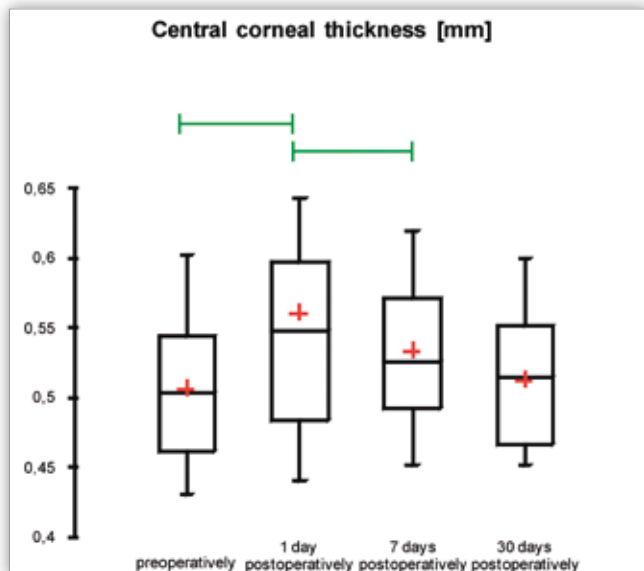


Fig. 8. Central corneal thickness changes in the study cohort. Green lines indicate statistically significant differences.

Ryc. 8. Zmiany grubości centralnej części rogówki u pacjentów z badanej grupy. Różnice istotne statystycznie zaznaczono zielonymi liniami.

Mean corneal endothelial cell density was 2483 ± 417 cells/mm² at baseline and decreased to 2325 ± 410 cells/mm² one month after the surgery (Fig. 9). The difference was statistically significant ($p < 0.05$). Mean corneal endothelial cell loss measured at 1 month postoperatively was 5.77%. No correlation was found between the length of the tunnel and corneal endothelial cell loss (Spearman coefficient = 0.06).

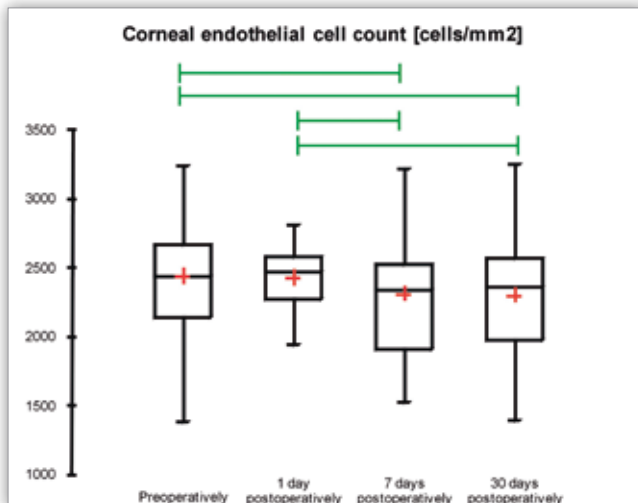


Fig. 9. Postoperative endothelial cell density. Green lines indicate statistically significant differences.

Ryc. 9. Gęstość śródbłonka rogówki – pomiar przeprowadzony po zabiegu. Różnice istotne statystycznie zaznaczono zielonymi liniami.

Discussion

The ultimate goal of constant development of cataract surgical techniques is to reduce surgically induced trauma. Currently, standard phacoemulsification requires creating a 2.2–2.75 mm wide corneal incision.

Surgically induced astigmatism after cataract surgery is a complex problem, as different factors affect the ultimate refractive outcome. It is widely known that the width of corneal incision created during phacoemulsification affects corneal wound integrity and surgically induced astigmatism. However, there are many other factors (i.e. preoperative astigmatism and location of incision) that influence the final refraction after cataract surgery (3). Generally, the length of clear corneal tunnel is not considered an important factor to impact the SIA.

SIA may impair the uncorrected distance visual acuity and require either surgical or spectacle correction, which adversely affects patient satisfaction with surgery.

Therefore, we decided to conduct a pioneering study in order to evaluate the effect of the length of the clear corneal incision created during standard phacoemulsification, on surgically induced astigmatism, central corneal thickness and corneal endothelial cell loss.

In our study all patients were operated using the same surgical technique, the same surgical settings, and the same type of surgical instruments, including the same type of the metal slit knife used to create the main incision and the same type of injector used to implant the IOL. In all patients clear corneal incision was created in the temporal position.

Torres et al. (4) found that surgical experience is an important factor pertaining to wound construction. Authors also

observed that 3.2 mm clear corneal incisions had some minor anatomic imperfections, such as gaping of the endothelial edge and incomplete wound sealing in the early postoperative period, which improved with time.

Fine et al. (5) examined the profile of clear corneal incision with anterior segment OCT and demonstrated that 3.5 mm wide clear corneal incisions are self-sealing when their chord length is about 2.0 mm. However the authors did not measure SIA.

Dupont-Monod et al. (6) used the anterior segment optical coherence tomography (AS-OCT) to analyze the in vivo architecture of clear corneal incisions after phacoemulsification and found that the 2.75 mm incision had an arcuate configuration, which corresponded to the knife movement. Our results confirm these results. Moreover, the authors did not observe relationship between the corneal incision angle and stromal edema at the incision site. It should be noted, though, that the central corneal thickness was not measured.

We observed a significant increase of central corneal thickness 1 day after the surgery, but no correlation was found between the length of the incision and central corneal thickness one month after the surgery. Most probably, the corneal healing process gradually resolves stromal edema at the incision site, which triggers postoperative fluctuations of SIA and the step-by-step shortening of the incision chord length. Additionally, the processes of healing and scarring, the decreasing corneal edema and shortening corneal incision are most likely to be responsible for changes to corneal curvature during the early postoperative period.

Elkady et al. (7) found that the quality of the incision influences the outcomes of cataract surgery and stated that smaller incisions, causing less trauma to the eye, yield better functional effect. Can et al. (8) observed a slow decrease of corneal incision length, thickness and angle during the postoperative period and concluded that the most likely cause of gradual changes in wound architecture was the resolution of edema in adjacent tissues.

The published literature lists different methods for calculating SIA. Out of them, we chose vector analysis, as the most frequently used method (9–13). Alio et al. (14) examined 100 eyes and demonstrated the SIA of 1.20 D calculated using vector analysis in patients after standard phacoemulsification, which is significantly more than in our group (0.73 ± 0.58 D one day after the surgery and 0.51 ± 0.41 D one month postoperatively). Similarly, Morcillo-Laiz et al. (15) conducted a study on 43 eyes after a standard 2.8 mm phacoemulsification and demonstrated the SIA of 0.49 ± 0.38 D at 1 month postoperatively, calculated using vector analysis. Cavallini et al. (16) demonstrated the SIA of 0.72 D at 1 month postoperatively, calculated using vector analysis in patients after 2.2 mm coaxial phacoemulsification, which is similar to our results. On the other hand, Yao et al. (17) examined 60 eyes and demonstrated the SIA of 1.29 ± 0.68 D in patients after 3.2 mm phacoemulsification. These values are significantly higher than our results.

In our previous study (18) the mean SIA calculated using vector analysis in eyes after standard phacoemulsification amounted to 0.77 ± 0.55 , which is similar to current findings. It should be emphasized that all studies evaluating SIA after phacoemulsification consider only the width of the incision, assuming that its length (corneal tunnel) is similar in all cases, so

its effect is negligible. Our study proves that there is the length of the clear corneal tunnel varies between the cases and that it impacts the SIA. This seems logical as the cornea is a three-dimensional structure and the corneal incision has a non-linear, two-dimensional (it has width and length) construction. Knowing this, it seems important to balance the optimum tunnel length, as longer incisions tend to induce higher astigmatism and shorter incisions might have sealing issues, thus increasing the risk of endophthalmitis.

The drawbacks of this study were: a relatively small study cohort, the fact that the width of the surgical knife determined the width of the corneal incision and the IOL implantation-dependent changes to its width were not measured (although the same type of injector was used in all patients) as well as the impossibility to pre-define the CCI lengths, which could only have been measured postoperatively. Yet, to the best of our knowledge, this is the first study utilizing vector analysis to evaluate the effect of the corneal tunnel length in a standard phacoemulsification on SIA, which significantly contributes to our knowledge.

Conclusions

The results suggest that the length of corneal tunnel significantly affects the ultimate surgically induced astigmatism after uneventful standard phacoemulsification. However, it does not seem to influence the central corneal thickness and corneal endothelial cell loss. Shorter corneal incisions induced lower astigmatism as compared to longer corneal incisions of the same width and location.

Further studies in a larger cohort are required to unequivocally determine the effect of corneal tunnel length on SIA. Future surgical techniques offering better repeatability may help achieve consistently improved outcomes. Using laser techniques likely to enable patient classification into subgroups according to the predefined CCI lengths.

Financial Disclosure

Authors confirm that they do not have any commercial or proprietary interest in any product or company mentioned. Authors report no financial support.

References:

1. Chylack LT Jr., Wolfe JK, Singer DM: *The Lens Opacities Classification System III. The Longitudinal Study of Cataract Study Group*. Arch Ophthalmol. 1993;111:831–836.
2. Wilczynska O, Wilczynski M: *Metody obliczania niezborności indukowanej chirurgicznie*. Klin Oczna. 2009; 111: 249–252.
3. Barequet IS, Yu E, Vitale S, Cassard S, Azar DT, Stark WJ: *Astigmatism outcomes of horizontal temporal versus nasal clear corneal incision cataract surgery*. J Cataract Refract Surg. 2004; 30: 418–423.
4. Torres LF, Saez-Espinola F, Colina JF, Retchkiman M, Patel MR, Agurto R, et al.: *In vivo architectural analysis of 3.2 mm clear corneal incisions for phacoemulsification using optical coherence tomography*. J Cataract Refract Surg. 2006; 32: 1820–1826.
5. Fine H, Hoffman RS, Packer M: *Profile of clear corneal cataract incisions demonstrated by ocular coherence tomography*. J Cataract Refract Surg. 2007; 33: 94–97.

6. Dupont-Monod S, Labbe A, Fayol N, Chassignol A, Bourges JL, Baudouin C: *In vivo architectural analysis of clear corneal incisions using anterior segment optical coherence tomography*. J Cataract Refract Surg. 2009; 35: 444–450.
7. Elkady B, Piner D, Alio JL: *Corneal incision quality: Microincision cataract surgery versus microcoaxial phacoemulsification*. J Cataract Refract Surg. 2009; 35: 466–474.
8. Can I, Bayhan HH, Celik H, Ceran BB: *Anterior segment optical coherence tomography evaluation and comparison of main clear corneal incisions in microcoaxial and biaxial cataract surgery*. J Cataract Refract Surg. 2011; 37: 490–500.
9. Nielsen PJ, Yanoff M, Duker JS: *Complications and outcomes: data collection and analysis*. In CD-ROM: Ophthalmology, Mosby, St Louis, 1998.
10. Naylor EJ: *Astigmatic difference in refractive errors*. Br J Ophthalmol. 1968; 52: 422–425.
11. Holladay JT, Cravy TV, Koch DD: *Calculating the surgically induced refractive change following ocular surgery*. J Cataract Refract Surg. 1992; 18: 429–443.
12. Holladay JT, Dudeja DR, Koch DD: *Evaluating and reporting astigmatism for individual and aggregate data*. J Cataract Refract Surg. 1998; 24: 57–65.
13. Kaye SB, Patterson A: *Analyzing refractive changes after anterior segment surgery*. J Cataract Refract Surg. 2001; 27: 50–60.
14. Alio JL, Rodriguez-Prats JL, Galal A, Ramzy M: *Outcomes of microincision cataract surgery versus coaxial phacoemulsification*. Ophthalmology. 2005; 112: 1997–2003.
15. Morcillo-Laiz R, Zato MA, Muaoz-Negrete FJ, Arnalich F: *Surgically induced astigmatism after biaxial phacoemulsification compared to coaxial phacoemulsification*. Eye. 2009; 23: 835–839.
16. Cavallini GM, Campi L, Masini C, Pelloni S, Pupino A: *Bimanual microphacoemulsification versus coaxial miniphacoemulsification: Prospective study*. J Cataract Refract Surg. 2007; 33: 387–392.
17. Yao K, Tang X, Ye P: *Corneal astigmatism, high order aberrations and optical quality after cataract surgery: microincision versus small incision*. J Refract Surg. 2006; 22: S1079–S1082.
18. Wilczynski M, Supady E, Loba P, Synder A, Palenga-Pydyn D, Omulecki W: *Evaluation of surgically induced astigmatism after coaxial phacoemulsification through 1.8 mm microincision and after standard phacoemulsification through 2.75 mm incision*. Klin Oczna. 2011; 113: 314–320.

The study was originally received 22.11.2014 (1496)/
Praca wpłynęła do Redakcji 22.11.2014 r. (1496)
Accepted for publication 02.11.2015/
Zakwalifikowano do druku 02.11.2015 r.

Reprint requests to (Adres do korespondencji):
dr hab. n. med. Michał Wilczyński
Klinika Chorób Oczu Uniwersytetu Medycznego w Łodzi
Szpital Kliniczny Nr. 1 im. N. Barlickiego
ul. Kopcińskiego 22
90-153 Łódź
e-mail: michal.wilczynski@umed.lodz.pl