

Is subcutaneous laparoscopic recti abdominis repair (SCOLA) a safe approach to repair diastasis of the rectus abdominis muscles (DMRA)? A brief review

Czy technika podskórnej laparoskopowej naprawy rozstępu mięśni prostych brzucha (SCOLA) jest bezpieczną metodą leczenia chirurgicznego rozstępu mięśni prostych brzucha (DMRA)? Krótki przegląd piśmiennictwa

Danilo Coco¹, Silvana Leanza²

¹Department of General Surgery, Ospedali Riuniti Marche Nord, Pesaro, Italy

²Department of General Surgery, Carlo Urbani Hospital, Jesi, Ancona, Italy

Medical Studies/Studia Medyczne 2022; 38 (3): 221–225

DOI: <https://doi.org/10.5114/ms.2022.119921>

Key words: diastasis of the rectus abdominis (DMRA), laparoscopic repair, subcutaneous laparoscopic rectus abdominis diastasis repair (SCOLA).

Słowa kluczowe: rozstępy mięśni prostych brzucha (DMRA), naprawa laparoskopowa, podskórna laparoskopowa naprawa rozstępu mięśni prostych brzucha (SCOLA).

Abstract

Diastasis of the rectus abdominis muscles is defined according to Beer's classification: the distance between the straight abdominal muscles greater than 2.2 cm, measured 3 cm above the belly button with relaxed abdomen. The conditions in which it occurs most frequently are 12 months post-partum or in obese subjects who have suffered evident weight loss. We retrospectively evaluated PubMed databases, Embase, and the Cochrane Library by applying various combinations of the subject-related terms. The search terms identified with the medical subject heading (MeSH) were "diastasis of the rectus abdominis (DMRA), laparoscopic repair, subcutaneous laparoscopic recti abdominis repair". The aim of the study was to describe laparoscopic techniques for the correction of combined ventral hernia with the plication of the diastasis of the rectus abdominis, muscle and to present the results.

Streszczenie

Zgodnie z klasyfikacją zaproponowaną przez Beera rozstępy mięśni prostych brzucha stwierdza się, gdy poszerzenie przestrzeni między brzegami mięśni prostych przekracza 2,2 cm przy pomiarze wykonywanym przy rozluźnionym brzuchu na wysokości 3 cm nad pępkiem. Zaburzenie występuje najczęściej w okresie 12 miesięcy po porodzie lub u osób otyłych, u których nastąpiła znacząca utrata masy ciała. Na potrzeby pracy dokonano retrospektywnego przeglądu publikacji w bazach danych PubMed, Embase i Cochrane Library, stosując różne kombinacje terminów związanych z analizowaną tematyką. Za pomocą medycznych nagłówków tematycznych (MeSH) zidentyfikowano następujące terminy wyszukiwania: rozstępy mięśni prostych brzucha (DMRA), naprawa laparoskopowa, podskórna laparoskopowa naprawa rozstępu mięśni prostych brzucha. Celem pracy było opisanie laparoskopowych technik naprawy przepukliny brzusznej wraz z zeszcieniem brzegów rozstępu mięśni prostych brzucha oraz przedstawienie wyników uzyskiwanych przy zastosowaniu tej metody.

Introduction

By diastasis of the rectus abdominis (DMRA) we mean distancing of the medial margins of the rectus muscles of the midline, usually greater than 2 cm. Beer *et al.* [1], in their classification, defined DMRA as the distance between the straight abdominal muscles greater than 2.2 cm, measured 3 cm above the navel with a relaxed abdomen. Clinically it manifests as swelling in the anterior wall of the abdomen accentuated by contraction of the abdominal muscles and/or

an increase in intra-abdominal pressure. The differential diagnosis is usually with abdominal wall herniation [2]. Usually, diastasis of the rectum does not involve clinical symptoms but, often, only aesthetic symptoms, which can be treated by plastic surgeons; however, the presence of associated abdominal hernia means that general surgeons treat this pathology [3, 4]. Plastic surgeons perform DMRA treatment in patients with excess skin, and usually the technique is open and is performed with a large transverse inci-

sion on the Pfannenstiel area associated with dermolipectomy. Patients with abdominal hernia associated with DMRA, on the other hand, are treated by general surgeons with plication techniques more or less mesh positioning. In the literature it can be seen that the presence of a large hernia and the non-positioning of mesh greatly increase the risk of recurrence. To improve these results, in the 1990s, the technique of plication of the abdominal fascia was associated with the open technique plus the use of laparoscopic mesh [5–7]. Recent studies by Arroyo *et al.* [8] and a prospective cohort – Danish Ventral Hernia Database on 4786 patients [9] – have shown results that support routine use of mesh, even in small hernias, demonstrating a reduction of recurrence rate from 11% to 1% and from 5% to 2%, respectively. These studies revealed a similar rate of complications based on suture alone. The laparoscopic technique is divided into diastasis repair and intraperitoneal, extraperitoneal, and subcutaneous hernia repair. However, the results were mixed alternatives seem questionable.

The aim of the present study was to describe laparoscopic techniques for the correction of combined ventral hernias with plication of the diastasis of the rectus abdominis muscle, and to present the results.

Material and methods

We retrospectively evaluated the PubMed, Embase, and Cochrane Library databases by applying various combinations of the subject-related terms. The search terms identified with the medical subject heading (MeSH) were “diastasis of the rectus abdominis (DMRA), laparoscopic repair, subcutaneous laparoscopic recti abdominis repair (SCOLA)”. The databases were used to collect the literature published up to 2010. Inclusion criteria were reports that included the following: diastasis of the rectus abdominis (DMRA), laparoscopic repair, subcutaneous laparoscopic recti abdominis repair”. Exclusion criteria were as follows: case reports, letters, comments, and abstracts. Duplicate reports and studies that contained noncancer patients were also excluded. No language restriction was applied in the search strategy. Two independent researchers performed the review. The PRISMA guidelines were followed during all stages of this systematic review. Recommendations were protocol, research question, search strategy, study eligibility, data extraction, study designs, risk of bias, publication bias, heterogeneity, and statistical analysis. The systematic literature search found 2500 articles, 330 of which were duplicates and hence were excluded from analysis. The titles and abstracts from the remaining 2170 articles were assessed. After careful evaluation, 2160 articles were determined to be unrelated to our study and subsequently excluded. The full text of the remaining 10 articles was thoroughly assessed. Case reports, editorials, letters to the editor, and general re-

views were then excluded. A total of 6 articles were ultimately included for this review, describing laparoscopic subcutaneous repair of concomitant ventral hernias and rectus diastasis. After excluding repetitive reports, 4 manuscripts comprised the relevant literature for this review article.

Results

Claus *et al.* [2] applied the subcutaneous onlay laparoscopic approach (SCOLA) in 48 patients to correct ventral hernia associated with correction of diastasis of the rectus abdominis muscles (DMRA) by pre-aponeurotic endoscopic technique. The authors stated there were no intra-operative complications and no conversion rate. The technique required a mean operative time of about 93.5 min. Seroma was the most frequent complication in 27% and 2% of surgical wound infections, and 2% presented subcutaneous tissue retraction/fibrosis. Median follow-up was 8 months. Juárez Muas *et al.* [10] treated 50 patients affected by diastasis recti from 50 mm to > 81 mm (14.9–55%) using subcutaneous recti plication with light/intermediate (90%) and heavy (10%) polypropylene meshes fixed with absorbable (62%) and non-absorbable material (38%). In 32% of patients, external oblique release was necessary. The surgical time was 83 min. Seroma was a finding in 12% of cases. The average hospital stay was 1.3 days, with pain level 3/10 according to Acute Visual Score (AVS). The patients returned to their usual activities after 16.5 days. No complications or recurrences were observed at 39 months. Köhler *et al.* [11] used subcutaneous technique in 20 patients affected by rectus diastasis with symptomatic umbilical and/or epigastric hernias, using a fully absorbable synthetic mesh placed in a supra-aponeurotic position. The mean operating time was 79 min, hospital stay 4 days. Two patients sustained symptomatic seroma. There were no recurrences at a follow-up period of 5 months. In their prospective cohort study, Dong *et al.* [12] applied the SCOLA technique with use of robot surgery, demonstrating that this approach was safe and effective for patients presenting with small midline ventral hernias and concomitant DR. They showed a mean operative time of 146 (46.3) min; 18.8% of seromas; 12.5% of hernia recurrence with mean follow-up of 2 months (63 days) (Table 1, Figure 1).

Discussion

Diastasis of the rectus abdominis muscles is defined according to Beer’s classification: the distance between the straight abdominal muscles greater than 2.2 cm, measured 3 cm above the belly button with relaxed abdomen. The conditions in which it occurs most frequently are 12 months post-partum or in obese subjects who have suffered evident weight loss [13]. Most patients with DMRA do not have symptoms related to a hernia, so there is no pain, faecal ob-

Table 1. Results

Author (year)	Number of patients	Research type	Technique	Recurrence rate	Mesh	Hernia/DMRA size	Timing of drainages	Complications	Conversion rate	Median operation time
Claus <i>et al.</i> (2018)	48 patients	Retrospective	Subcutaneous pre-aponeurotic endoscopic technique	2%	Polypropylene mesh	Hernia size 2.3 cm (1.5–4 cm) DMRA: was 4.05 cm (3–6 cm)	N/A	Seromas 27% Cutaneous retraction 2%	0%	93.5 min (70–150)
Juárez Muas <i>et al.</i> (2018)	50 patients	Prospective	Subcutaneous pre-aponeurotic endoscopic technique	0%	The light macroporous polypropylene prostheses (76%), followed by intermediate (14%) and heavy ones (10%)	Diastasis recti < 50 mm – 1.97 in. (55.5%), from 51 to 80 mm – 2.01 to 3.14 (29.6%), and > 81 mm – 3.18 (14.9%)	3.68 ±1.8 days permanence	Seroma (12%)	0%	83 ±20.8 min
Köhler <i>et al.</i> (2018)	20 patients	Retrospective	Subcutaneous pre-aponeurotic hybrid-endoscopic technique	2/20	Fully absorbable synthetic mesh 15.8 cm in length and 5.2 cm in width	1.5 cm	N/A	Seroma 2/20	0%	79 min (range: 48–133)
Dong <i>et al.</i> (2020)	16 patients	Prospective cohort study	Subcutaneous pre-aponeurotic endoscopic technique/laparoscopic and robotic	12.5%		1.9 (0.7) cm		Seroma 18%		146 (46.3) min

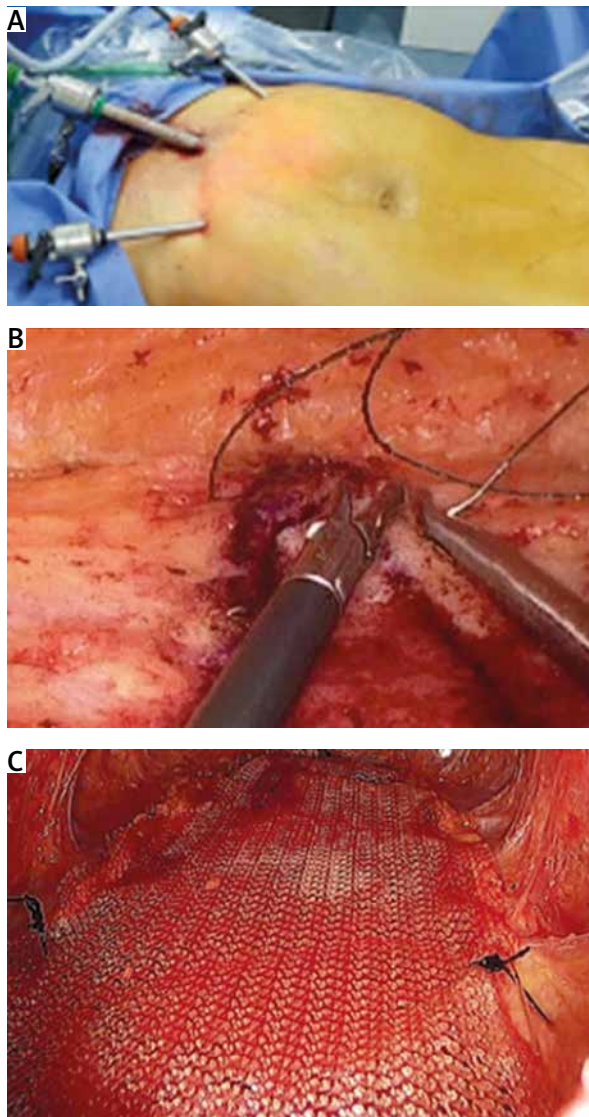


Figure 1. SCOLA technique. **A** – Placement of three trocar in suprapubic region. **B** – Synthesis of the anterior fascia of the rectus muscles with continuous absorbable suture. **C** – Placement of subcutaneous mesh

struction, or risk of intestinal strangulation; hence, it is usually treated conservatively, or in patients with complaints due to the absence of aesthetics of abdominal bulging or associated pendulous abdomen it is possible to perform abdominoplasty and repair of the DMRA by plastic surgeons. However, the thinning of the linea alba is important risk factor for the development of abdominal wall hernia. For this reason, the frequent concomitance of hernias in patients with DMRA often leads the patient to refer to a general surgeon for the repair of the abdominal hernia and consequently of the DMRA. A single surgical approach is strongly recommended given the high inci-

dence of umbilical and/or epigastric hernias with Recti muscles Diastasis (RD) (up to 50%) [14]. The use of the Laparoscopic Intraperitoneal Onlay Mesh (IPOM) PLUS technique brings the risks of intestinal lesions, adhesences, and intestinal obstruction or postoperative neuralgias for the use of laparoscopic access and use of intracavitary prosthesis and its fixation media, giving the patients no long-term cosmetic results in the early postoperative period [15]. In 2015, Bellido Luque *et al.* [16] stated that the preaponeurotic endoscopic approach seemed to be the right therapeutical option for recti diastasis. Their work was strengthened by the studies performed in 2016 by Juárez Muas [10], who presented preaponeurotic endoscopic repair with prosthesis reinforcement with recti plication using bearded sutures. Not entering the abdominal cavity, as in the laparoscopic approach, seemed to reduce laparoscopic complications and mesh-related complications. Endoscopic subcutaneous surgery allows the performance of an accurate dissection, haemostasis control, and washing devitalized fat tissue before placing the prosthesis [10]. With this technique, the percentage of seromas or wound infections does not appear to increase; however, in 100% of cases hypoesthesia was noted in the immediate postoperative period. There was also a total recovery from 2 to 6 months after surgery. This technique was called SCOLA (subcutaneous onlay laparoscopic approach) [10]. Another alternative is ELAR as endoscopic-assisted reconstruction of the linea alba. It represents an hybrid approach from a peri-umbilical incision with extension 2–3 cm higher assisted by an endoscopic vision aid for dissection of the pre-aponeurotic space until the xiphoid, and after reducing the diastasis with the use of sutures, reinforced by the placement of polypropylene mesh [17, 18]. Alternatives to the pre-aponeurotic techniques have been described as MILOS by Schwarz *et al.* [19] described as hybrid technique that put the mesh in the retromuscular space through a peri-umbilical incision or the totally extraperitoneal techniques by Daes [15] and Belyansky *et al.* [20]. Recent studies have shown that the non-use of mesh, the use of absorbable sutures, and the concomitant presence of diastasis are among the main technical risk factors for increased relapse [8, 9, 11]. The 5-year risk of all mesh-related complications requiring subsequent surgery seems to be about 5%, demonstrating positive outcomes and low incidence of hernia recurrence at 18 months [21].

Conclusions

Minimally invasive non-intraperitoneal repair techniques will gain more consensus between surgeons because they seem to respect the new paradigm shift of surgical techniques. These techniques represent everything that requires the repair of a wall defect: minimally invasive, closure of the defect, mesh

not outside of the abdominal cavity, minimization of mesh fixation.

Acknowledgments

The authors are thankful for the excellent illustrations provided by Silvana Leanza, MD.

Conflict of interest

The authors declare no conflict of interest.

References

1. Beer GM, Schuster A, Seifert B, Manestar M, Mihic-Probst D, Weber SA. The normal width of the linea alba in nulliparous women. *Clin Anat* 2009; 22: 706-711.
2. Claus CMP, Malcher F, Cavazzola LT, Furtado M, Morrell A, Azevedo M, Meirelles LG, Santos H, Garcia R. Subcutaneous onlay laparoscopic approach (SCOLA) for ventral hernia and rectus abdominis diastasis repair: technical description and initial results. *Arq Bras Cir Dig* 2018; 31: e1399.
3. Brauman D. Diastasis recti: clinical anatomy. *Plast Reconstr Surg* 2008; 122: 1564-1569.
4. Mommers EHH, Ponten JEH, Al Omar AK, de Vries Reilingh TS, Bouvy ND, Nienhuijs SW. The general surgeon's perspective of rectus diastasis. A systematic review of treatment options. *Surg Endosc* 2017; 31: 4934-4949.
5. Hickey F, Finch JG, Khanna A. A systematic review on the outcomes of correction of diastasis of the recti. *Hernia* 2011; 15: 607-614.
6. Köckerling F, Botsinis MD, Rohde C, Reinpold W, Schug-Pass C. Endoscopic-assisted linea alba reconstruction: New technique for treatment of symptomatic umbilical, trocar, and/or epigastric hernias with concomitant rectus abdominis diastasis. *Eur Surg* 2017; 49: 71-75.
7. Zukowski ML, Ash K, Spencer D, Malanoski M, Moore G. Endoscopic intracorporeal abdominoplasty: a review of 85 cases. *Plast Reconstr Surg* 1998; 102: 516-527.
8. Arroyo A, García P, Pérez F, Andreu J, Candela F, Calpena R. Randomized clinical trial comparing suture and mesh repair of umbilical hernia in adults. *Br J Surg* 2001; 88: 1321-1323.
9. Christoffersen MW, Helgstrand F, Rosenberg J, Kehlet H, Bisgaard T. Lower reoperation rate for recurrence after mesh versus sutured elective repair in small umbilical and epigastric hernias. A nationwide register study. *World J Surg* 2013; 37: 2548-2552.
10. Juárez Muas DM. Preaponeurotic endoscopic repair (REPA) of diastasis recti associated or not to midline hernias. *Surg Endosc* 2019; 33: 1777-1782.
11. Köhler G, Fischer I, Kaltenböck R, Schrittwieser R. Minimal invasive linea alba reconstruction for the treatment of umbilical and epigastric hernias with coexisting rectus abdominis diastasis. *J Laparoendosc Adv Surg Tech A* 2018; 28: 1223-1228.
12. Dong CT, Sreeramoju P, Pechman DM, Weithorn D, Camacho D, Malcher F. SubCutaneous OnLay endoscopic Approach (SCOLA) mesh repair for small midline ventral hernias with diastasis recti: an initial US experience. *Surg Endosc* 2021; 35: 6449-6454.
13. Sperstad JB, Tennfjord MK, Hilde G, Ellström-Eng M, Bø K. Diastasis recti abdominis during pregnancy and 12 months after childbirth: prevalence, risk factors and report of lumbopelvic pain. *Br J Sports Med* 2016; 50: 1092-1096.
14. Köhler G, Luketina RR, Emmanuel K. Sutured repair of primary small umbilical and epigastric hernias: concomitant rectus diastasis is a significant risk factor for recurrence. *World J Surg* 2015; 39: 121-126.
15. Daes J. Evolución de la reparación laparoscópica de las hernias ventrales y del sitio de la incisión. *Rev Hispanoam Hernia* 2016; 4: 83-85.
16. Bellido Luque J, Bellido Luque A, Valdivia J, Suarez Gráu JM, Gomez Menchero J, García Moreno J, Guadalajara Jurado J. Totally endoscopic surgery on diastasis recti associated with midline hernias. The advantages of a minimally invasive approach. Prospective cohort study. *Hernia* 2015; 19: 493-501.
17. Köckerling F, Botsinis MD, Rohde C, Reinpold W. Endoscopic-assisted linea alba reconstruction plus mesh augmentation for treatment of umbilical and/or epigastric hernias and rectus abdominis diastasis – early results. *Front Surg* 2016; 3: 27.
18. Köckerling F, Botsinis MD, Rohde C, Reinpold W, Schug-Pass C. Endoscopic assisted linea alba reconstruction: New technique for treatment of symptomatic umbilical, trocar, and/or epigastric hernias with concomitant rectus abdominis diastasis. *Eur Surg* 2017; 49: 71-75.
19. Schwarz J, Reinpold W, Bittner R. Endoscopic mini/less open sublay technique(EMILOS) – a new technique for ventral hernia repair. *Langenbecks Arch Surg* 2017; 402: 173-180.
20. Belyansky I, Daes J, Radu VG, Balasubramanian R, Reza Zahiri H, Weltz AS, Sibia US, Park A, Novitsky Y. A novel approach using the enhanced-view totally extraperitoneal (eTEP) technique for laparoscopic retromuscular hernia repair. *Surg Endosc* 2018; 32: 1525-1532.
21. Roth JS, Anthone GJ, Selzer DJ, et al. Prospective evaluation of poly-4-hydroxybutyrate mesh in CDC class I/ high-risk ventral and incisional hernia repair: 18-month followup. *Surg Endosc* 2018; 32: 1929-1936.

Address for correspondence:

Danilo Coco MD
Department of General Surgery
Ospedali Riuniti Marche Nord
Pesaro, Italy
E-mail: webcostruction@msn.com