

Tuberculosis and tuberculosis-associated immune reconstitution inflammatory syndrome in HIV: immunological review of manifestation and immunopathogenesis

Chaitenya Verma^{1,2}, Bharati Swami^{1,3}, Vishwanath Upadhyay^{2,4}, Aayushi Singh¹, Vandana Anang¹, Shakuntala S.K. Saraswati¹, Ankush K. Rana¹

¹Infectious Disease Immunology, Dr. B.R. Ambedkar Center for Biomedical Research, University of Delhi, Delhi, India

²Department of Medicine, All India Institute of Medical Sciences, New Delhi, India

³Product Development Cell-1, National Institute of Immunology, New Delhi, India

⁴Jamia Hamdard Institute of Molecular Medicine, Hamdard University, Delhi, India

Abstract

Tuberculosis (TB) is the most common opportunistic infection that makes human immunodeficiency virus (HIV) infection more complicated. TB-immune reconstitution inflammatory syndrome (TB-IRIS) mainly refers to an excessive immune response among HIV-infected patients. In HIV-infected patients, IRIS occurs after initiation of antiretroviral therapy (ART), irrespective of increased CD4 count and effective suppression of HIV viremia; IRIS may occur at any stage in the progression of immunodeficiency and manifests with weakened immune system. IRIS is associated with various inflammatory processes as the outcome of immunological reaction against a variety of opportunistic infections (OIs). Currently, there is no reliable biological marker available for diagnosis of TB-IRIS. In accordance with current clinical case definition, deterioration of clinical and radiological symptoms of pre-existing TB infection in HIV patients is called “paradoxical TB-IRIS”. The appearance of a previously undiagnosed or new TB infection during ART treatment is called “unmasking TB-IRIS”. IRIS is a challenging complication for researchers and medical practitioners, as the incidence of IRIS is between 3-40% in patients initiated on ART. The variation in incidence probably reflects the differences in case definitions, patients’ population studied, and individual resource-limited settings. The immune pathogenesis of IRIS is poorly understood, and epidemiology partially defined. The complication for clinicians remains challenging in terms of diagnosis and treatment as well as patients’ suffering, even though, the mortality is typically low.

HIV AIDS Rev 2020; 19, 2: 67-73

DOI: <https://doi.org/10.5114/hivar.2020.96486>

Key words: HIV, T cells, unmasking, paradoxical, TB-IRIS.

Introduction

Tuberculosis (TB)-associated immune reconstitution inflammatory syndrome (IRIS) is a result of rapid re-establishment of the excessive and atypical immune response against

live and dead/latent TB [1]. It may occur in human immunodeficiency virus (HIV)-infected or, more infrequently, non-infected patients. However, among HIV-infected patients after administration of antiretroviral therapy (ART), it leads to patient’s suppression of HIV replication and im-

Address for correspondence: Dr. Chaitenya Verma, Infectious Disease Immunology, Dr. B.R. Ambedkar Center for Biomedical Research, University of Delhi, e-mail: chaitenya999@gmail.com

Article history:
Received: 28.05.2019
Received in revised form: 31.07.2019
Accepted: 09.10.2019
Available online: 19.06.2020



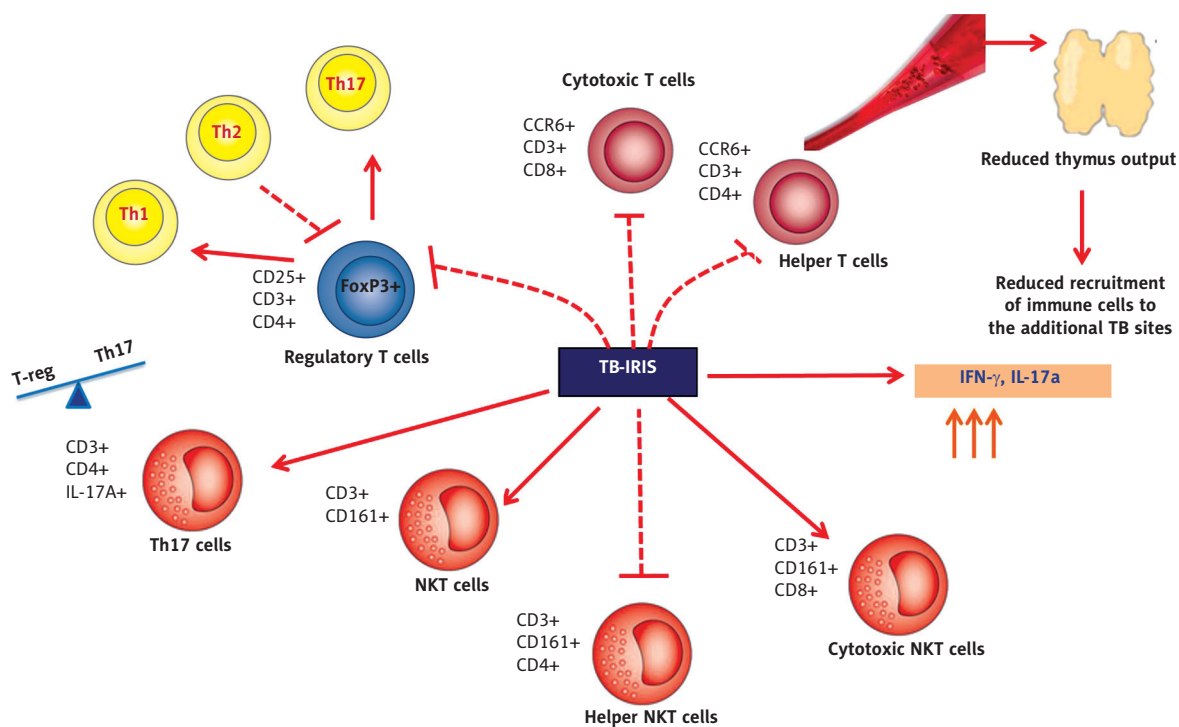


Figure 1. Immune mechanism during tuberculosis-immune reconstitution inflammatory syndrome in human immunodeficiency virus

provement in CD4⁺ T-cell count, which shows restoration of pathogen-specific immunity [2-4]. This immunological development directly indicates the development of immunity against pathogen or any opportunistic infections (OIs), resulting in patients' quality of life improvement and prolong survival [3]. However, another group of infected patients experiences different clinical challenges; their partially or dysregulated restored immunity during ART treatment creates IRIS conditions. IRIS is a spectrum of deteriorated clinical symptoms and immunological worsening against opportunistic pathogens (Figure 1), and how immune cells get affected during TB-IRIS [5]. The confirmation of the disease relies primarily upon case definitions involving clinical and laboratory criteria. There is no set definition, and no biological tests are available for the diagnosis of this disease. In accordance with a current case definition, worsening of clinical and radiological symptoms of pre-existing infections in HIV patients is called "paradoxical IRIS". The appearance of previously undiagnosed or new infection is called "unmasking TB-IRIS" [6]. This review summarizes the available literature on case definitions, epidemiology, diagnosis, pathogenic mechanisms, and possible immunological aspects of TB-IRIS.

Definitions of tuberculosis-associated immune reconstitution inflammatory syndrome

First ever case definition was published by French *et al.* [6]. In 2005, there was another case definition of IRIS proposed

by Shelburne *et al.* [7]. These both case definitions are widely used, however, there is no such consensus case definition available, which is particularly specified for opportunistic infection. The only case definition for TB-associated IRIS (TB-IRIS) was proposed by Colebunders *et al.* [8]. A team of researchers, working in the area of HIV and HIV-TB coinfection, organized a meeting in Kampala (Uganda), and International Network to study HIV-associated IRIS (INSHI) was established in 2006 to manage these kind of difficulties. The aim of this meeting was to develop a consensus case definition for tuberculosis-associated IRIS. These case definitions are appropriate to limited resource setting.

Case definition for diagnosis of immune reconstitution inflammatory syndrome

Since no gold standard definition for diagnosis of IRIS is available, patients suffer clinical deterioration and numerous immunological challenges. In the year 2004, French *et al.* and in 2006, Robertson *et al.* proposed general case definitions for IRIS [6, 8]. Diagnosis of IRIS requires two major criteria plus two minor criteria to be fulfilled (Table 1). These proposed general definitions supported clinicians in the diagnosis of disease in patients; however, a more specific definition to differentiate between various forms of IRIS is required. HIV-infected individuals have a greater risk of acquiring *Mycobacterium tuberculosis* infection and developing TB, thus, a higher probability of progression of HIV infection towards AIDS disease.

Table 1. Evaluations of immune reconstitution inflammatory syndrome

Defined by	French <i>et al.</i> , 2004	Robertson <i>et al.</i> , 2006
Major criteria	<ul style="list-style-type: none"> • Localized disease • Exaggerated inflammatory reaction • Atypical inflammatory response in affected tissues • Progression of organ dysfunction or enlargement of pre-existing lesions after definite clinical • Improvement with pathogen-specific therapy prior to ART and exclusion of treatment toxicity and new diagnoses • Decrease in plasma HIV RNA level > 1 log₁₀ copies/ml 	<ul style="list-style-type: none"> • Worsening symptoms of inflammation/infection • Temporal relationship with starting antiretroviral treatment • Symptoms not clarified by newly acquired infection or disease, or the usual course of earlier acquired disease • > 1 log₁₀ decrease in plasma HIV load
Minor criteria	<ul style="list-style-type: none"> • Increase in CD4+ cell count after ART • Increase in an immune response specific to relevant pathogen • Spontaneous resolution of disease with continuation of ART 	<ul style="list-style-type: none"> • Increase in CD4+ cell count of ≥ 25 cells/μl • Biopsy demonstrating well-formed granulomatous • Inflammation or unusually exuberant inflammatory response

HIV – human immunodeficiency virus, TB-IRIS – tuberculosis-associated immune reconstitution inflammatory syndrome, VL – viral load, ART – antiretroviral therapy, RNA – ribonucleic acid

Paradoxical and unmasking tuberculosis-associated immune reconstitution inflammatory syndrome

It is important to distinguish between subclinical infections firstly appearing during ART and clinically evident infections already existing at the initiation of treatment, which often paradoxically become worse during therapy. For a clinician, it is critical to understand that anything is possible in case of IRIS, in which ART may seem to be unsuccessful. Furthermore, patients typically have a good prognosis [6, 7]. As a form of worsening during TB therapy, paradoxical TB-IRIS often appears more severe, and frequently includes multiple organ systems. Paradoxical reactions are also far more common in the period after ART instigation than in patients without HIV and patients infected with HIV not on ART. In unmasking TB-IRIS patients, TB could be diagnosed before ART, but due to low sensitivity of sputum smear and chest radiography in patients with progressive immunosuppression, the diagnosis may be missed prior ART initiation. Instead, when ART is initiated, patients may have subclinical TB that reactivate latent TB, or TB reinfection may occur around the time of ART initiation [9, 10]. Possibly, an increased clinical surveillance of patients also plays a role. There is a scale of clinical presentations among such TB cases during early ART suggesting being prone to complex interactions between the infectious *M. tuberculosis* and immune recovery (which inclines to result in TB becoming more clinically evident). The dynamics of this interaction may result in TB remaining subclinical, a characteristic clinical presentation, or in inflated inflammatory presentation. Consequences of ART-mediated immune restoration, mainly occurring in the existence of high mycobacterial load: the onset timing of TB symptoms may be considered, there may be faster symptom onset, and it may result in

amplified inflammatory clinical manifestations causing unmasking TB-IRIS.

Epidemiology

As demonstrated in Table 2, the reported incidence of IRIS varies from 3–40% of patients initiated on ART. This variation may be likely due to differences in case definitions, patients' population studied, and individual resource-limited settings [9–11]. In 2010, a meta-analysis was done by Müller *et al.*, in which 13,103 patients were considered for analysis from 54 cohort studies. It was observed that 1,685 patients developed IRIS [12]. *Mycobacterium tuberculosis* is one of the most common opportunistic pathogens to cause TB-associated IRIS [13–15]. Several studies proposed different percentages of IRIS incidents [12]. The first prospective study was performed by Narita *et al.* in 1998, to assess the incidence of paradoxical responses in patients receiving ATT and subsequently initiated on ART. In their study, 33 of HIV/TB co-infected patients undergoing dual therapy (ART and ATT treatment) and 12 (36%) patients developed TB-IRIS [16].

Risk factors associated with HIV-infected patients and the development of tuberculosis-associated immune reconstitution inflammatory syndrome

The existence of opportunistic infection at the time of ART initiation, poses a risk factor for the development of IRIS. Before initiation of ART, disseminated infection such as TB and cryptococcal disease has been shown to be associated with an increased risk for development of IRIS. Several studies reported that CD4+ cell count less than 50 cells/μl and higher HIV plasma viral load before

Table 2. Incidence of tuberculosis-associated immune reconstitution inflammatory syndrome in HIV patients in various case studies

Study investigator/ year	Study design	Year of study	Incidence of TB-IRIS	Median age of patients (year)	Median CD4 at baseline (cells/mm ³)	Median VL at baseline (log ₁₀ /ml)	Median time to IRIS events (days)
Narita <i>et al.</i> , 1998	Prospective	1996-1997	12/33 (36%)	40	51	5.8	15
Wendel <i>et al.</i> , 2001	Observational	1996-1999	3/28 (11%)	37	69	NA	NA
Breton <i>et al.</i> , 2004	Retrospective	1996-2001	16/37 (43%)	35	100	5.3	12
Breen <i>et al.</i> , 2004	Retrospective	1997-2002	14/50 (35%)	36	NA	NA	11
Kumarasamy <i>et al.</i> , 2004	Retrospective	2000-2003	11/144 (8%)	29	123	NA	22
Manosuthi <i>et al.</i> , 2006	Retrospective	2003-2004	21/167 (21%)	36	36	5.63	32
Lawn <i>et al.</i> , 2007	Prospective	2002-2005	19/160 (13%)	35	68	4.84	14
Umphonsathien <i>et al.</i> , 2011	Retrospective	2000-2009	12/184 (6.5%)	40	41	6.5	70
Worodria <i>et al.</i> , 2012	Prospective	2007-2009	53/376 (21%)	35	52	NA	14
Narendran <i>et al.</i> , 2013	Prospective	2009-2011	26/48 (54%)	36	93	5.9	11
Lai <i>et al.</i> , 2015	Prospective	2009-2011	33/63 (52%)	32	82	1.8	13

initiation of ART were considered as greater risk factors for developing IRIS [17-19]. On the other hand, a rapid increase in suboptimal CD4+ cell count at the time of the initial month of ART treatment and early initiation of ART after ATT treatment were associated with TB-associated IRIS [15, 20]. There is modest agreement among the number of studies on other risk factors for IRIS and optimal treatment strategy. Limited data are available on the optimal timing of initiation of ART and associated treatment of OIs. However, some studies showed that the risk factor for developing IRIS increases if ART treatment is initiated close to the time of OI [15, 20]. A study by Price *et al.*, in 2002, proposed that genetic predisposition and certain genes were associated with increased susceptibility to the development of IRIS in the presence of TB and herpes infection [21]. Younger age and male gender were inconsistently associated with IRIS [15, 22], whereas the type of ART regimen and ethnicity did not show to be risk factors for IRIS [10].

Impact of tuberculosis in HIV infection

A TB infection increases HIV replication in infected patients, which is associated with an increase in viral load and results in more rapid progression of HIV disease [23-25].

Mycobacterium tuberculosis is a potent immune activator that leads to a profound revolution in the cytokines and chemokines complex, which further provides an optimal environment for viral replication. It also increases the risk of progression of HIV and conversion into AIDS and increases the occurrence of other OIs [26]. The management of TB and HIV co-infected patients is challenging because of medication burden, increased level of adverse effect, drug-drug interaction, etc. [27].

Impact of HIV on tuberculosis infection

HIV disease is the greatest risk factor for acquiring *M. tuberculosis* infection and developing TB [28]. HIV infection disturbs the cell-mediated immunity through depletion of CD4+ T cells. This imbalance in the immunity leads to an increase in the number of cases of primary TB and reactivation of TB in HIV-infected patients [29]. Initially, in HIV infection, CD4+ lymphocytes are decreasing, but viral load associated with the risk of patient fatality increases. In response, the defense mechanism increases CD8+ lymphocytes and play a key role in reducing HIV viremia. However, the level of CD8+ lymphocyte count also decreases due to a progression of HIV infection. On the other hand, the development of TB during HIV infection is related to severe

immune activation with the simultaneous release of pro-inflammatory cytokines such as interleukins (IL)-1 β , IL-6, and tumor necrosis factor (TNF)- α that promote HIV replication [24, 28, 30] (Figure 2).

Complexity and difficulties among HIV and tuberculosis co-infection

TB/HIV co-infection creates huge changes in the natural phenomenon and pathology of both diseases. Clinical symptoms of HIV and tuberculosis in co-infected patient correspond with each other, causing another obstacle in the right diagnosis of the disease. Features of HIV and TB are difficult to distinguish, since both the diseases present with persistent fever. Diagnostic and treatment of HIV-infected patient who develops TB are complicated. Mechanism regarding the interaction between HIV and TB has been completely elucidated. Thus, the proper timing of ART starting in HIV-TB co-infected patients are particularly important to reduce morbidity and mortality [31, 32]. On the other hand, both the diseases are diagnosed with different diagnostic modalities. In both cases, patients are treated with more than one drug combination, which results in poor drug adherence and increased adverse drug reaction, with corresponding drug toxicity such as drug-induced hepatotoxicity. Additionally, drug-drug interaction and TB-IRIS with HAART contribute to treatment difficulty and patients' poor drug compliance [33].

Immunopathogenesis of immune reconstitution inflammatory syndrome

The immunopathogenesis of IRIS remains unclear. As we look at IRIS, one of the most prominent features is that the clinical appearance depends on the type of underlying infection [34]. IRIS is a result of the impaired regulatory mechanism and immune responses against a variety of antigenic stimuli, and the time of ART initiation is a matter of concern in HIV-TB co-infected patients [13]. It has been suggested that the process is driven by antigenic stimulation, in which a specific immune response and inflammatory response are exaggerated by the production of pro-inflammatory cytokines [35]. Many studies suggested that immune replenishment following ART treatment is characterized by a huge proliferation of memory CD4+ T cell types (CD4+ CD45RO+), which is likely due to peripheral lymphoid re-deployment [36-38]. However, activated naive CD4+ T cells do not recover after several months of ART treatment [39]. Furthermore, IFN- γ and IL-2 concentration increases in IRIS development [40]. Few studies support the abundance of antigen-specific CD4+ T cells, peripheral blood mononuclear cells, and IFN- γ response to *M. tuberculosis* antigens after the initiation of ART, with the primed CD4+ T cells being activated to recognize previous antigenic exposure. This might account for the symptom of IRIS [41, 42], which probably occurs due to the construction of post-ART im-

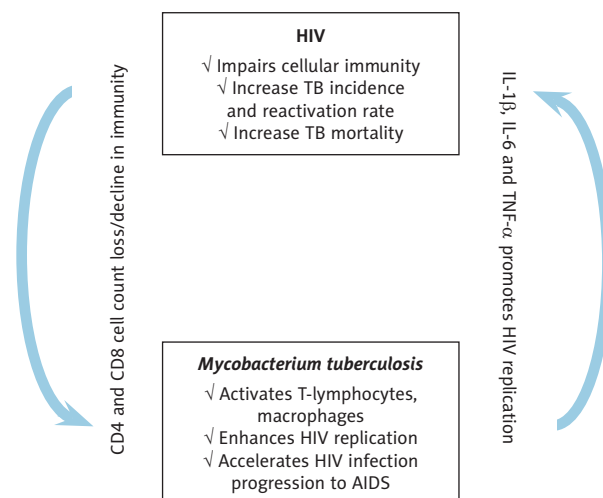


Figure 2. Conceptual diagram to illustrate interactions between human immunodeficiency virus and *Mycobacterium tuberculosis*

immune machinery arising from residual immune cells that have previously encountered the antigen rather than newly produced cells [40] (Figure 1).

Immune suppressive machinery against unfavorable immune responses

There are several known mechanisms produced by the host to regulate immunological damage caused by excessive inflammatory immune responses. T reg cells are supposed to participate in regulating inflammatory responses by mediating key components such as IL-10. It directly or indirectly facilitates the suppression of effector T cell responses. Additionally, T reg cells secrete IL-35 and transforming growth factor (TGF)- β , which induces conventional CD4+ T cells to further differentiate into T reg cells and promote T cell tolerance [43]. The high turnover of FoxP3+ is beneficial, as it may help in limiting the severity of tissue destruction associated with an inflammatory condition due to infection in patients that may not progress to IRIS (Figure 2).

Cell surface molecules such as cytotoxic T lymphocyte-associated protein-4 (CTLA-4) and CD28 are equally important in contributing towards T reg cell-mediated immune suppression. In CD28-CTLA-4 pathway, CD28 is a key molecule, which promotes T cell responses, while CTLA-4 is an essential attenuator of antigenic T cell responses [44]. CTLA-4 suppresses dendritic cell (DC)-mediated T cell stimulation by binding to CD80 and CD86, which leads to lower expression of these co-stimulatory molecules on DC. CD80 molecules are liable to interact with CTLA-4 for maintaining immune tolerance. This inhibitory function is interrupted by the up regulation of CD86 on DC cells, because of inflammatory stimulation against pathogenic stimuli that leads to immune activation [45, 46].

Treatment

There is no standard treatment available for TB-IRIS. Corticosteroids remain the only treatment available [47]. The patients who experiencing limp node, soft tissue or airway TB-IRIS entail extended anti-tuberculosis therapy; however, no optimal time duration is available, as it depends on case definition and individual resource settings. Most of the TB-IRIS patients show clinical improvements within two months of anti-tuberculosis therapy, but the range is wide, from one month to seven months, depending on the severity and site of the disease. Some of the patients had tissue abuses and pleural effusion, which may require aspiration. Many studies reported adjunctive therapy such as corticosteroids and non-steroidal anti-inflammatory drugs used against TB-IRIS.

Conclusion

Even though the exact cause of IRIS occurrence is ambiguous, the possible reason is a wide variation in clinical presentation and symptoms, but etiology and diagnosis remain challenging. Early ART among HIV patients is the leading approach to restore and recover their immune system, and to prevent HIV-associated consequences as well as help in limiting the leukocytes imbalance and dysfunctions. However, lower CD4 count and higher viral load are in some way used as a current risk factors for the development of IRIS in HIV patients. Future studies should focus on investigating prognostic and diagnostic biological markers for the diagnosis of IRIS using advanced technologies and existing current studies on T cells and B cells.

Conflict of interest

The authors declare no conflict of interest with respect to the research, authorship, and/or publication of this article.

References

- Walker NE, Stek C, Wasserman S, Wilkinson RJ, Meintjes G. The tuberculosis-associated immune reconstitution inflammatory syndrome: recent advances in clinical and pathogenesis research. *Curr Opin HIV AIDS* 2018; 13: 512-521.
- Boulware DR, Meya DB, Bergemann TL, et al. Clinical features and serum biomarkers in HIV immune reconstitution inflammatory syndrome after cryptococcal meningitis: A prospective cohort study. *PLoS Med* 2010; 7: 1-14.
- Ravimohan S, Tamuhla N, Steenhoff AP, et al. Therapy: a prospective observational cohort study. *Lancet Infect Dis* 2016; 15: 429-438.
- Wilson EM, Sereti I. Immune restoration after antiretroviral therapy: the pitfalls of hasty or incomplete repairs. *Immunol Rev* 2014; 254: 343-354.
- Lanzafame M, Vento S. Tuberculosis-immune reconstitution inflammatory syndrome. *J Clin Tuberc Other Mycobact Dis* 2016; 3: 6-9.
- French MA, Price P, Stone SF. Immune restoration disease after antiretroviral therapy. *AIDS* 2004; 18: 1615-1627.
- Shelburne SA, Montes M, Hamill RJ. Immune reconstitution inflammatory syndrome: more answers, more questions. *J Antimicrob Chemother* 2006; 57: 167-170.
- Colebunders R, John L, Huyst V, Kambugu A, Scano F, Lynen L. Tuberculosis immune reconstitution inflammatory syndrome in countries with limited resources. *Int J Tuberc Lung Dis* 2006; 10: 946-953.
- Grant PM, Komarow L, Lederman MM, et al. Elevated interleukin 8 and T-helper 1 and T-helper 17 cytokine levels prior to antiretroviral therapy in participants who developed immune reconstitution inflammatory syndrome during actg a5164. *J Infect Dis* 2012; 206: 1715-1723.
- Sharma SK, Soneja M. HIV & immune reconstitution inflammatory syndrome (IRIS). *Indian J Med Res* 2011; 134: 866-877.
- Breton G, Duval X, Estellat C, et al. Determinants of immune reconstitution inflammatory syndrome in HIV type 1-infected patients with tuberculosis after initiation of antiretroviral therapy. *Clin Infect Dis* 2004; 39: 1709-1712.
- Müller M, Wandel S, Colebunders R, Attia S, Furrer H, Egger M. Incidence and lethality of immune reconstitution disease in HIV-infected patients starting antiretroviral therapy: systematic review and meta-analysis. *Lancet Infect Dis* 2010; 10: 251-261.
- Sharma SK, Karmakar S, Vashishtha R, et al. Clinical characteristics of tuberculosis-associated immune reconstitution inflammatory syndrome in North Indian population of HIV/AIDS patients receiving HAART. *Clin Dev Immunol* 2011; 2011: 239021.
- Sharma SK, Dhooria S, Barwad P, Kadiravan T, Ranjan S. A study of TB-associated immune reconstitution inflammatory syndrome using the consensus case-definition. *Indian J Med Res* 2010; 131: 805-808.
- Shelburne SA, Visnegarwala F, Darcourt J, et al. Incidence and risk factors for immune reconstitution inflammatory syndrome during highly active antiretroviral therapy. *AIDS* 2005; 19: 399-406.
- Narita M, Ashkin D, Hollender ES, Pitchenik AE. Paradoxical worsening of tuberculosis following antiretroviral therapy in patients with aids. *Am J Respir Crit Care Med* 1998; 158: 157-161.
- Burman W, Weis S, Vernon A, et al. Frequency, severity and duration of immune reconstitution events in HIV-related tuberculosis. *Int J Tuberc Lung Dis* 2007; 11: 1282-1289.
- Jevtović DJ, Salemović D, Ranin J, Pešić I, Žerjav S, Djurković-Djaković O. The prevalence and risk immune restoration disease in HIV-infected patients treated with highly active antiretroviral therapy. *HIV Med* 2005; 6: 140-143.
- Breen RAM, Smith CJ, Bettinson H, et al. Paradoxical reactions during tuberculosis treatment in patients with and without HIV co-infection. *Thorax* 2004; 59: 704-707.
- Lawn SD, Bekker LG MR. Immune reconstitution disease associated with mycobacterial infections in HIV-infected individuals receiving antiretrovirals. *Lancet Infect Dis* 2005; 5: 361-373.
- Price P, Morahan G, Huang D, et al. Polymorphisms in cytokine genes define subpopulations of HIV-1 patients who experienced immune restoration diseases. *AIDS* 2002; 16: 2043-2047.
- Ratnam I, Chiu C, Kandala NB, Easterbrook PJ. Incidence and risk factors for immune reconstitution inflammatory syndrome in an ethnically diverse HIV type 1-infected cohort. *Clin Infect Dis* 2006; 42: 418-427.
- Bruchfeld J, Correia-Neves M, Käällenius G. Tuberculosis and HIV coinfection. *Cold Spring Harb Perspect Med* 2015; 5: a017871.
- Toossi Z, Johnson JL, Kanost RA, et al. Increased replication of HIV-1 at sites of Mycobacterium tuberculosis infection: potential mechanisms of viral activation. *J Acquir Immune Defic Syndr* 2001; 28: 1-8.
- Goletti D, Weisman D, Jackson RW, et al. Effect of Mycobacterium tuberculosis on HIV Replication. *J Immunol* 1996; 157: 1271-1278.
- Naidoo K, Naidoo K, Padayatchi N, Abdool Karim Q. HIV-associated tuberculosis. *Clin Dev Immunol* 2011; 2011: 585919.
- Padmapriyadarsini C, Narendran G, Swaminathan S. Diagnosis & treatment of tuberculosis in HIV co-infected patients. *Indian J Med Res* 2011; 134: 850-865.
- Kwan C, Ernst JD. HIV and tuberculosis: a deadly human syndrome. *Clin Microbiol Rev* 2011; 24: 351-376.

29. Diedrich CR, Flynn JAL. HIV-1/Mycobacterium tuberculosis co-infection immunology: how does HIV-1 exacerbate tuberculosis? *Infect Immun* 2011; 79: 1407-1417.
30. Andrews CA, Koup RA. The immunopathology of HIV infection. *J Antimicrob Chemother* 1996; 37 Suppl B: 13-25.
31. Kulane A, Ahlberg BM, Berggren I. "It is more than the issue of taking tablets": the interplay between migration policies and TB control in Sweden. *Health Policy (New York)* 2010; 97: 26-31.
32. Pawlowski A, Jansson M, Sköld M, Rottenberg ME, Källenius G. Cornea transplant at Parma between 1983 and 1990. *New Trends Ophthalmol* 1991; 6: 343-347.
33. Arbex MA, Varella M de CL, Mello HR de SFAF de. Antituberculosis drugs: drug interactions, adverse effects, and use in special situations. Part 1: First-line drugs. *J Bras Pneumol* 2010; 36: 626-640.
34. French MA. HIV/AIDS: immune reconstitution inflammatory syndrome: a reappraisal. *Clin Infect Dis* 2009; 48: 101-107.
35. Seddiki N, Sasson SC, Santner-Nanan B, et al. Proliferation of weakly suppressive regulatory CD4+ T cells is associated with overactive CD4+ T-cell responses in HIV-positive patients with mycobacterial immune restoration disease. *Eur J Immunol* 2009; 39: 391-403.
36. Goicoechea M, Smith DM, Liu L, et al. Determinants of CD4+ T cell recovery during suppressive antiretroviral therapy: association of immune activation, T cell maturation markers, and cellular HIV-1 DNA. *J Infect Dis* 2006; 194: 29-37.
37. Bucy RP, Hockett RD, Derdeyn CA, et al. Initial increase in blood CD4(+) lymphocytes after HIV antiretroviral therapy reflects redistribution from lymphoid tissues. *J Clin Invest* 1999; 103: 1391-1398.
38. Autran B, Carcelain G, Li TS, et al. Positive effects of combined antiretroviral therapy on CD4+ T cell homeostasis and function in advanced HIV disease. *Science* 1997; 277: 112-116.
39. Stone JD, Cochran JR, Stern LJ. T-cell activation by soluble MHC oligomers can be described by a two-parameter binding model. *Biophys J* 2001; 81: 2547-2557.
40. Shankar EM, Vignesh R, Velu V, et al. Does CD4+CD25+foxp3+ cell (Treg) and IL-10 profile determine susceptibility to immune reconstitution inflammatory syndrome (IRIS) in HIV disease? *J Inflamm (Lond)* 2008; 5: 2.
41. Swaminathan S, Padmapriyadarsini C, Narendran G, Thomas BE, Anand S, Rajyalakshmi A. Immune reconstitution syndrome following initiation of antiretroviral therapy in a patient with HIV infection and multidrug-resistant tuberculosis. *Indian J Chest Dis Allied Sci* 2005; 47: 299-304.
42. Narendran G, Swaminathan S, Sathish S, Rajasekaran S. Immune reconstitution syndrome in a child with TB and HIV. *Indian J Pediatr* 2006; 73: 627-629.
43. Schmidt A, Oberle N, Krammer PH. Molecular mechanisms of Treg-mediated T cell suppression. *Front Immunol* 2012; 3: 51.
44. Zheng Y, Manzotti CN, Liu M, Burke F, Mead KI, Sansom DM. CD86 and CD80 differentially modulate the suppressive function of human regulatory T cells. *J Immunol* 2004; 172: 2778-2784.
45. Sharpe AH, Freeman GJ. The B7-CD28 superfamily. *Nat Rev Immunol* 2002; 2: 116-126.
46. Sansom DM, Manzotti CN, Zheng Y. What's the difference between CD80 and CD86? *Trends Immunol* 2003; 24: 314-319.
47. Meintjes G, Wilkinson RJ, Morroni C, et al. Randomized placebo-controlled trial of prednisone for paradoxical tuberculosis-associated immune reconstitution inflammatory syndrome. *AIDS* 2010; 24: 2381-2390.