

# EMERGENCY CESAREAN SECTION IN CASE OF ANEURYSM OF THE MUSCULAR INTRAVENTRICULAR SEPTUM WITH NEONATAL FOLLOW-UP - A CASE REPORT AND REVIEW OF THE LITERATURE



**Authors:**

Joanna Płuzańska<sup>1</sup>, Jacek Więcek<sup>6</sup>, Michał Krekora<sup>3</sup>, Jolanta Kietbasicz-Binikowska<sup>1,2</sup>, Tomasz Talar<sup>4</sup>, Maciej Słodki<sup>1,5</sup>, Maria Respondek-Liberska<sup>1</sup>

1. Department of Prenatal Cardiology, Polish Mother's Memorial Hospital Research Institute 2. Department of Cardiology, Polish Mother's Memorial Research Institute 3. Department of Obstetrics and Gynecology, Polish Mother's Memorial Hospital Research Institute 4. Department of Neonatology, Polish Mother's Memorial Hospital Research Institute 5. Institute of Health Sciences, The State School of Higher Professional Education in Plock, Poland

Prenat Cardio 2016 Jan; 6(1):43-49  
DOI: 10.1515/pcard-2016-0006

**Abstract**

We present the case of aneurysm of the muscular intraventricular septum with accompanying cardiomegaly and abnormal venous flow patterns requiring emergency cesarean section and specialized neonatal treatment. At the age of 8 months our patient has no clinical symptoms with a 6 mm scar in intraventricular muscular septum..

**Key words:** cesarean section, fetal echo, aneurysm of the septum, cardiomegaly

**INTRODUCTION**

In the literature regarding fetal cardiology there are several case reports about prenatal detection of aneurysms or diverticulum of the fetal heart at different levels.

Usually they do not influence fetal growth, mainly their nature is benign with the tendency to resolve.

Here we report a special case with dramatic presentation in the third trimester, which thanks to the good cooperation between perinatologists, had a successful outcome.

**CASE REPORT**

A 20 year old prima gravida suffering from bilateral hydronephrosis observed since 20 weeks of gestation, that underwent two DJ shunt implantations, repeatedly treated with antibiotics, was referred and transported by medical transport from Opole to our prenatal cardiology center in Lodz at 35 weeks of gestation due to suspected fetal congenital heart malformation.

The previous US examinations at 8, 16, 20, 24, 28, 30, 31, 33 weeks of gestation were described as normal.

The abdominal US examination of the gravida showed a strongly dilated pelvicalyceal system of the right kidney, duplication of the left kidney pelvicalyceal system with moderate dilatation. The gravida was hospitalized several times, decompressions of the hydronephrosis were conducted twice without effect and at 33 weeks of gestation the gravida refused reimplantation of the DJ shunt and nephrostomy. Oral antibiotics were administered on an out-patient basis.



**How to cite this article:**

Płuzańska J, Więcek J, Krekora M, Kietbasicz-Binikowska J, Talar T, Słodki M, Respondek-Liberska M.  
*Emergency cesarean section in case of aneurysm of the muscular intraventricular septum with neonatal follow-up - a case report and review of the literature.*  
Prenat Cardio 2016; 6(1):43-49

Due to cervical insufficiency at 35 weeks the gravida was admitted for hospitalization in the obstetrical department and upon fetal ultrasound examination significant cardiomegaly, abnormal axis of the heart, and ventricular septal defect were suspected. The gravida was transported from her city to our center (215km) for an urgent consultation.

The ultrasound exam in our unit revealed a single male fetus in cephalic longitudinal position with LGA biometry (34,5hbd by LMP, 38.1 hbd by ultrasound) and Heart area/ Chest area ratio of 0,5. The four chamber view was grossly abnormal showing two asymmetrical atria and two asymmetrical ventricles with no contraction of RV. The foramen ovale was 4 mm, systemic and pulmonary venous return were normal. Abnormal flow through the ductus venosus and pulmonary veins were observed with reversal

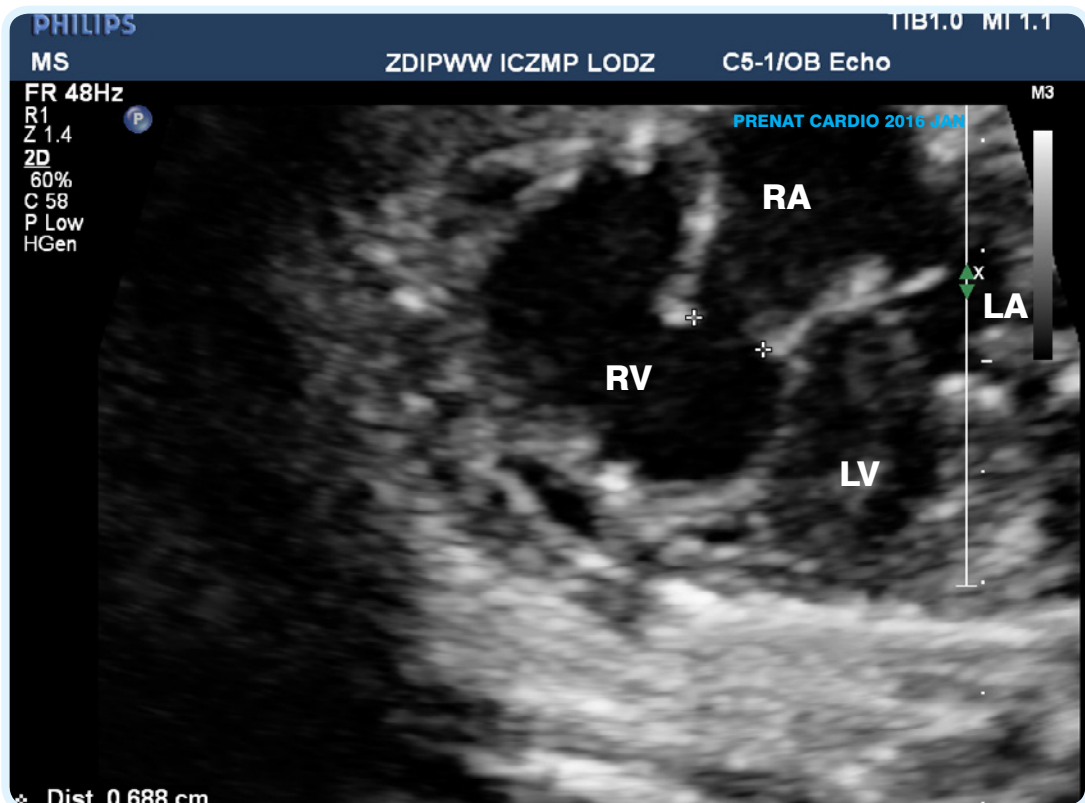
flow  $v=37\text{cm/s}$  suggesting postnatal hemodynamic and respiratory distress. The CVPS was 6 points (minus 2 for heart size, minus 1 for RV function, minus 1 for abnormal DV flow). The initial diagnosis of acute ischemia of the right ventricle and septum was made in differentiation with severe myocarditis. The gravida was referred to the emergency department with an urgent recommendation of delivery by cesarean section, which was performed on the same day.

Male neonate, weighing 3000g received 5/6/8/8 points in the Apgar scale, required assisted mechanical ventilation for 2 days and further nCPAP support for 3 days.

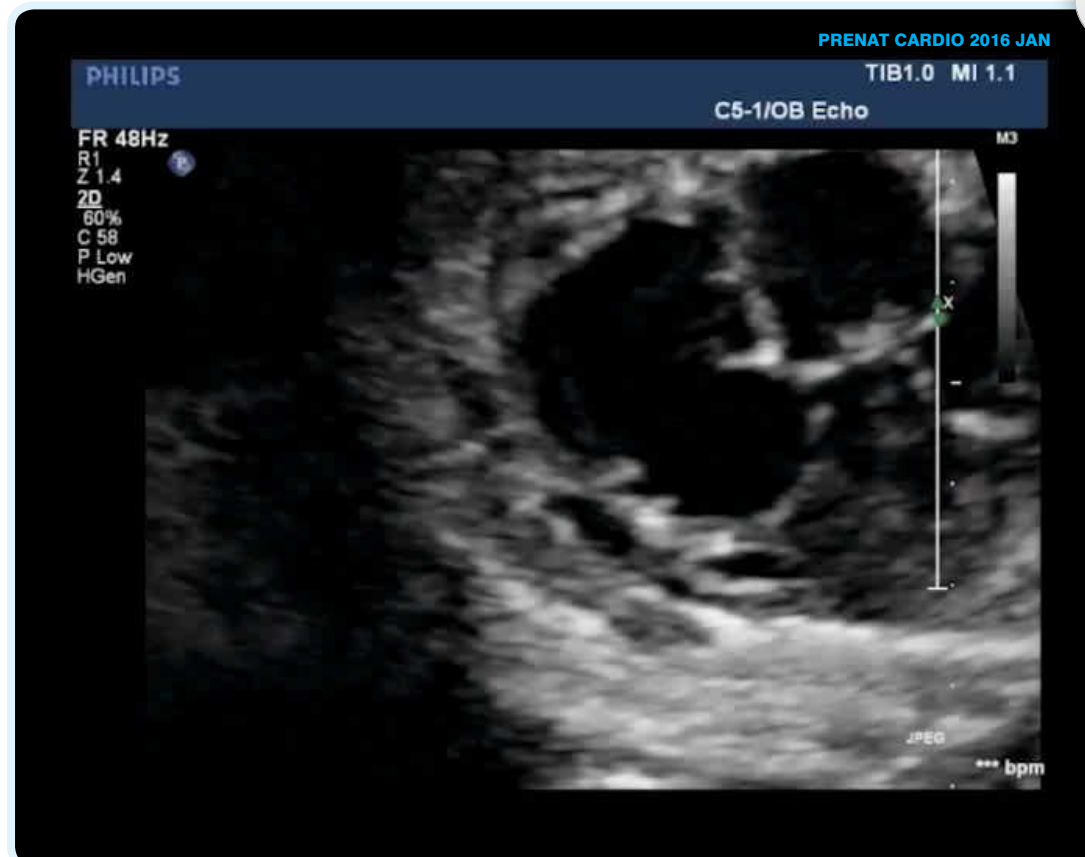
Echocardiography hour after birth confirmed a significant degree of right ventricular dilatation with hypokinesis and abnormal structure and motion of the lower muscular part of the interventricular septum: bulging aneurysmal structure into the right ventricle.

Screening for infection was conducted, and broad-spectrum antibiotics modified by antibiogram were administered, as well as dopamine and Corotopé.

Laboratory studies showed an increase in Troponin T 128,5 (pg/ml), (maximum 597,5pg/ml on 24th day of



Fot 1: Enlarged RV and "squeezed" LV in 4 chamber view



Fot. 6 (cine): Same view  
Play the movie directly in the pdf by clicking on the content

life), NTproBNP=30038 (pg/ml), CK-MB (93 IU/L). During the hospitalization gradual improvement in clinical status was observed along with the normalization of test results. Upon discharge: CK-MB 57IU/L, Troponin T 228,6(pg/ml), NTproBNP 1491 (pg/ml). Echocardiography showed improvement in contractility within the septum and the gradual reduction in the size of the right ventricle improving its function.

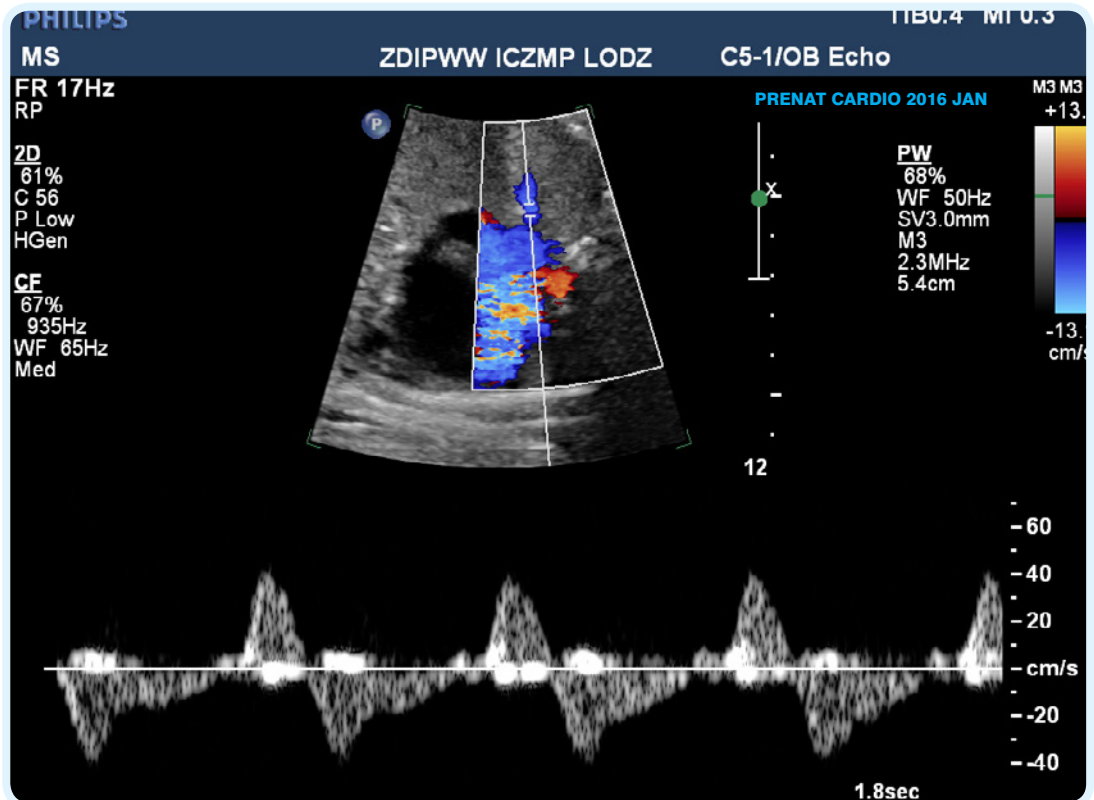
ECG also showed variation from the initial dominant features of large pre-excitation to the dominant rhythm with normal PQ and the image of the right bundle branch block. Holter examination (24-hour ECG) showed 2% of single extrasystoles of atrial origin. The baby boy in good general condition, with no signs of heart insufficiency was discharged home at 3 weeks of postnatal life with a body weight of 3500g, with recommendation of continuation of pharmacological treatment with Enarenal and Acesan. At the age of 8 months baby boy is asymptomatic and on echo has a 6 mm scar at the level of lower part of intermuscular septum (Fig. 5,6)

**DISCUSSION**

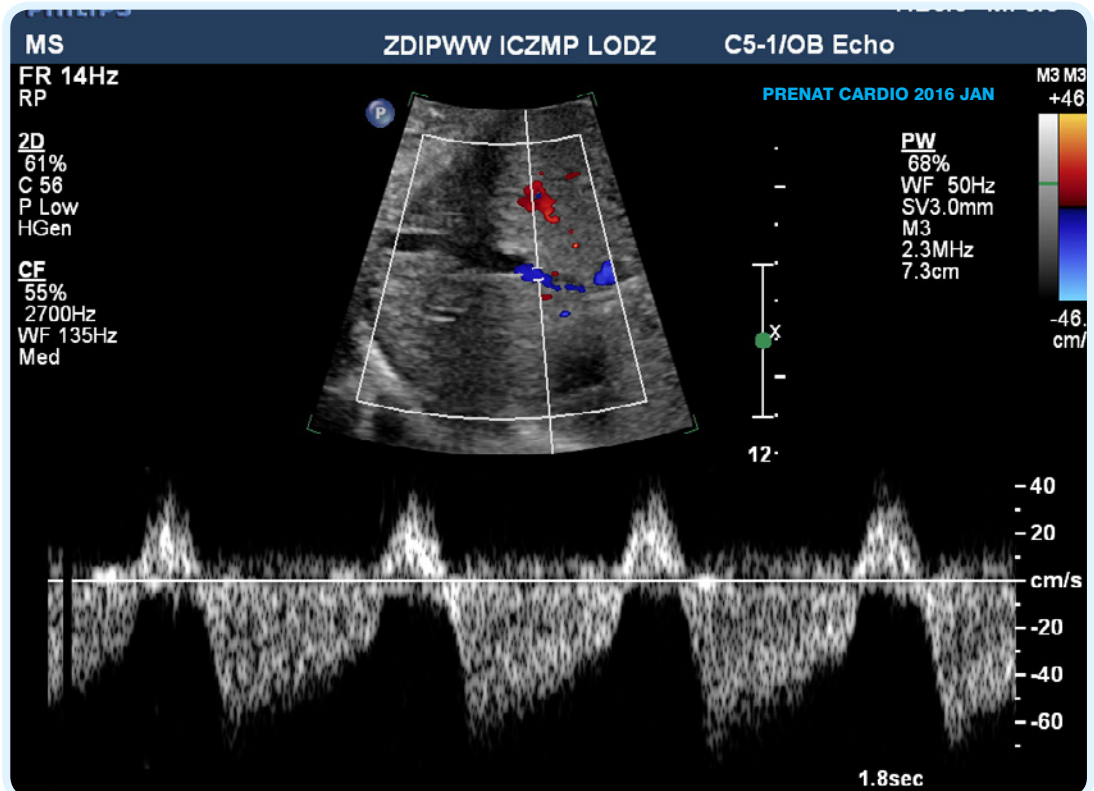
Congenital malformations of the muscular intraventricular septum are rare, however described in prenatal cardiology [1,2,3,4,5,6]. Left and right ventricular outpouchings are also described [7,8].

Aneurysms of the ventricular septum are usually considered to be acquired, a result of infarction,

cardiomyopathy, anomalies of the coronary arteries, Kawasaki disease, sarcoidosis or as complications from cardiac surgery [4,6]. More common are aneurysms of the membranous section of the intraventricular septum and are often associated with ventricular septal defects, with



Fot 3: Reversal flow in pulmonary vein at the level of left atrium



Fot 2: Reversal flow in ductus venosus

Name of author	Year of publication	Prenatal diagnosis	Postnatal diagnosis	Vaginal delivery or CS	Follow-up
Alday 14	1976	No	20th day Aneurysm	Unknown	Cardiac cath 2nd year open heart aneurysmectomy
Chen 3	1991	No	29 year old man and his 4 year old son		Both symptom free
Mohan & Kumar 15	1992	No	18 year old (male)		Asymptomatic
Prabhakar 5	1993	No	1 Year old		Ventricular septal aneurysmectomy performed successfully
Eriksson 2	1998 3 cases	No	One family		Asymptomatic
Fujiwara 4	2001 Case 1	26 wks- VSD	Aneurysm	Vaginal delivery	Asymptomatic
	Case 2	28 wks	Aneurysm	Vaginal delivery	Asymptomatic
Donofrio 10	2002	26 wks	Confirmed	Vaginal delivery at term	Cardiac catheterization on 5th day, digoxin
Baspinar 16	2005	No	5 months - aneurysm	Vaginal delivery at term	Pathological ST changes + WPW + minimal RVOT stenosis + RV hypertrophy No clinical symptoms
Wong 17	2007	No	5 days- aneurysm	Vaginal delivery at term	L & RBBB + abnormality of the short arm of chromosome 20, (46, XX, add (20)(p13) progressing well from a cardiac perspective but has poor muscle tone and developmental delay
Nicolae 18	2007	No	Yes	unknown	Surgical repair
Nguyen A 19	2008	28t wks	Large PDA, moderate biventricular dysfunction Severe thinning of basa to mild ventricular septum resulting in RVOTO & critical tricuspid stenosis with absent pulmonary valve	unknown	Died
Nguyen B	2008	23rd wks Thinning of the entire ventricular septum & Pulmonary atresia + IVS	Severe TV stenosis, hypertrophied RV free wall, multiple RV sinusoids	unknown	BTS, BDG, modified Fontan, resolution of septal aneurysm at 2yr of age, alive at 5 yr

Table 1. Echocardiographic findings and neonatal outcome in analysed population (part 1/)

Nguyen C		Thin ventricular septum aneurysm bulging into LVOT without obstruction and pulmonary atresia with IVS	Hypoplastic TV stenosis, hypertrophied RV free wall, multiple RV sinusoids	unknown	BTS, BDG, modified Fontan, alive at 3yr, bulging aneurysm without LVOTO
Nguyen D	2008	Large ventricular septal aneurysm bulging from the body of RV into the LV causing mild LVOTO and pulmonary atresia with nearly IVS	Severe TV stenosis, additional small VSD, single LCA, multiple RV sinusoids	unknown	BTS, septal plication of aneurysm, BDG, modified Fontan, alive at 5 yr, no LV obstruction
Carr 20	2008	19 wks	Confirmed aneurysm	unknown	Dilated cardiomyopathy requiring heart transplant
Lalit 21	2015		Male 48 years		Incidental findings
Our case	2015 /2016	8, 16, 20, 24, 28, 30, 31, 33 US no abnormalities 35 wks RV akinesis	Aneurysm	URGENT Cesarean Section	Alive & Well, no surgery Echogenic "scar" in lower muscular part of the IVS

Table 1. Echocardiographic findings and neonatal outcome in analysed population (part 2)

reports by echocardiography reaching the year 1969.<sup>[9]</sup>

To our knowledge we report the first case of fetal aneurysm of the muscular interventricular septum, requiring immediate intervention and delivery by caesarian section due to acute cardiomegaly and virtually asystole of right ventricle.

The first prenatal diagnosis of an aneurysm of the muscular IVS was that presented by Fujiwara et al.<sup>[4]</sup> (Table 1) in two brothers diagnosed at 26 and 28 weeks of gestation. In both cases the neonatal condition upon delivery was good and neither brother presented with cardiac or respiratory failure, as opposed to our patient.

Upon literature review it is theoritized that this type of aneurysm may be a result of an embryologic defect of the myocardium.<sup>[1,2,3,4,5]</sup> The first case report suggesting the familial occurrence of muscular aneurysms of IVS was made by Chen et al.<sup>[9]</sup> in the year 1991: in this case both father and son were

diagnosed. Such a theory is supported by another study by Eriksson et al.<sup>[2]</sup> and Donofrio 2002. Eriksson<sup>2</sup> described the familial occurrence of such aneurysms in 2 brothers and their father. These reports seem to support the concept that muscular aneurysms are congenital embryological defects of the myocardium, although the exact inheritance mechanism is yet to be determined. As in the cited cases our patient was also male. According to adult cardiovascular assessment, the grandfather's heart was anatomically normal, father's medical history is not available at the current moment.

It seems that fortunately our patient was referred to our center at the last moment, which resulted in immediate CS due to acute cardiomegaly, grossly impaired RV function and Doppler flow patterns (6 points CVPS)<sup>[11,12]</sup> allowing for intensive, targeted neonatal therapy in the tertiary medical center for the baby (advantage of "in utero" transport of 215km

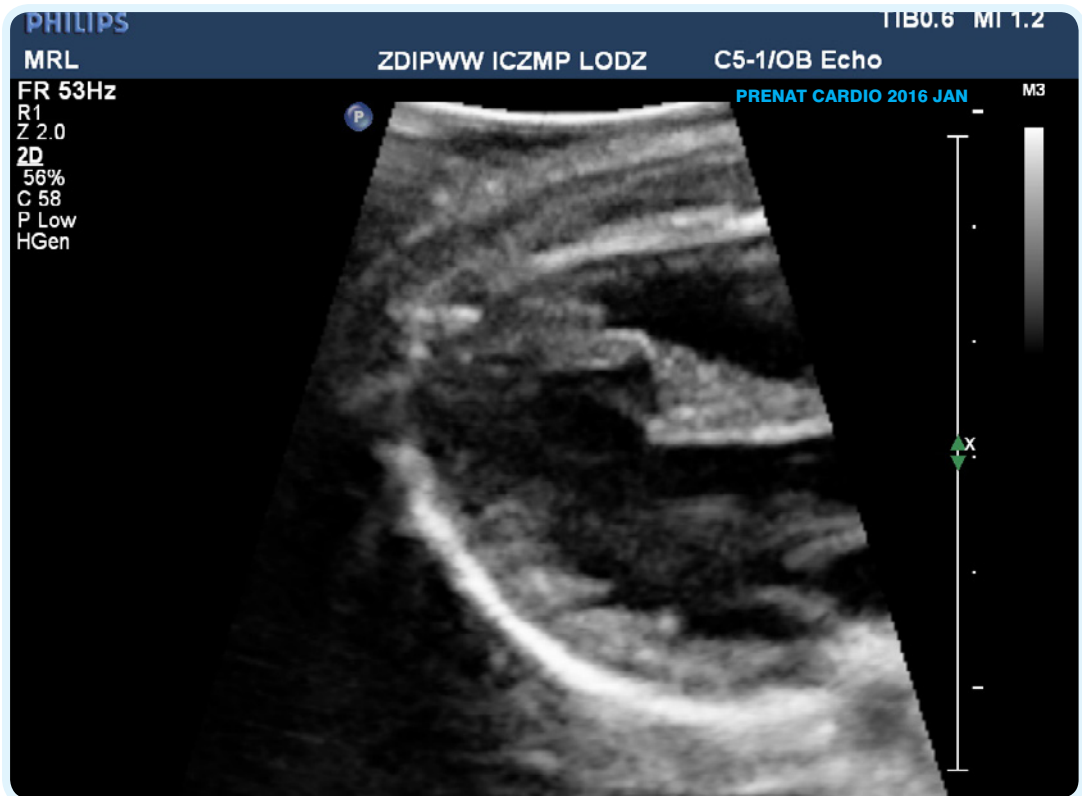
instead of by neonatal ambulance).

In the literature upon prenatal screening the initial diagnosis that was made was that of a ventricular septal defect<sup>[4]</sup> In our case the referring obstetrician also made this false diagnosis. However what was striking in the presented case was fetal heart cardiomegaly with large disproportion of the four chambers in favor of the right side of the heart. Previous cases described good clinical state upon delivery.<sup>[4]</sup> Our patient after birth received a poor Apgar score, initially required nCPAP FiO2 0,35 and was ultimately intubated because of increasing respiratory failure mainly due to cardiomegaly, and not only because of the aneurysm of the septum. As in the cases presented by Eriksson et al.<sup>[2]</sup> our patient also presented with abnormal ECG, which evolved in postnatal life. It is too early to state further prognosis and future impact. The other postnatal finding in the second month of life was of course the abnormal presentation of muscular intraventricular septum-

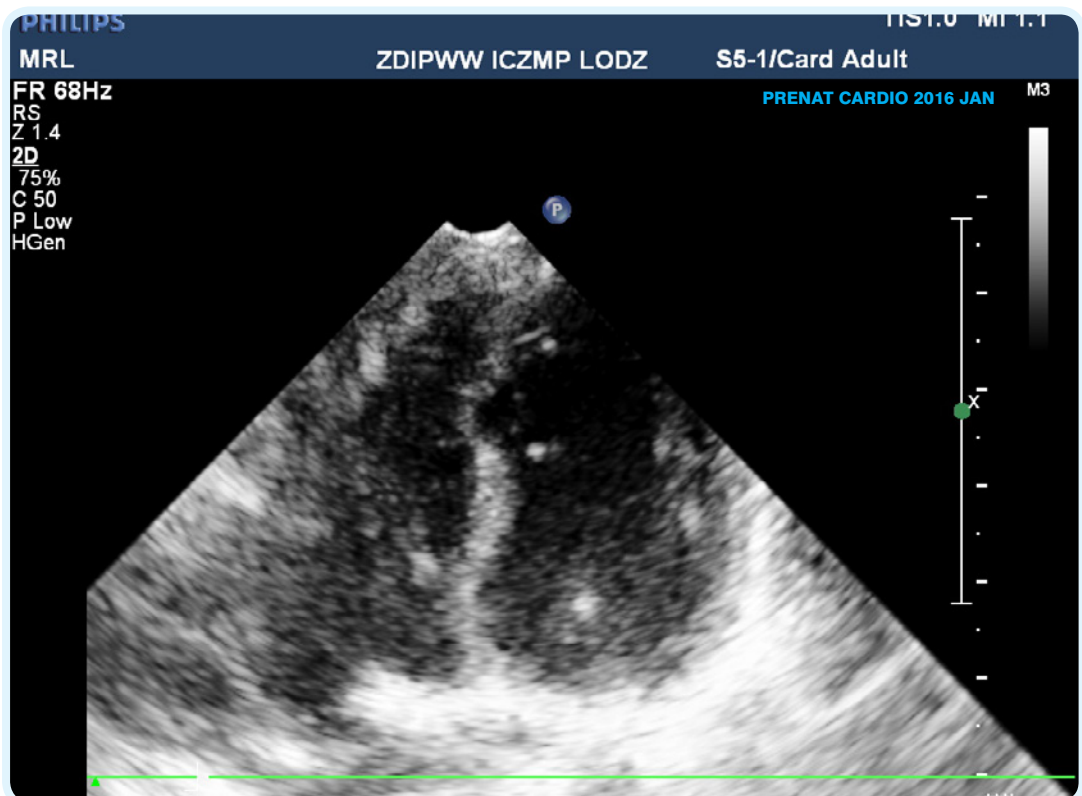
a scar after prenatal ischemic event?

Taking into consideration this case and our previous experience [13], and also the data from literature (table1) which shows that the postnatal course of fetal muscular septum aneurysm could be very different from cases that are asymptomatic for a long time to those resulting in early death, requiring cardiac surgery or heart transplantation,<sup>2,3,4,5,10, 14,15,16,17,18,19,20</sup>

this is further proof that with the current knowledge and ultrasound machines widely available, third trimester fetal echocardiography is justified. The gravida was examined 8 times before the final diagnosis was made, 8 ultrasound examinations were described as normal, the 9th revealed cardiomegaly which was the main cause for targeted echocardiographic examination. Maybe it is worth considering again introducing mandatory third trimester echocardiographic examinations? It is important to remember that this III trimester examination is not only for the late diagnosis of congenital malformations but mainly to assess the hemodynamic status of the fetus and detect acute cardiovascular changes that will require immediate



Fot 4: Myocardial scar at the age of 4 months



Fot 5: Myocardial scar at the age of 8 months (no abnormalities in ECG)

obstetrical intervention and targeted neonatal treatment. Thus "late echocardiography" may allow, like in this case, for transport in utero and optimal management of neonate upon delivery.

## References

1. Prabhakar G, Kumar N, Al-Oufi S, et al. (1993) Congenital aneurysm of the muscular interventricular septum. *Eur Heart J* 14:1294–1296
2. Eriksson H, Cooper SM, Rosenbaum KN, Ruckman RN (1998) Familial occurrence of congenital aneurysm of the muscular interventricular septum. *Pediatr Cardiol* 19:249-252
3. Chen MR, Rigby ML, Redington AN (1991) Familial aneurysms of the interventricular septum. *Br Heart J* 65:104-106
4. Fujiwara M, Sase M, Kondou O, Furukawa S. Congenital aneurysm of the muscular interventricular septum in a fraternal case diagnosed by fetal echocardiography. *Pediatr Cardiol*. 2001;22:353-356. doi:10.1007/s002460010246.
5. Prabhakar G, Kumar N, al-Oufi S, DeMoor M, al-Halees Z, Duran MG. Congenital aneurysm of the muscular interventricular septum. *Eur Heart J*. 1993;14:1294-1296. doi:10.1016/j.echo.2008.01.005.
6. Magherini A, Schmidtlein C, Urciuolo A et al. Congenital aneurysm of the interventricular muscular septum with rupture into the right ventricle in a child. *Am Heart J* 1988; 116:185-7
7. Williams J a., Collardey KR, Treadwell MC, Owens ST. Prenatally diagnosed right ventricular outpouchings: A case series and review of the literature. *Pediatr Cardiol*. 2009;30:840-845. doi:10.1007/s00246-009-9425-2.
8. Rad EM, Awad S, Hijazi ZM. REVIEW ARTICLE Congenital Left Ventricular Outpouchings: A Systematic Review of 839 Cases and Introduction of a Novel Classification after Two Centuries. 2014;(Dclv):498-511.
9. Varghese PJ, Izukawa T, Celermajer J, Simon A, Rowe RD. Aneurysm of the membranous ventricular septum. A method of spontaneous closure of small ventricular septal defect. *Am. J. Cardiol*. 1969; 24: 531–6
10. Donofrio MT1, Allen DR, Tekin M, Bodurtha J. Autosomal dominant myocardial disease diagnosed by fetal presentation of proband with an aneurysm of the muscular interventricular septum. *Pediatr Cardiol*. 2002 Jan-Feb;23(1):27-31. Epub 2002 Feb 19.
11. Huhta James C, Paul James J. „Fetal heart failure , Part. I. *Prenat Cardio* 2011, 2(2),
12. Huhta James C. *Doppler in Fetal Heart Failure Part II. Prenat Cardio* 2012, 1(3),
13. Strzelecka I, Moszura T, Respondek-liberska M. ROUTINE THIRD TRIMESTER FETAL CARDIAC EVALUATION : TIME FOR. 2015;18(3):18-23. doi:10.12847/09154.
14. Alday LE, Moreyra E, Quiroga C, Buonano C, Dander B. Cardiomyopathy complicated by left ventricular aneurysms in children. *Br Heart J*. 1976 Feb;38(2):162-6.
15. Mohan JC, Kumar P Cross-sectional echocardiographic diagnosis of a congenital aneurysm of the muscular interventricular septum *Int J Cardiol*. 1992 Jun;35(3):415-6.
16. Ba pınar O, Karaaslan S, Oran B, Baysal T, Kele S. Congenital aneurysm of the muscular interventricular septum in a child. *Turk J Pediatr*. 2005 Jan-Mar;47(1):82-4.
17. Wong SH, Coleman DM, Aftimos S Congenital aneurysm of the muscular interventricular septum in association with cardiac arrhythmias and a chromosomal abnormality. *Pediatr Cardiol*. 2007 Jan-Feb;28(1):57-60. Epub 2007 Feb 15.
18. Nicolae MI, Summers KM, Radford DJ. Familial muscular ventricular septal defects and aneurysms of the muscular interventricular septum. *Cardiol Young*. 2007 Oct;17(5):523-7. Epub 2007 Jul 18.
19. Nguyen TP, Srivastava S, Ko HH, Lai WW. Congenital muscular ventricular septal aneurysm: report of four cases and review of the literature. *Pediatr Cardiol*. 2008 Jan;29(1):40-4. Epub 2007 Sep 5
20. Carr M, Kearney DL, Eidem BW. Congenital aneurysm of the muscular interventricular septum. *J Am Soc Echocardiogr*. 2008 ;21(11):1282.e1-6.
21. Lalit Garg, Umesh Kumar Mittal, Harmeet Kaur Rissam, and Ashok Sharma Aneurysm of Mid and Apical Interventricular Cardiac Septum Dissecting Along the Basal Part – An Uncommon Entity Diagnosed with CT Angiography *Pol J Radiol*. 2015; 80: 453–456. Published online 2015 Oct 1.

**Division of work:**

**J. Plużańska:** preparing the manuscript , review of the literature, submitting the manuscript

**Co-authors:** work with the manuscript

**Maria Respondek-Liberska:** idea of the article, diagnosis of the case, documentation of the case, correction of the manuscript

**Conflict of interest:** The authors declare no conflict of interest

**Authors do not report any financial or personal links with other persons or organizations, which might affect negatively the content of this publication and/or claim authorship rights to this publication**