

# One, two or three port appendectomy – a rational approach

Andrzej Gołębiewski, Marcin Łosin, Maciej Murawski, Agnieszka Wiejek, Dominika Lubacka, Piotr Czauderna

Department of Surgery and Urology for Children and Adolescents, Medical University of Gdansk, Poland

Videosurgery Miniinv 2013; 8 (3): 226–231

DOI: 10.5114/wiitm.2011.33991

## Abstract

**Introduction:** Laparoscopic appendectomy is a safe and feasible technique accepted by many surgeons as the gold standard approach for the treatment of acute appendicitis in children. Traditionally laparoscopic appendectomy requires the use of three ports. However, surgical techniques with fewer ports have been reported.

**Aim:** To evaluate the efficacy of laparoscopic appendectomy in children according to the proposed 3-step protocol using one, two or three ports.

**Material and methods:** A total of 100 children with the diagnosis of acute appendicitis underwent laparoscopic appendectomy. Patients were treated according to the following protocol: transumbilical access with one 10 mm port using the laparoscope with working channel. The appendix was mobilized and delivered through the umbilical port and tied extracorporeally and removed. If the appendix was placed retroceally or had adhesions, a second port was introduced. The appendix was mobilized and finally retrieved from the abdominal cavity through the camera port, and resected extracorporeally. In the cases of very short and gangrenous appendix and immobile colon, a third port was introduced and totally intra-abdominal appendectomy was performed. Patients were evaluated regarding the duration of the operation, and operative and postoperative complications.

**Results:** During the study period 100 children (58 males, 42 females) had laparoscopic appendectomy: 48 children by one-port technique (group I), 27 children by two-port technique (group II) and 25 children by three-port technique (group III). The mean operative time was 33 min (20–55 min) in group I, 39 min in group II (23–60 min), and 49 min (30–75 min) in group III. There were no intraoperative complications. Wound infections were recorded in 4 (8.3%) patients in group I, three (11.1%) in group II and four (16.0%) in group III. One patient in group III developed an abdominal abscess managed conservatively.

**Conclusions:** One-port laparoscopic appendectomy is a feasible technique in children. It allows 48% of children to have the operation. The addition of a second port allows one to mobilize the appendix and perform extracorporeal resection in an additional 27% of cases. These approaches have shorter operative time compared to 3-port technique. Laparoscopic extracorporeal appendectomy, especially one-port, is found to be cost effective and have excellent cosmetic results.

**Key words:** laparoscopy, appendectomy, one port, transumbilical.

## Introduction

Despite the fact that appendicitis remains the most common emergency surgical condition in children, the treatment of choice is still controversial. Laparoscopic appendectomy, a technique known for

nearly 30 years, has been widely used and nearly universally accepted for the treatment of uncomplicated cases. The indication in complicated appendicitis, the method of appendix division and removal, and the number of used ports are still debatable. The traditional approach to laparoscopic appendectomy, de-

### Address for correspondence:

Andrzej Gołębiewski MD, PhD, Department of Surgery and Urology for Children and Adolescents, Medical University of Gdansk, 1-6 Nowe Ogrody St, 80-803 Gdansk, Poland, phone: +48 58 302 30 31, e-mail: angol@gumed.edu.pl

scribed by Semm in 1983, employs 3 ports [1]. Successful attempts to perform the procedure with fewer ports have been reported. There are reports of several modifications utilizing 2-port techniques, hybrid approaches, single port assisted techniques and recently single incision laparoscopic surgery (SILS) appendectomy [2-5]. The one-trocar appendectomy first proposed by Pelosi and Pelosi in 1992 is one of such modifications [6]. This procedure is performed using only one trocar located paraumbilically using an operative laparoscope. After intra-abdominal mobilization, the appendix is exteriorized through the umbilical port and resected extracorporeally. However, this procedure cannot always be completed using only one trocar due to anatomical and clinical conditions. To solve this problem use of a second or third port is recommended and the procedure can be completed either intra- or extracorporeally.


Despite the chosen technique, the aim of all procedures should be safe surgery and minimal surgical trauma and good cosmesis. To optimize the efficacy of laparoscopic appendectomy in all children admitted with acute appendicitis, regardless of the grade of the disease and anatomy of the appendix, we introduced a unified protocol.

## Aim

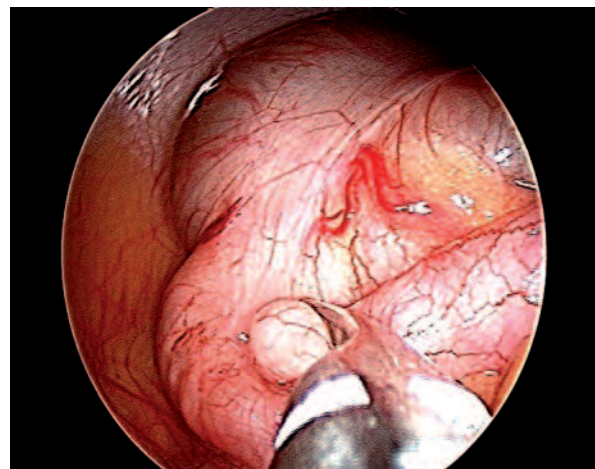
The aim of the study was to report one center's experience in treating acute appendicitis with one, two or three port laparoscopic appendectomy in children according to a 3-step protocol and compare their outcome in terms of operative time, length of hospital stay and surgical site infections.

## Material and methods

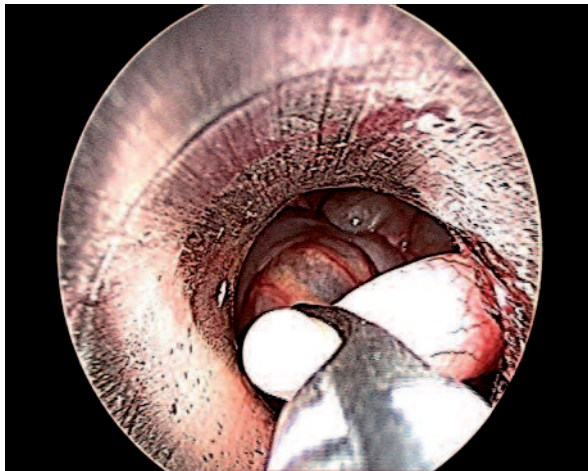
A prospective study was carried out involving 100 consecutive cases of acute appendicitis treated laparoscopically in the period December 2010 – February 2012. The analyzed group consisted of 100 children (58 males, 42 females) aged from 2 to 18 years (mean: 13 years) admitted with symptoms of acute appendicitis. The presenting symptom in each patient was acute abdominal pain in the right lower quadrant. Diagnosis of appendicitis was based on clinical findings (tenderness upon palpation of the abdomen, resistance of right iliac region, fever), laboratory parameters and ultrasonography findings. A total of 100 children, irrespective of grade of disease, were eligible for laparoscopic appendectomy. Patients were treated according to the following unified protocol. Preoperatively all patients were hydrated and given wide-spectrum antibiotics. Patients were placed in the supine position and given general anesthesia with endotracheal intubation and assisted ventilation. Nasogastric tube insertion and bladder catheterization were done routinely. The first 10 mm port was inserted in an open manner (Hasson's technique) on the left of the umbilicus. The procedure was begun in all patients using the 0°, 10-mm laparoscope with a 5-mm working channel (Karl Storz Tuttlingen, Germany) and 450-mm reusable instrument (grasper) (Photo 1). Pneumoperitoneum was achieved, maintaining pressure between 8 mm Hg and 12 mm Hg, according to the patient's weight. After an abdominal examination the appendix and caecum were mobilized (Photo 2), and the appendix was grasped and delivered through the umbilical port



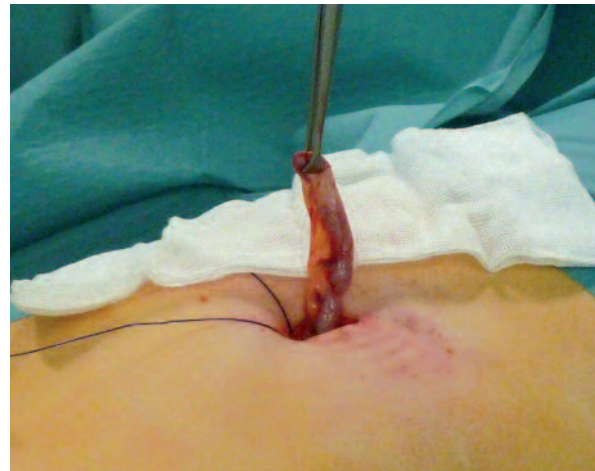**Photo 1.** Laparoscope with a working channel



**Photo 2.** Mobilization of appendix and cecum



**Photo 3.** Delivery of the appendix through the umbilical port



**Photo 4.** Appendix exteriorized through the umbilical access

(Photos 3 and 4). Before the extraction, the insufflation was stopped and the pneumoperitoneum released. After grasping of the cecal base with a Babcock clamp, the mesentery was divided and 2 ligatures were placed on the base of the appendix. The appendix was resected extracorporeally and removed. No purse string suture was tied on the cecum. This technique was called by us TULAEA (transumbilical laparoscopically assisted extracorporeal appendectomy). If the appendix was placed retroceally or adhesions were present, an additional 5 mm trocar was introduced in the midline suprapubic position. The appendix was mobilized and finally retrieved from the abdominal cavity through the camera port, and resected extracorporeally (two-port TULAEA). Subsequently the cecum was reinserted into the abdominal cavity. After reinsufflation the operative field was checked for hemostasis and tightness of ligatures, and the abdominal cavity was washed with normal saline. In the cases of a very short and gangrenous appendix and/or immobile

colon, a third trocar (5 mm) was introduced in the right flank and totally intra-abdominal laparoscopic appendectomy (LA) was performed. The mesoappendix was divided using bipolar cautery. Once the appendix was freed and exposed, two endoloops were used for tying its base. If the lumen of the appendix was too wide to close with a clip, an additional loop was used. After resection the appendix was placed into a cut finger of a sterile glove and removed through the umbilical port. The operative field was checked for hemostasis and the abdominal cavity was washed with normal saline. All patients received postoperative antibiotics. Patients were compared regarding the time of the operation and operative and postoperative complications.

## Results

During the study period 100 children (58 males, 42 females) in the median age of 11 years (range: 3-16 years) had laparoscopic appendectomy. The appendix was easily identified, grasped and exteriorized through the umbilical access in 48 children by one-port technique (TULAEA – group I). An additional trocar was used in 27 children for mobilization and visualization of the appendix and irrigation and suctioning of the pus. The appendix was freed from adhesions, mobilized and resected extracorporeally (two-port TULAEA – group II). For advanced appendicitis or difficult anatomy 25 patients underwent conventional laparoscopic appendectomy (three-port LA – group III). The indications for conversion to the

**Table I.** Histology of resected appendectomy specimens

Histology	Group I	Group II	Group III
Normal	5	2	0
Acute phlegmonous	37	15	5
Gangrenous	6	8	13
Perforated	0	2	7

traditional laparoscopic approach were a complicated inflammatory mass (7 cases), perforated appendicitis with gangrenous changes (10 cases) and immobility of the appendix (8 cases). The mean operative time was 33 min (20-55 min) in group I, 39 min in group II (23-60 min), and 49 min (30-75 min) in group III. There were no intraoperative complications. There was never any tearing of the appendix during its mobilization or extraction. Bowel movements were restored within 24 h of the operation in all patients. Median length of postoperative analgesia was 2 days (range: 1-3 days). Median hospital stay was 3.5 days (range: 3-7 days). The histological findings of the resected appendectomy specimens revealed more advanced inflammatory changes in group III, as detailed in Table I.

There were 12 (12%) postoperative complications. Wound infections were recorded in 4 (8.3%) patients in group I, 3 (11.1%) in group II and in 4 (16.0%) in group III. One patient in group III developed an abdominal abscess managed conservatively. At 3- to 15-month follow-up there were no problems related to the appendectomy.

## Discussion

Several randomized controlled trials and meta-analyses have demonstrated the advantages of laparoscopic appendectomy [7]. It allows for easy and complete exploration of the abdominal cavity, differential diagnosis with other diseases involving the pelvic and right iliac region and easy access to appendices with an anomalous position. The other advantages of laparoscopic appendectomy are: less postoperative pain, reduced incidence of surgical site infections and ileus, shorter hospital stay and better cosmesis compared with open appendectomy. Most of the current techniques use at least three trocars. In order to decrease both costs and the incidence of wound infections, techniques with one or two trocars and laparoscopic-guided appendectomies with micro-laparotomy have been described [3, 5, 8]. The use of LA through a single umbilical incision using a combined intra- and extra-corporeal method was reported as early as 1992 for adults [6] and 1999 for children [9].

This technique as described by Esposito [2] involves identifying and mobilizing the appendix laparoscopically using an operative laparoscope with a working channel through the umbilicus and per-

forming the actual appendectomy extracorporeally. The appendix is mobilized and finally retrieved from the abdominal cavity under vision through the camera port, helped by deflation of the pneumoperitoneum, and the rest of the procedure (control of vessels and tying the base) is done outside the abdomen. The one-trocar TULAEA appendectomy combines the advantages of laparoscopic surgery with those of open surgery. The benefits of this technique include better cosmesis, shorter operation time and reduced costs compared with laparoscopic appendectomy [10]. However, the mobilization and extraction of the appendix is not always possible with one instrument. Great limitations of the procedure remain subserous or strongly adherent appendices that do not allow mobilization with only one instrument. In the cases where the appendix is placed retroceally or has adhesions, a second port is introduced. The appendix is mobilized using two instruments, exteriorized through the umbilicus and the rest of the procedure is done extracorporeally (two-port TULAEA). When the appendix is gangrenous with a friable wall, the risk of laceration is too great to permit excessive tractions used with this technique. Also when the appendix is in a retrocecal position this maneuver cannot be performed. Sometimes, in patients with dense inflammatory adhesions in the right iliac region, immobile colon or with a difficult appendix (completely subserous retrocecal appendix), it may be necessary to add two additional ports, and eventually complete the procedure intra-abdominally (three-port LA).

Single port laparoscopic surgery (SILS) is gaining popularity and several authors have reported the feasibility of appendectomy utilizing this technique [11]. Single port laparoscopic surgery as a single-incision procedure performed within the umbilicus offers better cosmesis. However, single port laparoscopic appendectomy did not offer much advantage over traditional laparoscopic appendectomy (three ports) due to prolonged operative time and high costs of special ports and articulated instruments [12, 13]. In our study the use of one-port technique (one-port TULAEA) was feasible in 48% of cases. The mean operative time was 33 minutes, which is comparable to that reported in a study done by El-Gohary and El-Marsafawy (34.4 min) [14] and by Koontz *et al.* (36 min) [5]. Although Adhikary *et al.* have reported a mean operative time of 23.3 min [15], we were not able to perform the operation so fast. We found a sig-

nificant difference between outcomes of various techniques of appendectomy. Operative time was comparable in one-port and two-port technique, and significantly higher in three-port technique. This is because the operations performed with 3 ports (complicated appendicitis or unfavorable anatomy) were more demanding.

In our study we found a difference in surgical site infections. As reported by Bahar *et al.*, in patients with non-perforated appendicitis the incidence of wound infection is < 10%. The rate of wound infection increases with perforated appendicitis to 15-20% and is highest with diffuse peritonitis (35%) [16]. In our series surgical site infection was significantly lower in one-port and two-port groups as compared to that in the three-port group. In total 11 patients developed surgical site infection. Surgical site infection was 8.3%, 11.1% and 16.0% in one-port, two-port and three-port appendectomy groups respectively. There was one case of intra-abdominal abscess in group 3. The highest rate of surgical site infection and presence of intra-abdominal abscess in group 3 were probably because this group had the highest rate of complicated appendicitis. TULA EA, especially one-port, is found to be cost effective because of shorter operative time and less surgical site infection. For uncomplicated appendicitis the TULA EA technique has been found to be very useful in prospective comparative analysis with three-port appendectomy. One-port appendectomy has been found to be associated with significantly shorter operative time, lower incidence of surgical site infection, less postoperative pain and significantly shorter hospital stay. Extracorporeal appendectomy has also been associated with a shorter learning curve [9, 10]. In our experience the one-trocar TULA EA appendectomy represents a valid alternative to other laparoscopic and open appendectomy techniques in children. It is fundamental to remember that in a number of patients it is necessary to insert one or more additional ports or to perform a conversion to safely perform the procedure. The conversion rate is likely higher in adults than in children because the distance between the cecum and umbilicus is shorter and the abdominal wall is more supple in children [9].

## Conclusions

One-port TULA EA is a safe and effective single-incision approach for early appendicitis that incorpo-

rates both open and laparoscopic techniques to provide excellent exploration of the abdomen, a short hospital stay, minimal pain, and an excellent cosmetic result. The main advantage of this technique is the reduced trauma due to a single large orifice for the laparoscope. In our experience, one-port appendectomy represents a valid alternative to other laparoscopic and open appendectomy techniques in children. Cases of advanced appendicitis may require an additional trocar or "conversion" to conventional laparoscopic techniques to safely perform the appendectomy. The surgeon's experience remains the most relevant factor in safely accomplishing this procedure. One-port laparoscopic appendectomy (TULA EA) is a feasible technique in children. It allows 48% of children to have the operation. The addition of a second port allows one to mobilize the appendix and perform extracorporeal resection in an additional 27% of cases. In total TULA EA technique was feasible in 75% of children. These approaches have shorter operative duration compared to 3-port technique. Laparoscopic extracorporeal appendectomy, especially one-port, is found to be cost effective and have excellent cosmetic results.

## References

1. Semm K. Endoscopic appendectomy. *Endoscopy* 1983; 15: 59-64.
2. Esposito C. One-trocar appendectomy in pediatric surgery. *Surg Endosc* 1998; 12: 177-8.
3. Ates O, Hakguder G, Olguner M, Akgur FM. Single-port laparoscopic appendectomy conducted intracorporeally with the aid of a transabdominal sling suture. *J Pediatr Surg* 2007; 42: 1071-4.
4. Tekin A, Kurtoglu HC. Video-assisted extracorporeal appendectomy. *J Laparoendosc Adv Surg Tech* 2002; 12: 57-60.
5. Koontz CS, Smith LA, Burkholder HC, et al. Video-assisted transumbilical appendectomy in children. *J Pediatr Surg* 2006; 41: 710-2.
6. Pelosi MA, Pelosi MA III. Laparoscopic appendectomy using a single umbilical puncture (minilaparoscopy). *J Reprod Med* 1992; 37: 588-94.
7. Aziz O, Athanasiou T, Tekkis PP, et al. Laparoscopic versus open appendectomy in children: a meta-analysis. *Ann Surg* 2006; 243: 17-27.
8. Yagnik VD, Rathod JB, Phatak AG. A Retrospective study of two-port appendectomy and its comparison with open appendectomy and three-port appendectomy. *Saudi J Gastroenterol* 2010; 16: 268-71.
9. Valla J, Ordorica-Flores RM, Steyaert H, et al. Umbilical one-puncture laparoscopic-assisted appendectomy in children. *Surg Endosc* 1999; 13: 83-5.
10. Visnjic S. Transumbilical laparoscopically assisted appendectomy in children. High-tech low-budget surgery. *Surg Endosc* 2008; 22: 1667-71.

11. Oltmann SC, Garcia NM, Ventura B, et al. Single-incision laparoscopic surgery: feasibility for pediatric appendectomies. *J Pediatr Surg* 2010; 45: 1208-12.
12. Vettoretto N, Mandalà V. Single port laparoscopic appendectomy: are we pursuing real advantages? *World J Emerg Surg* 2011; 6: 25.
13. Bryks-Laszkowska A, Gołębiewski A, Czauderna P. Laparoscopic single port surgery nephrectomy in a child – initial experience. *Videosurgery Miniinv* 2012; 7: 304-6.
14. El-Gohary MA, El-Marsafawy M. Port-exteriorization appendectomy (PEA): a preliminary report. *Pediatr Surg Int* 2001; 17: 39-41.
15. Adhikary S, Tyagi S, Sapkota G, et al. Port exteriorization appendectomy: is it the future? *Nepal Med Coll J* 2008; 10: 30-4.
16. Bahar MM, Jangjoo A, Amouzeshi A, Kavianifar K. Wound infection incidence in patients with simple and gangrenous or perforated appendicitis. *Arch Iranian Med* 2010; 1: 13-6.

**Received:** 1.12.2012, **accepted:** 2.02.2013.