

INCREASED INTERLEUKIN 6 AND TUMOUR NECROSIS FACTOR α EXPRESSION IN THE INFRAPATELLAR FAT PAD OF THE KNEE JOINT WITH THE ANTERIOR KNEE PAIN SYNDROME: A PRELIMINARY REPORT

DARIUSZ WITOŃSKI¹, MAŁGORZATA WĄGROWSKA-DANILEWICZ², RAFAŁ KĘSKA¹,
GRAŻYNA RACZYŃSKA-WITOŃSKA³, OLGA STASIKOWSKA-KANICKA²

¹Department of Reconstructive Surgery and Arthroscopy of the Knee, Medical University of Łódź

²Department of Nephropathology, Medical University of Łódź

³Chair of Biology and Medical Genetics, Medical University of Łódź

The pathway of pain in the anterior knee pain syndrome remains unclear. It has been hypothesized that some biochemical mediators of inflammation, such as cytokines contribute to the process. The objective of this work was to evaluate the synovial membrane and the infrapatellar fat pad expression of the inflammatory mediators and potentially chondrodestructive cytokines interleukin 6 (IL-6) and tumour necrosis factor α (TNF- α) in the anterior knee pain syndrome, and to determine whether the cytokine expression counterpart with/corresponds to the amount of chondral damage in this syndrome. Ten consecutive patients with the anterior knee pain syndrome (group I) participated in the study. Patients with a history of trauma were excluded from this group. For comparison we used 10 patients with anterior cruciate ligament rupture or meniscal lesion with no history of pain in the anterior compartment (group II). Immunohistochemical techniques using a polyclonal rabbit anti-human antibody to IL-6 and a monoclonal mouse anti-human antibody to TNF- α were employed. The results show a statistically significant higher expression of IL-6 in infrapatellar fat pad ($p < 0.05$) as well as TNF- α in the infrapatellar fat pad and the synovium ($p < 0.03$, and $p < 0.02$, respectively) in group I as compared to control subjects. There is no any difference in the amount of chondral damage present in group I as compared to group II. The results of this study provide the immunohistochemical evidence suggesting that the anterior knee pain syndrome could be characterized by infrapatellar fat pad and synovial inflammation variations without the articular cartilage loss.

Key words: knee joint, human, anterior knee pain syndrome, interleukin 6, tumour necrosis factor α .

Introduction

The anterior knee pain syndrome is characterized by chronic pain in the anterior compartment of the knee. The syndrome occurs in adolescents, and is much more common among girls [1-4]. Although the pathway of pain mechanisms continues to be

intensively studied, the source of pain is unclear. At the present stage of knowledge it is difficult to attribute pathophysiology of pain in the anterior knee pain syndrome to any specific anatomic structures or biomechanical disturbances of patellofemoral joint [5]. The mechanical, neural and chemical pathways of pain mechanisms have been advocated [6, 7]. Some authors

reported degenerative neuropathy at the lateral retinaculum, a higher prevalence of substance P immunoreactive nerve fibres in the lateral retinaculum or in the medial retinaculum and the infrapatellar fat pad in anterior knee pain syndrome knees [8-10].

The biochemical mediators of inflammation and the inflammatory response are the lineage of any pain. Throughout this process nerve endings release inflammatory peptide proteins such as substance-P (SP) and calcitonine gene-related peptide (CGRP), which with other forceful inflammatory mediator captivate cells like monocytes and macrophages, will release puissant inflammatory mediators – cytokines. The role of cytokines, such as tumour necrosis factor α (TNF- α) and interleukin 1 β (IL-1 β), on cartilage damage has been well recorded [11-13]. Interleukin 1 and TNF- α seem to tend directly to tissue damage through induction of the release of tissue-damaging enzymes from synovial cell and articular chondrocytes [14]. In addition to IL-1 and TNF- α , other cytokines, like IL-6 have been arranged in the mechanisms of synovial proliferation and joint destruction [15, 16]. However, the role of cytokines in the anterior knee pain syndrome has not yet been defined.

This study was conducted to explore the expression of the main inflammatory mediators and potentially chondrodestructive cytokines IL-6 and TNF- α in the anterior knee pain syndrome knee, and to determine whether the cytokine expression correlated with the aggregate of chondral damage in this syndrome.

Material and methods

The synovium and the infrapatellar fat pad of two groups of patients were evaluated in this study. The material for the investigation was obtained during arthroscopic procedures or the arthroscopic anterior cruciate ligament (ACL) reconstruction. All patients underwent complete clinical examination of the lower extremity and routine examination of the knee as well as the patellofemoral joint. All patients were informed about the research study and agreed to participate in the investigation. The Institutional Review Board Approval was obtained before beginning the study.

The anterior knee pain syndrome group (group I) consisted of 10 patients (6 females, 4 males). The mean age at arthroscopy was 18.9 years. All patients complained about persistent pain in the anterior part of the knee during squatting, prolonged sitting with the flexed knee or descending stairs, with tenderness mainly on the medial patellofemoral joint line. Retropatellar crepitation was found in four knees. Patients with a history of trauma were excluded from this group. For comparison, we used a group of 10 patients (5 males, 5 females) operated on because of meniscal lesion or

ACL rupture with no history of anterior knee pain. The mean age at arthroscopy was 25.2 years.

Light microscopy

Tissue samples from the synovial membrane and the infrapatellar fat pad were fixed in 10% buffered formalin for 24 h, and then dehydrated in graded ethyl alcohols, cleared in xylene, and embedded in paraffin. Afterwards, tissue specimens were cut into 4 μ m thick sections, stained with haematoxylin & eosin and examined upon a Olympus BX40 microscopy.

Immunohistochemistry

Paraffin-embedded tissue sections were mounted onto SuperFrost slides, deparaffinized, then treated in a microwave oven in a solution of TRS (Target Retrieval Solution, pH 6.0, DakoCytomation, Denmark) for 30 minutes (2 \times 6 min 360 W, 2 \times 5 min 180 W, 2 \times 4 min 90 W), and transferred to distilled water. Endogenous peroxidase activity was blocked by 0.3% hydrogen peroxide in distilled water for 30 min, and then sections were rinsed with Tris-Buffered Saline (TBS, DakoCytomation, Denmark) and incubated overnight in a moist chamber in 4°C with the following antibodies: polyclonal rabbit anti-human antibody to IL-6 (Abcam, Inc, Cambridge, UK; dilution 1 : 200), and monoclonal mouse anti-human antibody to TNF- α (Abcam Inc, Cambridge, UK; dilution 1 : 300). Immunoreactivity was visualized using a EnVision-horseradish peroxidase kit (Dako, Carpinteria, CA, USA) according to the instructions of the manufacturer. Visualization was performed by incubating the sections in a solution of 3,3'-diaminobenzidine (DakoCytomation, Denmark). After washing, the sections were counterstained with haematoxylin and coverslipped. For each antibody and for each sample a negative control was processed. Negative controls were carried out by incubation in the absence of the primary antibody and always yielded negative results.

Morphometry

Histological morphometry was performed by means of the image analysis system consisting of a PC computer equipped with a Pentagram graphical tablet, Indeo Fast card (frame grabber, true-colour, real-time), produced by Indeo (Taiwan), and colour TV camera Panasonic (Japan) linked to a Carl Zeiss microscope (Germany). This system was programmed (MultiScan 8.08 software, produced by Computer Scanning Systems, Poland) to calculate the number of objects (semiautomatic function). The coloured microscopic images were saved serially in the memory of a computer, and then quantitative examinations were carried out. Interleukin 6 and

TNF- α positive cells were determined by counting them (semiautomatic function) in a sequence of ten consecutive computer images of $400 \times$ high power fields – 0.0187 mm^2 each. The results were expressed as a mean number of IL-6 and TNF- α immunopositive cells per high power monitor field.

Statistical methods

All values were expressed as the mean \pm SD (standard deviation). The differences between groups were tested using the Student t-test for independent samples preceded by the evaluation of normality and homogeneity of variances with the Levene's test. Results were considered statistically significant at $p < 0.05$ (Table I).

Results

The arthroscopic findings in group I included softening of the articular cartilage of the medial facet of the patella in 8 knees. Localized fibrillation of the central ridge and the medial facet was found in two knees. These changes were classified as International Cartilage Repair Society (ICRS) 1a [17]. In 6 knees of group II, besides the ACL rupture or meniscal lesion, we found fissuring or fragmentation of the patellar surface, classified as ICRS 1b.

Synovial membrane tissue sections

The synovial membrane in patients of group I was composed of 2-3 layers of synovial lining cells. Beneath them the loose connective tissue with capillaries was seen. In one tissue sample in this group, the

congestion related to blood vessel vasodilatation was noted. Lymphocytes and monocytes/macrophages were found in the perivascular locations. A few lymphocytes and macrophages infiltrated the synovial lining cells.

The microscopic examination of tissue samples obtained from patients of group II revealed the loose connective tissue covered by cuboidal cells. The number of synovial lining cells was up to two cell layers. A few scattered lymphocytes were seen within the connective tissue, often localized near capillaries.

Infrapatellar fat pad sections

In 5 patients of group I focal oedema of the adipose and connective tissue in infrapatellar pad fat was seen. In addition, in these patients the microscopic evaluation showed lymphocytes and monocytes/macrophages scattered among the adipose tissue.

The microscopic examination of tissue sections obtained from patients of group II revealed the adipose and loose connective tissue containing the blood vessels. In one tissue sample in this group, focal haemorrhages surrounded by monocytes/macrophages were found.

Immunohistochemistry

The cells showing cytoplasmic immunopositivity to IL-6 and TNF- α were found within the synovial layer, loose connective tissue and adipose tissue. The morphologic picture of these cells resembles inflammatory infiltrating cells, fibroblasts and synoviocytes. Interleukin 6-immunopositive cells and TNF- α -immunopositive cells were found quite often in the synovial lining layer, as well as in the connective and adipose tissue. These

Table I. Mean value from ten consecutive visual areas showing the IL-6 and TNF- α expression in slices excised from the infrapatellar fat pad (H) and the synovium (S) of patients in group I-II

VALID NUMBER	IL-6				TNF- α			
	H I	H II	S I	S II	H I	H II	S I	S II
1	1.2	0.9	6.3	7.2	1.4	0.7	6.4	4.7
2	0.8	0.0	3.8	3.6	0.9	0.0	3.9	3.4
3	0.8	1.1	5.1	6.2	1.1	0.9	5.8	2.7
4	1.1	0.3	2.9	2.0	1.2	0.2	7.1	1.3
5	0.9	0.4	4.7	4.3	0.3	0.0	3.2	5.1
6	0.7	0.0	8.1	1.7	0.8	0.0	6.6	1.1
7	0.7	0.8	2.5	2.5	0.5	0.7	1.8	1.6
8	0.2	0.6	5.5	6.8	0.2	0.4	2.7	3.5
9	1.2	0.3	4.3	1.4	0.9	0.5	3.9	2.7
10	0.3	0.0	5.8	1.3	1.2	0.8	5.5	1.9
$\bar{x} \pm \text{SD}$	0.79 ± 0.34	0.44 ± 0.39	4.90 ± 1.65	3.70 ± 2.3	0.85 ± 0.40	0.42 ± 0.35	4.68 ± 1.82	2.80 ± 1.36

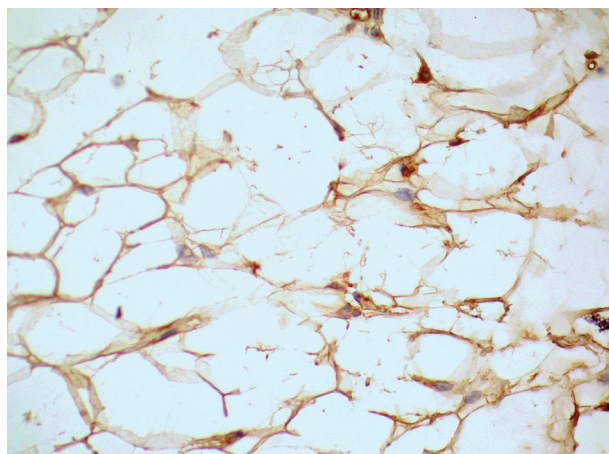


Fig. 1. Immunopositive IL-6 cells scattered in the infrapatellar fat pad section in a patient with the anterior knee pain syndrome (group I). Magnification 400×

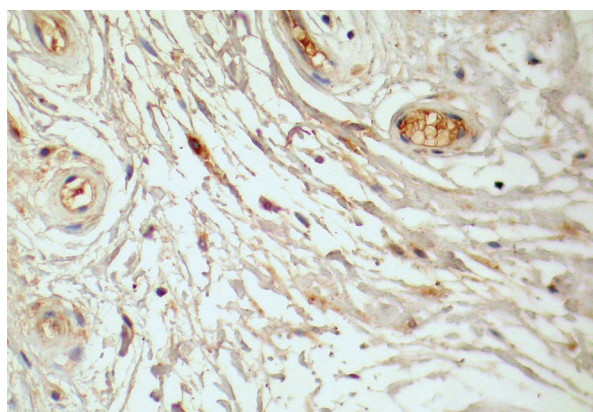


Fig. 2. Immunohistochemical staining to IL-6 in the synovium in a patient with the anterior knee pain syndrome (group I). Interleukin 6 immunopositivity is noted in the proximity to endothelial cells. Magnification 400×

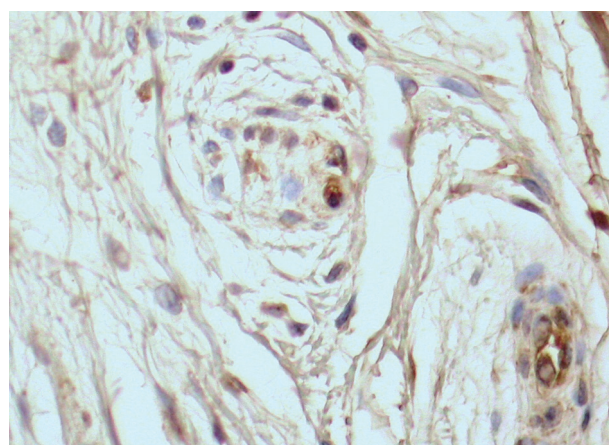


Fig. 3. Tumor necrosis factor α expressing cells in perivascular areas in the close proximity to the endothelium in the synovial tissue section in a patient with the anterior knee pain syndrome (group I). Magnification 400×

cytokine-expressing cells were scattered within the connective and adipose tissues (Fig. 1), or tended to occur in small clusters. Immunopositive cells were often found in perivascular locations (Fig. 2, 3).

Interleukin 6

In patients with the anterior knee pain syndrome (group I), IL-6-positive cells were found in all sections of the synovium and the infrapatellar fat pad. In all patients with meniscal lesion or ACL rupture (group II), IL-6 positive cells were seen in the synovial tissue sections (mean value: 3.7 ± 2.3). The fat pad sections did not manage to show IL-6 positivity in 2 patients in this group; however the mean value of IL-6 positive cells was 0.44 ± 0.39 . The mean number of IL-6-positive cells in the synovial membrane sections in patients with the anterior knee pain syndrome did not differ in comparison to patients of group II ($p = 0.19$), while the mean number of IL-6-positive cells in the infrapatellar fat pad was significantly higher ($p < 0.05$).

Tumor necrosis factor α

In all patients of group II, TNF- α positive cells were found in the synovial tissue (mean value: 2.8 ± 1.36). The immunostaining of TNF- α in the fat pad tissue was negative in one patient. The mean value of TNF- α immunopositivity fat pad sections was 0.42 ± 0.35 . In patients of group I, TNF- α -expressing cells were found in all synovial sections and fat pad sections. Statistical analysis showed that TNF- α immunopositivity in synovial membranes and fat pads was significantly higher in this group in comparison to patients with meniscal lesions or ACL rupture (group II) ($p < 0.02$, and $p < 0.03$, respectively).

Discussion

The results presented here show a statistically significant higher expression of IL-6 in infrapatellar fat pad as well as TNF- α in the infrapatellar fat pad and the synovium in anterior knee pain syndrome knees as compared to control subjects. We are not able to formulate any conclusion relating to the correlation of cytokine expression with the amount of chondral damage present in anterior knee pain syndrome knees (ICRS 1a) bracketed to control subjects (ICRS 1b). Previous studies suggested that the infrapatellar fat pad had been implicated in the development of anterior knee pain syndrome [9, 18-21]. The study conducted by Ushiyama *et al.* revealed that although synovial cells and articular chondrocytes were considered to be primary sources of cytokines like TNF- α and IL-6 found in knee synovial fluids, they may also originate from the infrapatellar fat pad [22]. Besides, the wide range of pain

intensity in anterior knee pain syndrome knee, with a poor correlation to the degree of patellofemoral malalignment, has turned attention to psychological aspects, which restrain the pain sensation. Studies conducted on these patients suggested significantly greater depression, hostility and passive attitude as compared to the reference data [23, 24]. Brummett *et al.* found that the depressive symptoms and gender interaction were predictors of CRP and IL-6 response, and concluded that depression seemed to be related to inflammation more strongly among hostile individuals and among women than among men [25].

The pain may occur although the patient has never displayed any desired signs of tissue damage, like for example fibromyalgia and doubtlessly cases of low back pain. Usually, this pain is called “neuropathic” or “psychogenic”, as opposed to “nociceptive” where physical reasons are present [26]. Our previous studies indicated that in cases of the anterior knee pain syndrome, the presence of nerve fibres immunoreactive for substance P was statistically significant in the medial retinaculum ($p < 0.005$) and in the infrapatellar fat pad ($p < 0.001$) as compared to control, which could explain an increased immunohistochemical expression of inflammatory mediators such as IL-6 and TNF- α in the infrapatellar fat pad in anterior knee pain syndrome patients in the present study [9]. Substance P and the compounded increased production of TNF- α have been shown to be crucially comprehended in the pathogenesis of neuropathic pain modes. Inhibition of macrophage recruitment to the nerve injury site, or pharmacologic interference with TNF- α production has been shown to reduce both the neuropathologic and behavioural manifestations of the neuropathic pain posture [27].

This is the first biopsy studies using immunohistochemical staining techniques analyzing expression of inflammatory mediators in the infrapatellar fat pad and the synovium in anterior knee pain syndrome patients. Bazzichi *et al.* studying the correlation of cytokine (IL-1, IL-6, IL-8, IL-10, TNF- α) levels with the patients’ clinical and psychiatric profile found higher levels of IL-10, IL-8 and TNF- α in fibromyalgia patients than in controls with significant correlations between the biochemical parameters and clinical data [28]. Salemi *et al.* showed immunoreactivity for IL-1 β , IL-6 and TNF- α in skin tissues of fibromyalgia patients, suggesting an inflammatory constituent in the induction of pain [29]. Liptan hypothesized that inflammation of the fascia was the source of peripheral nociceptive input that leads to central sensitization in fibromyalgia. The major cell of the fascia, the fibroblast, has been shown to secrete pro-inflammatory cytokines, particularly IL-6, in response to strain. Biopsy studies

using immunohistochemical staining techniques have found increased levels of collagen and inflammatory mediators in the connective tissue surrounding the muscle cells in fibromyalgia patients [30]. Wang *et al.* studied the role of TNF- α in patients with chronic low back and found a significantly higher proportion of TNF- α positive participants in the patients group than in the control group [31].

Previous studies suggested that anterior knee pain syndrome was a psychosomatic syndrome associated with subclinical patellar instability often due to imbalance of the rectus femoris and vastus medialis, with pain originating in the fat pad and the medial retinaculum [4]. Therefore, the results of the present study encouraged us to speculate that the anterior knee pain syndrome may be caused by biomechanical and psychological factors with inflammation alterations. The syndrome is characterized by the infrapatellar fat pad and synovial inflammation without articular cartilage confusion. Change in inflammation could counterpart with/correspond to pain in the anterior knee pain syndrome, but not loss of cartilage. Treatment of pain in the anterior knee pain syndrome needs to consider, besides biomechanical aspects, the treatment of the infrapatellar fat pad and synovium inflammation. We could hypothesize that the inflammation of the infrapatellar fat pad may counterfeit functional healing response to biomechanical factors, which explained only limited evidence for the effectiveness of NSAIDs for short term pain reduction in the anterior knee pain syndrome [32].

In conclusion, this study revealed that chronic inflammation with production of proinflammatory cytokines, like TNF- α , IL-6, is a feature of the infrapatellar fat pad from patients with the anterior knee pain syndrome. This low stage inflammation results in the production of cytokines that may tend to the pathway of pain in anterior knee pain syndrome knees. However, the pathophysiology of this proceeding, the clinical applicability of TNF- α and IL-6 and, particularly, its apportionment in a potential pain pathway in these patients need to be more intently scrutinized and assigned in further surveys.

Acknowledgements

This study was supported by the Medical University of Łódź, grant # 502–18–672.

References

1. Lichota DK. Anterior knee pain: symptom or syndrome? *Curr Womens Health Rep* 2003; 3: 81-86.
2. Mann G, Constantini N, Hetsroni I, *et al.* Anterior knee-pain syndrome. *Adolesc Med State Art Rev* 2007; 18: 192-220.
3. Sanchis-Alfonso V, Rosello-Sastre E, Martinez-Sanjuan V. Pathogenesis of anterior knee pain syndrome and functional patellofemoral instability in the active young. *Am J Knee Surg* 1999; 12: 29-40.

4. Witonski D. Anterior knee pain syndrome. *Int Orthop* 1999; 23: 341-344.
5. Post WR. Anterior knee pain: diagnosis and treatment. *J Am Acad Orthop Surg* 2005; 13: 534-543.
6. Biedert RM, Kerns V. Neurosensory characteristics of the patellofemoral joint: what is the genesis of patellofemoral pain? *Sports Med Arthros Rev* 2001; 29: 295-300.
7. Biedert RM, Sanchis-Alfonso V. Sources of anterior knee pain. *Clin Sports Med* 2002; 21: 335-347.
8. Fulkerson JP. Diagnosis and treatment of patients with patellofemoral pain. *Am J Sports Med* 2002; 30: 447-456.
9. Witonski D, Wągrow ska-Danielewicz M. Distribution of substance-P nerve fibers in the knee joint in patients with anterior knee pain syndrome. A preliminary report. *Knee Surg Sports Traumatol Arthrosc* 1999; 7: 177-183.
10. Wojtys EM, Beaman DN, Glover RA, et al. Innervation of the human knee joint by substance-P fibers. *Arthroscopy* 1990; 6: 254-263.
11. Henderson B, Pettipher ER. Arthritogenic actions of recombinant IL-1 and tumor necrosis factor α in the rabbit: evidence for synergistic interactions between cytokines in vivo. *Clin Exp Immunol* 1989; 75: 306-310.
12. Saez-Llorens X, Jafari HS, Olsen KD, et al. Induction of suppurative arthritis in rabbit by Haemophilus endotoxin, tumor necrosis factor- α , and interleukin-1 β . *J Infect Dis* 1991; 163: 1267-1272.
13. Thorbecke, GJ, Shah R, Leu CH, et al. Involvement of endogenous tumor necrosis factor and transforming growth factor β during induction of collagen type II arthritis in mice. *Proc Natl Acad Sci U S A* 1992; 89: 7375-7379.
14. Arend WP, Dayer JM. Inhibition of the production and effects of interleukin-1 and tumor necrosis factor α in rheumatoid arthritis. *Arthritis Rheum* 1995; 38: 151-160.
15. Arend WP, Dayer JM. Cytokine and cytokine inhibitors or antagonists in rheumatoid arthritis. *Arthritis Rheum* 1990; 33: 305-315.
16. Tissi L, Puliti M, Barluzzi R, et al. Role of tumor necrosis factor α , interleukin-1 β , and interleukin-6 in a mouse model of group B streptococcal arthritis. *Infect Immun* 1999; 67: 4545-4550.
17. Brittberg M, Winalski CS. Evaluation of cartilage injuries and repair. *J Bone Joint Surg Am* 2003; 85-A Suppl 2: 58-69.
18. Bennell K, Hodges P, Mellor R, et al. The nature of anterior knee pain following injection of hypertonic saline into the infrapatellar fat pad. *J Orthop Res* 2004; 22: 116-121.
19. Bohnsack M, Hurschler C, Demirtas T, et al. Infrapatellar fat pad pressure and volume changes of the anterior compartment during knee motion: possible clinical consequences to the anterior knee pain syndrome. *Knee Surg Sports Traumatol Arthrosc* 2005; 13: 135-141.
20. Bohnsack M, Klages P, Hurschler C, et al. Influence of an infrapatellar fat pad edema on patellofemoral biomechanics and knee kinematics: a possible relation to the anterior knee pain syndrome. *Arch Orthop Trauma Surg* 2009; 129: 1025-1030.
21. Bohnsack M, Meier F, Walter GF, et al. Distribution of substance-P nerves inside the infrapatellar fat pad and the adjacent synovial tissue: a neurohistological approach to anterior knee pain syndrome. *Arch Orthop Trauma Surg* 2005; 125: 592-597.
22. Ushiyama T, Chano T, Inoue K, et al. Matsusue Y. Cytokine production in the infrapatellar fat pad: another source of cytokines in knee synovial fluids. *Ann Rheum Dis* 2003; 62: 108-112.
23. Carlsson AM, Werner S, Mattlar CE, et al. Personality in patients with long-term patellofemoral pain syndrome. *Knee Surg Sports Traumatol Arthrosc* 1993; 1: 178-183.
24. Witoński D, Karlińska I, Musiał A. Personality characteristics in patients with the anterior knee pain syndrome. *Med Sci Monit* 1998; 4: 1019-1023.
25. Brummett BH, Boyle SH, Ortel TL, et al. Associations of depressive symptoms, trait hostility, and gender with C-reactive protein and interleukin-6 response after emotion recall. *Psychosom Med* 2010; 72: 333-339.
26. Bromm B, Lorenz J. Neurophysiological evaluation of pain. *Electroencephalogr Clin Neurophysiol* 1998; 107: 227-253.
27. Myers RR, Wagner R, Sorkin LS. Hyperalgesic action of cytokines on peripheral nerves. In: Cytokines and pain. Watkins LR, Maier SF (eds). Birkhauser Verlag, Basel/Switzerland 1999; 133-157.
28. Bazzichi L, Rossi A, Massimetti G, et al. (2007) Cytokine patterns in fibromyalgia and their correlation with clinical manifestations. *Clin Exp Rheumatol* 2007; 25: 225-230.
29. Salemi S, Rethage J, Wollina U, et al. Detection of interleukin 1 β (IL-1 β), IL-6, and tumor necrosis factor- α in skin of patients with fibromyalgia. *J Rheumatol* 2003; 30: 146-150.
30. Liptan GL. Fascia: A missing link in our understanding of the pathology of fibromyalgia. *J Body Mov Ther* 2010; 14: 3-12.
31. Wang H, Schiltenswolf M, Buchner M. The role of TNF- α in patients with chronic low back pain-a prospective comparative longitudinal study. *Clin J Pain* 2008; 24: 273-278.
32. Heintjes EM, Berger M, Bierma-Zeinstra SMA, et al. Pharmacotherapy for patellofemoral pain syndrome. *Cochrane Database of Systematic Reviews* 2004; Issue 3. Art. No.: CD003470. DOI: 10.1002/14651858.CD003470.pub2

Address for correspondence

Dariusz Witoński
 Department of Reconstructive Surgery
 and Arthroscopy of the Knee
 Medical University of Łódź
 ul. Drewnowska 75
 91-002 Łódź
 phone: +48 42 256 36 02
 fax: +48 42 256 36 02
 e-mail: WitonD@hotmail.com