

# QUIZ

## WHAT IS YOUR DIAGNOSIS?

### Case description

A 31-year-old woman underwent resection of the inguinal lymph node, 3 cm in diameter, with a suspicion of metastasis. Two years ago, a subcutaneous

lesion from the right thigh was excised. There was no family history of malignancy or any other significant pathologies. The microscopic findings of the lymph node (Fig. 1 A, B) and subcutaneous lesion (Fig. 1 C, D) are presented below.

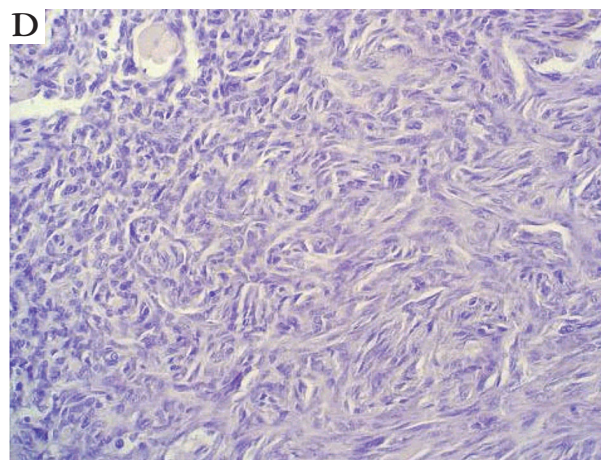
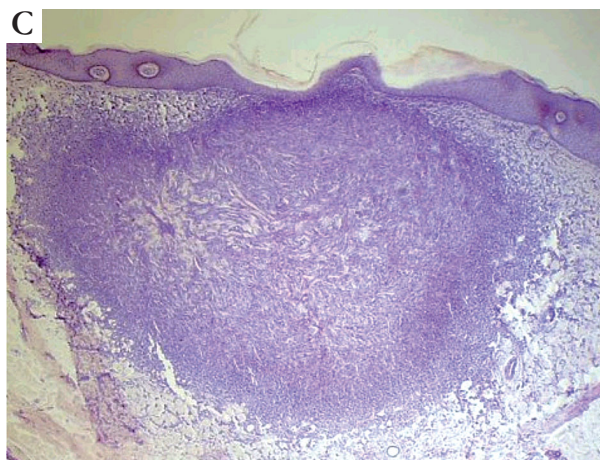
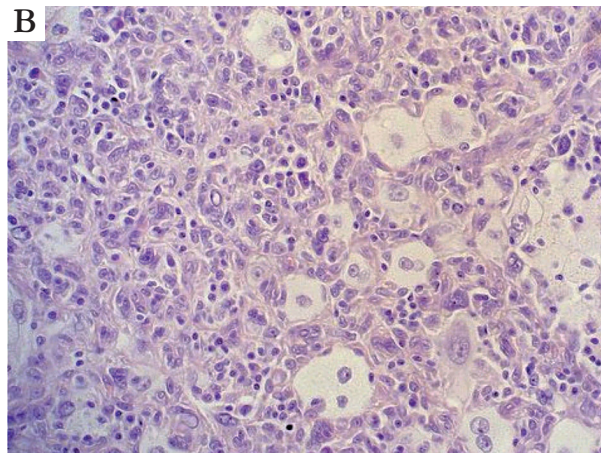
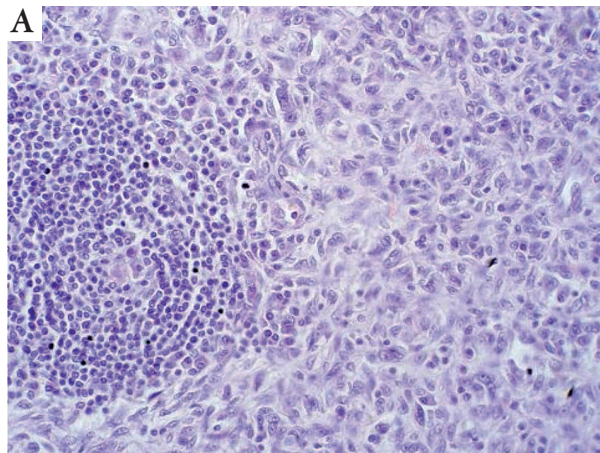


Fig. 1.

Anna Szumera-Ciećkiewicz, Konrad Ptaszyński

Department of Pathology, Maria Skłodowska-Curie Memorial Cancer Centre and Institute of Oncology, Warsaw  
02-781 Warsaw, ul. Roentgena 5, tel. +48 22 546 27 26, e-mail: [annacieckiewicz@coi.waw.pl](mailto:annacieckiewicz@coi.waw.pl)

Answers should be sent to the Editorial Office by 30.09.2011. The correct answer will be announced in the next issue of the *Polish Journal of Pathology*. All participants with the highest number of correct answers to the quizzes published in vol. 62 (4 issues) will be entered into the prize draw for a book.