

# ENDOSCOPIC VERSUS HISTOLOGICAL DIAGNOSIS OF BARRETT'S ESOPHAGUS: A CROSS-SECTIONAL SURVEY

GITI IRVANLOO<sup>1</sup>, BEHNAZ FALLAHI<sup>2</sup>, FERESHTE ENSANI<sup>1</sup>, MEHRDAD AZMI<sup>3</sup>, AFSANEH MORTEZA<sup>4</sup>

<sup>1</sup>Associate Professor of pathology, Tehran University of Medical Sciences, Tehran, Iran

<sup>2</sup>Pathologist, Tehran University of Medical Sciences, Tehran, Iran

<sup>3</sup>Assistant Professor of gastroenterology, Tehran University of Medical Sciences, Tehran, Iran

<sup>4</sup>Farzan Clinical Research Institute, Tehran, Iran

**Context:** Barrett's esophagus is a common pathological condition in patients with gastro-esophageal reflux disease.

**Objective:** The aim of this study was to compare endoscopic diagnosis versus histological confirmation.

**Design:** Cross-sectional. **Setting:** Cancer Institute of the Imam Khomeini Hospital.

**Material and methods:** A total of 50 patients with a history of gastro-esophageal reflux were recruited and underwent upper endoscopy at this cross-sectional survey. Four-quadrant biopsy was taken from all suspected areas of intestinal metaplasia. Sections of blocks were stained with Mixed Alcian Blue (PH 2.5)/PAS and haematoxylin-eosin stainings for the diagnosis of intestinal metaplasia (complete vs. incomplete types) and goblet cell / columnar cell / dysplasia, respectively.

**Main outcome measure:** The presence of *Helicobacter pylori* was assessed by Giemsa staining.

**Results:** There were 44 cases of short-segment Barrett's esophagus and 6 of long-segment Barretts esophagus by endoscopy. When examined by histologic examination, 12 patients with short-segment Barrett's esophagus and 4 with long-segment Barrett's esophagus had intestinal metaplasia. Haematoxylin-eosin staining diagnosed 12 cases of intestinal metaplasia, whereas mixed alcian blue/PAS was used to diagnose 16 cases ( $\kappa = 80\%$ ,  $p < 0.001$ ). The positive predictive value in the diagnosis of goblet cell metaplasia and columnar cell metaplasia was 32% and 66%, respectively. *Helicobacter pylori* infection was observed in 10 cases of those with columnar cell metaplasia without goblet cells, while none of the patients with intestinal metaplasia were infected.

**Conclusion:** Our findings suggest that biopsy taking is necessary in all patients with gastro-esophageal reflux disease, whose results suggest columnar cell lining in distal esophagus in endoscopy.

**Key words:** Barrett's esophagus, mixed alcian blue (PH = 2.5)/PAS, haematoxylin eosin, endoscopy.

## Introduction

Barrett's esophagus is the replacement of the distal esophageal epithelial lining with specialized intestinal mucosa. Nearly 8% to 20% of patients with asymptomatic chronic gastro-esophageal reflux disease are af-

ected [1]. However, some studies have reported 44% of Barrett's esophagus in patients with gastroesophageal reflux disease [2].

Reflux of the gastric content causes ulceration and destruction of the squamous epithelium, which in many

instances is replaced by columnar epithelium [3]. Due to chronic gastritis, reflux progressively damages squamous mucosa and those with specialized columnar epithelium are at an increased risk of developing high-grade dysplasia and adenocarcinoma [4, 5]. Barrett's esophagus is diagnosed by the presence of intestinal type goblet cells in the sections of esophageal biopsies [6, 7]. Most patients are identified during routine endoscopic evaluation [8], but the definite diagnosis is based on histological proof [9, 10]. However, the estimation of standard endoscopic study in the diagnosis of Barrett's esophagus is not known yet. The aim of this study was to compare endoscopy versus pathological staining in the diagnosis of intestinal metaplasia in the Barrett's esophagus.

## Material and methods

We performed a cross-sectional survey of patients with symptomatic gastro-esophageal reflux disease from February 2007 to January 2009. A total of 50 patients were recruited from the Cancer Institute of the Imam Khomeini Hospital. Demographic data including age and sex were investigated for all participants. Patients with one or more of the following criteria including 1 – duration of symptomatic reflux disease of more than 3 years, 2 – no response to proton pump inhibitors and 3 – presence of warning signs like dysphagia, weight loss and gastro-intestinal bleeding, undergone upper endoscopy were recruited. One of the study investigators performed all endoscopic examinations using a standard and END-view video endoscopy (PENTAX EPK-700 and Olympus CV-165). None of the patients were sedated during endoscopy. There were no immediate or long-term complications after any of the endoscopic procedures.

The appearance of the esophagogastric junction, defined as the junction of the proximal end of gastric folds and the tubular esophagus, was carefully noted during the antegrade view before and after retroflexion in the stomach. Barrett's esophagus is diagnosed by the observation of salmon-coloured mucosa extending from the esophagogastric junction with biopsy confirmation of specialized intestinal metaplasia. Biopsies were performed on any tongues of salmon-coloured mucosa arising from the esophagogastric junction, which were suspected of Barrett's esophagus. Four-quadrant biopsy specimens were obtained from all suspected areas of intestinal metaplasia every 1 cm of the length of the columnar epithelium. We did not obtain biopsy specimens of the mid or proximal esophagus. Patients were divided into short-segment Barrett's esophagus (SSBE) (< 3 cm of the length of salmon-coloured mucosa) group and long-segment Barrett's esophagus (LSBE) (> 3 cm of the length of salmon-coloured mucosa) group according to endoscopic findings.

Sections of these blocks were stained with mixed alcian blue (pH = 2.5)/PAS and haematoxylin-eosin

stainings for the diagnosis of intestinal metaplasia (complete vs. incomplete type) and goblet cell / columnar cell/dysplasia, respectively. Slides were then reviewed by a pathologist who was blinded to the results of morphologic evaluation and patient outcome. The presence of *Helicobacter pylori* was assessed by Giemsa staining.

Endoscopic study reported short-segment Barrett's esophagus (SSBE), long-segment Barrett's esophagus (LSBE) and presence of suspicious foci of dysplasia.

Pathological study reports by haematoxylin-eosin staining including epithelial lining types of the distal esophagus (with and without goblet cell mucosa) and the presence of dysplasia. The severity of dysplasia was graded as 0: negative for dysplasia, 1: indefinite for dysplasia, 2: low-grade dysplasia, 3: high-grade dysplasia and 4: intramucosal carcinoma. Reports by mixed alcian blue (PH = 2.5)/PAS included types of epithelial lining (with and without goblet cell) and types of intestinal metaplasia (complete vs. incomplete types).

The research was carried out according to the principles of the declaration of Helsinki. The local ethics review committee of the Tehran University of Medical Sciences approved the study protocols. All participants gave written informed consent before participation.

## Statistical analysis

Variables are presented as numbers and percents. To investigate the endoscopy versus histological study, the  $\chi^2$  and  $\kappa$  analysis was employed. The statistical package SPSS 17 for Windows (Chicago, Illinois, USA) was used for analysis.

## Results

There were 50 participants, with mean age of  $47 \pm 16.32$ . Twenty two of them were males and 38 females. Endoscopic examination had 32% positive predictive value in the diagnosis of intestinal metaplasia while it had 66% positive predictive value in the diagnosis of columnar cell metaplasia without goblet cells. It had 27% PPV in the diagnosis of goblet cell metaplasia and 70% PPV in the diagnosis of columnar cell metaplasia in short-segment Barrett's esophagus. We had only 6 cases of long-segment Barrett's esophagus and 4 of them had intestinal metaplasia. Haematoxylin-eosin staining diagnosed 12 (24%) cases of intestinal metaplasia (Fig. 1), while mixed alcian blue (PH = 2.5)/PAS staining (Fig. 2) diagnosed 16 (32%) cases. Morphological characteristics of the lesions have been shown in (Table I).

There were 93.8% negative predictive value and 93% specificity in the diagnosis of dysplasia. Endoscopic study reported 3 cases of dysplasia and none of them was confirmed with histological studies ( $p = 0.88$ ,  $\kappa = 0.00$ ). There was 1 (2%) case indefinite for dysplasia in the histological examination.

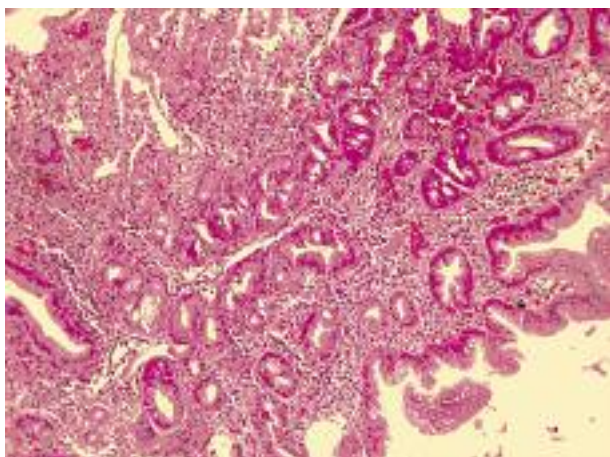


Fig. 1. Haematoxylin and eosin-stained section of intestinal metaplastic epithelium of Barrett's esophagus

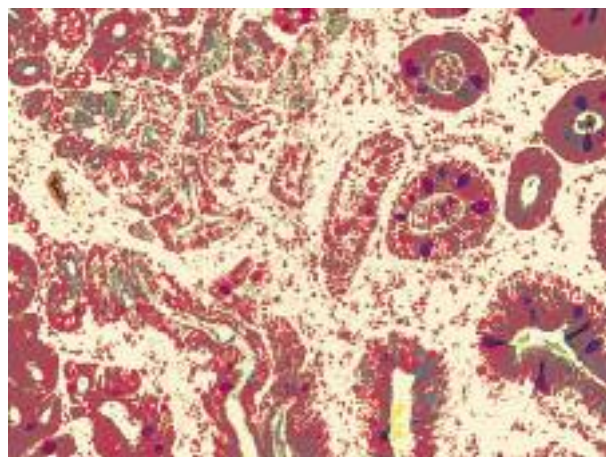


Fig. 2. Alcian blue/PAS stain in Barrett's esophagus with complete metaplasia

Table I. Morphological characteristics of the studied lesions

GROUP HISTOLOGY	SHORT-SEGMENT BARRETT'S ESOPHAGUS (N = 44)	LONG-SEGMENT BARRETT'S ESOPHAGUS (N = 6)	TOTAL	P VALUE
Haematoxylin and Eosine (n%)				
Columnar epithelium	31 (70%)	3 (50%)	34 (66%)	$\kappa = 80\%$ P value < 0.001
Without goblet cells				
Intestinal metaplasia	9 (20%)	2 (33%)	11 (24%)	
Squamous epithelium	4 (10%)	1 (17%)	5 (10%)	
Mixed alcian blue (PH : 2.5) (n%)				
Complete metaplasia	5 (42%)	1 (25%)	6 (37.5%)	
Incomplete metaplasia	7 (57%)	3 (75%)	10 (62.5%)	
Dysplasia (n%)				$\kappa = 0.00$
Endoscopy	2 (4.5%)	1 (16%)	3 (6%)	P value = 0.88
Histology	1 (2.2%)	0	1 (2%)	

Variables are expressed as number and percent.

Ten (20%) cases were infected with *Helicobacter pylori*. None of the patients with intestinal metaplasia were infected while 10 (30.3%) cases of those with columnar cell metaplasia were infected.

## Discussion

We have shown that endoscopy has a 32% positive predictive value in the diagnosis of intestinal metaplasia and 66% positive predictive value in the diagnosis of columnar cell metaplasia. Few studies have evaluated the ability of endoscopy in the diagnosis of Barrett's esophagus; Eloubeidi *et al.* showed a 34% positive predictive value and 97% negative predictive value in the diagnosis of Barrett's esophagus. They suggested alternative methods in the prediction of Barrett's esophagus [11]. Some studies suggest that an increased rate of Barrett's esophagus is irrelevant to the increased use

of endoscopy [12]. Our findings suggest that endoscopy has a low level of positive predictive value (PPV) in the diagnosis of intestinal metaplasia, while it has a higher level of positive predictive value in the diagnosis of columnar cell metaplasia without goblet cell. Our studied population had more columnar cell metaplasia than intestinal metaplasia. As Hahn *et al.* stated, some columnar cell metaplasia has intestinal differentiation and cancerous potentials [13]; thus, endoscopy is a useful method in these patients, however further investigation is suggested in these patients.

Our patients had SSBE 7 times more than LSBE in endoscopic study. This has been shown by Cameron *et al.* as well [14]. In Csendes *et al.*'s study the prevalence of SSBE was 86% when the prevalence of LSBE was about 14% [15]. Other studies have shown prevalence of about 3-5% for LSBE and 10-15% for SSBE [16]. We showed that only 27% of patients with

SSBE had intestinal metaplasia (42% of them had complete intestinal metaplasia and 57% – incomplete type) and 66% of patients with LSBE had intestinal metaplasia. In Csendes *et al.*'s study, 42% of patients with SSBE had intestinal metaplasia [16]; however, another study reported 35% prevalence [15]. Csendes *et al.* have shown 68.1% of intestinal metaplasia in patients with LSBE. They suggested a positive correlation between intestinal metaplasia and length of Barrett's esophagus [15]. In all studied population, there was 32% of intestinal metaplasia (62.5% incomplete type and 37.5% complete type). Csendes *et al.* showed that the prevalence of intestinal metaplasia in patients with gastro-esophageal reflux is about 33% [15], whereas it is about 12% in other studies [17]. It should be taken into account that the diagnosis of intestinal metaplasia is associated with the number of biopsies taken. This difference may be due to the various techniques used in different studies.

In our study, endoscopy had a 93.3% negative predictive value, 0.00% sensitivity and 93% specificity in the diagnosis of dysplasia. Dysplastic foci are not evident in endoscopic study and when there are a limited number of dysplastic foci, it is possible to miss the patients, so four-quadrant biopsy is the preferred method of diagnosis. However, the endoscopist took some biopsies from suspicious dysplastic foci. Histological findings showed a poor correlation with endoscopic study ( $\kappa = 0.00\%$ ,  $p < 0.88$ ). It should be taken into account that we did not use additional methods in endoscopic study for diagnosis of dysplasia, besides we had a small population studied, so further studies are suggested.

*Helicobacter pylori* infection was observed in 10 (30.3%) cases of those with columnar epithelial without goblet cells, while none of the patients with intestinal metaplasia were infected. *Helicobacter pylori* infection is considered a causative agent for gastrointestinal disease like gastritis, peptic ulcer, gastric cancer, and mucosa associated gastric tissue [18, 19]. Besides, it is regarded an essential factor in acid peptic disease [20]. Since the first report of Labenz *et al.*, as to the question whether *H. pylori* eradication would increase the incidence of gastro-esophageal reflux disease [21], many studies showed that *H. pylori* eradication would increase gastro-esophageal reflux disease incidence in patients [19, 22-25]. Our finding is consistent with these observations, as none of the patients with intestinal metaplasia were infected. However, Peitz *et al.* have shown that 50% of patients with Barrett's esophagus were infected with *H. pylori* [26].

In conclusion, according to the results, there is a good significant agreement between haematoxylin-eosin and Mixed Alcian Blue (PH: 2.5)/PAS staining in the diagnosis of intestinal metaplasia ( $p < 0.001$ ,  $\kappa = 80\%$ ). So, routine study with Mixed Alcian Blue (pH = 2.5)/PAS staining is not recommended.

Our findings also suggest that biopsy is necessary in all patients with gastro-esophageal reflux disease, who had results suggesting of columnar cell lining in distal esophagus in endoscopy.

## Acknowledgment

The authors would like to express their sincere gratitude to the Farzan Institute for Research & Technology for technical assistance.

*Work was developed at the Cancer Institute of the Imam Khomeini Hospital.*

## References

1. Kuo CJ, Lin CH, Liu NJ, et al. Frequency and risk factors for Barrett's esophagus in Taiwanese patients: A prospective study in a tertiary referral center. *Dig Dis Sci* 2010; 55: 1337-1343.
2. Fenoglio-Preiser. *Gastrointestinal Pathology: An Atlas and Text*. 3<sup>rd</sup> Edition, Lippincott Williams & Wilkins, Philadelphia 2008.
3. Allescher HD. Diagnosis of gastroesophageal reflux. *Praxis (Bern 1994)* 2002; 91: 779-790.
4. Odze RD. Barrett esophagus: histology and pathology for the clinician. *Nat Rev Gastroenterol Hepatol* 2009; 6: 478-490.
5. Buskens CJ, Hulscher JB, van Gulik TM, et al. Histopathologic evaluation of an animal model for Barrett's esophagus and adenocarcinoma of the distal esophagus. *J Surg Res* 2006; 135: 337-344.
6. Riddell RH, Odze RD. Definition of Barrett's esophagus: time for a rethink – is intestinal metaplasia dead? *Am J Gastroenterol* 2009; 104: 2588-2594.
7. Breyer HP, Silva De Barros SG, Maguilnik I, Edelweiss MI. Does methylene blue detect intestinal metaplasia in Barrett's esophagus? *Gastrointest Endosc* 2003; 57: 505-509.
8. Yilmaz N, Tuncer K, Tunçyürek M, et al. The prevalence of Barrett's esophagus and erosive esophagitis in a tertiary referral center in Turkey. *Turk J Gastroenterol* 2006; 17: 79-83.
9. Ringhofer C, Lenglinger J, Izay B, et al. Histopathology of the endoscopic esophagogastric junction in patients with gastroesophageal reflux disease. *Wien Klin Wochenschr* 2008; 120: 350-359.
10. Chang CY, Lee YC, Lee CT, et al. The application of Prague C and M criteria in the diagnosis of Barrett's esophagus in an ethnic Chinese population. *Am J Gastroenterol* 2009; 104: 13-20.
11. Eloubeidi MA, Provenzale D. Does this patient have Barrett's esophagus? The utility of predicting Barrett's esophagus at the index endoscopy. *Am J Gastroenterol* 1999; 94: 937-943.
12. Alcedo J, Ferrandez A, Arenas J, et al. Trends in Barrett's esophagus diagnosis in Southern Europe: implications for surveillance. *Dis Esophagus* 2009; 22: 239-248.
13. Hahn HP, Blount PL, Ayub K, et al. Intestinal differentiation in metaplastic, nongoblet columnar epithelium in the esophagus. *Am J Surg Pathol* 2009; 33: 1006-1101.
14. Cameron AJ, Kamath P, Carpenter HC. Barrett's esophagus: The prevalence of short and long segments in reflux patients. *Dis Esoph* 1996; 763-767.
15. Csendes A, Smok G, Burdiles P, et al. Prevalence of intestinal metaplasia according to the length of the specialized columnar epithelium lining the distal esophagus in patients with gastroesophageal reflux. *Dis Esophagus* 2003; 16: 24-28.
16. Spechler SJ. Clinical practice. Barrett's esophagus. *N Engl J Med* 2002; 346: 836-842.
17. Phillips RW, Wong RK. Barrett's esophagus. Natural history, incidence, etiology, and complications. *Gastroenterol Clin North Am* 1991; 20: 791-816.

18. Chu B, Jiang LR, Zhou S, et al. Relationship between the types of *Helicobacter pylori* strains and chronic upper gastrointestinal diseases in children. *Chin J Contemp Pediatr* 2007; 9: 201-204.
19. Gold BD. *Helicobacter pylori* infection in children. *Cur Prob Pediatr* 2001; 31: 247-266.
20. Daugule I, Rumba I, Alksnis J, Ejderhamn J. *Helicobacter pylori* infection among children with gastrointestinal symptoms: A high prevalence of infection among patients with reflux oesophagitis. *Acta Paediatr* 2007; 96: 1047-1049.
21. Labenz J, Blum AL, Bayerdörffer E, et al. Curing *Helicobacter pylori* infection in patients with duodenal ulcer may provoke reflux esophagitis. *Gastroenterology* 1997; 112: 1442-1447.
22. Hamada H, Haruma K, Mihara M, et al. High incidence of reflux esophagitis after eradication therapy for *Helicobacter pylori*: impacts of hiatal hernia and corpus gastritis. *Aliment Pharmacol Ther* 2000; 14: 729-735.
23. Sarnelli G, Ierardi E, Grasso R, Verde C, et al. Acid exposure and altered acid clearance in GERD patients treated for *Helicobacter pylori* infection. *Diges Liver Dis* 2003; 35: 151-156.
24. Brazowski J, Nowak A, Szaflarska-Poplawska A. Prevalence of *Helicobacter pylori* infection among children and youth with acid gastroesophageal reflux. *Przegląd Lekarski* 2006; 63: 128-130.
25. Souza RC, Lima JH. *Helicobacter pylori* and gastroesophageal reflux disease: A review of this intriguing relationship. *Dis Esophagus* 2009; 22: 256-263.
26. Peitz U, Hackelsberger A, Günther T, et al. The prevalence of *Helicobacter pylori* infection and the pattern of gastritis in Barrett's esophagus. *Dig Dis* 2001; 19: 164-169.

### Address for correspondence

**Behnaz Fallahi MD**

P.O. Box: 13185-1678, Tehran, Iran

phone: +9821 66439463

fax: +9821 66423304

e-mail: drbfallahi@gmail.com