

ADVANCES IN

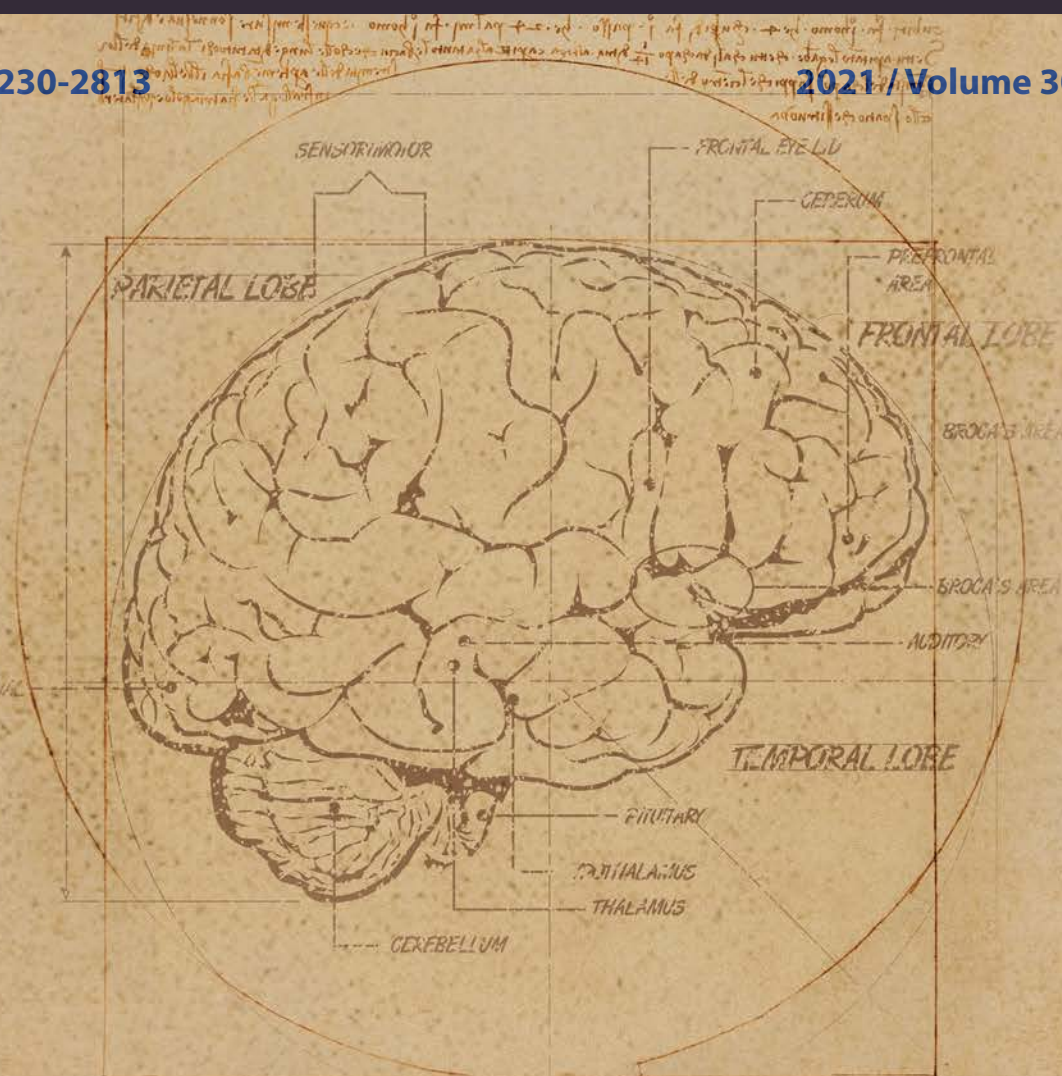
PSYCHIATRY & NEUROLOGY

POSTĘPY

Psychiatrii i Neurologii

ISSN: 1230-2813

2021 / Volume 30 / Issue 4

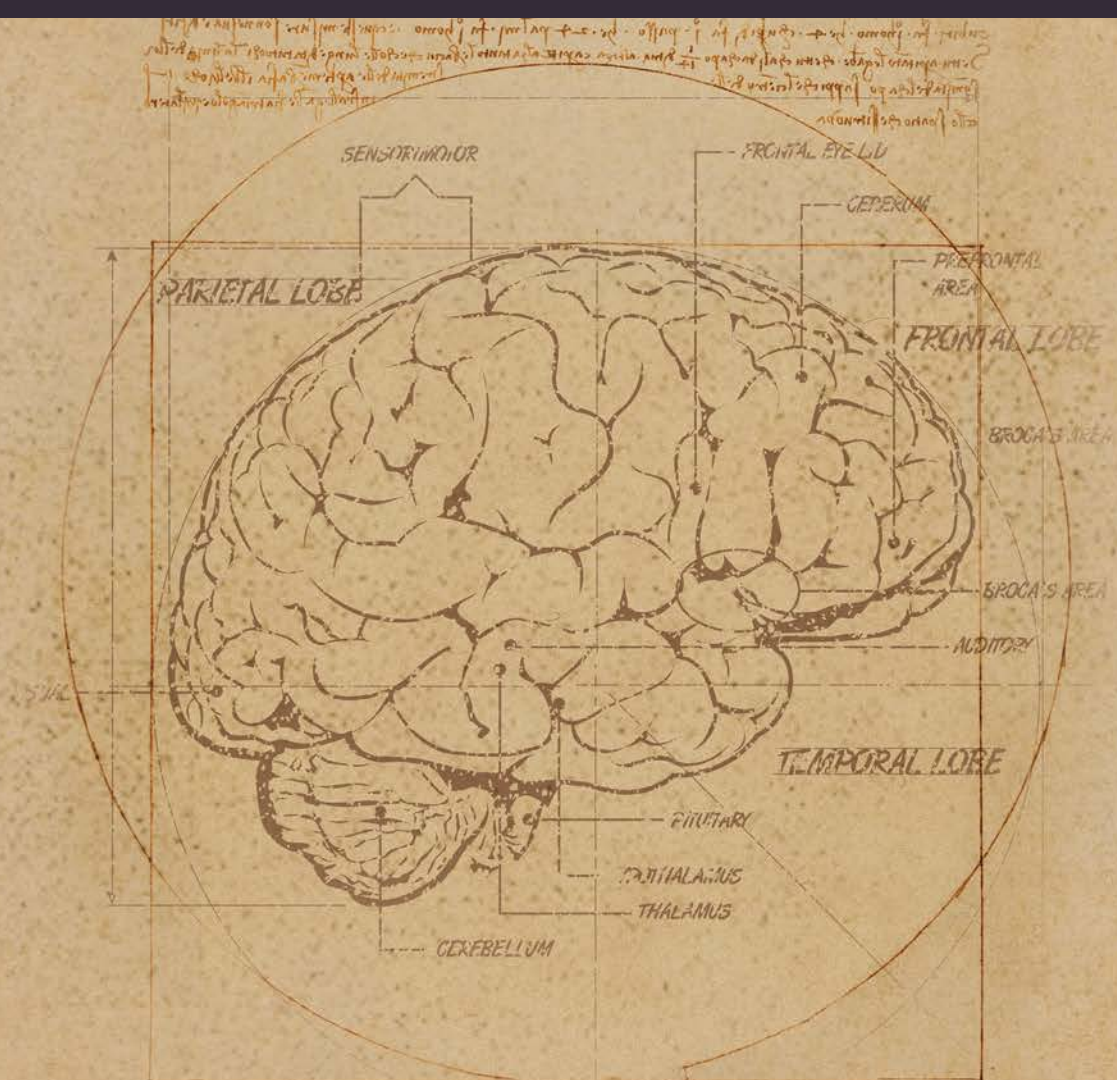


ISSN: 1230-2813



9 771230 281149





This diagram illustrates the various lobes and structures of the human brain, including the cerebrum, cerebellum, and brainstem. The labels identify key areas such as the frontal lobe, parietal lobe, temporal lobe, and the sensory and motor regions.

The diagram is a detailed anatomical drawing of the human brain, showing the cerebrum, cerebellum, and brainstem. The labels identify key areas such as the frontal lobe, parietal lobe, temporal lobe, and the sensory and motor regions.

This diagram illustrates the various lobes and structures of the human brain, including the cerebrum, cerebellum, and brainstem. The labels identify key areas such as the frontal lobe, parietal lobe, temporal lobe, and the sensory and motor regions.