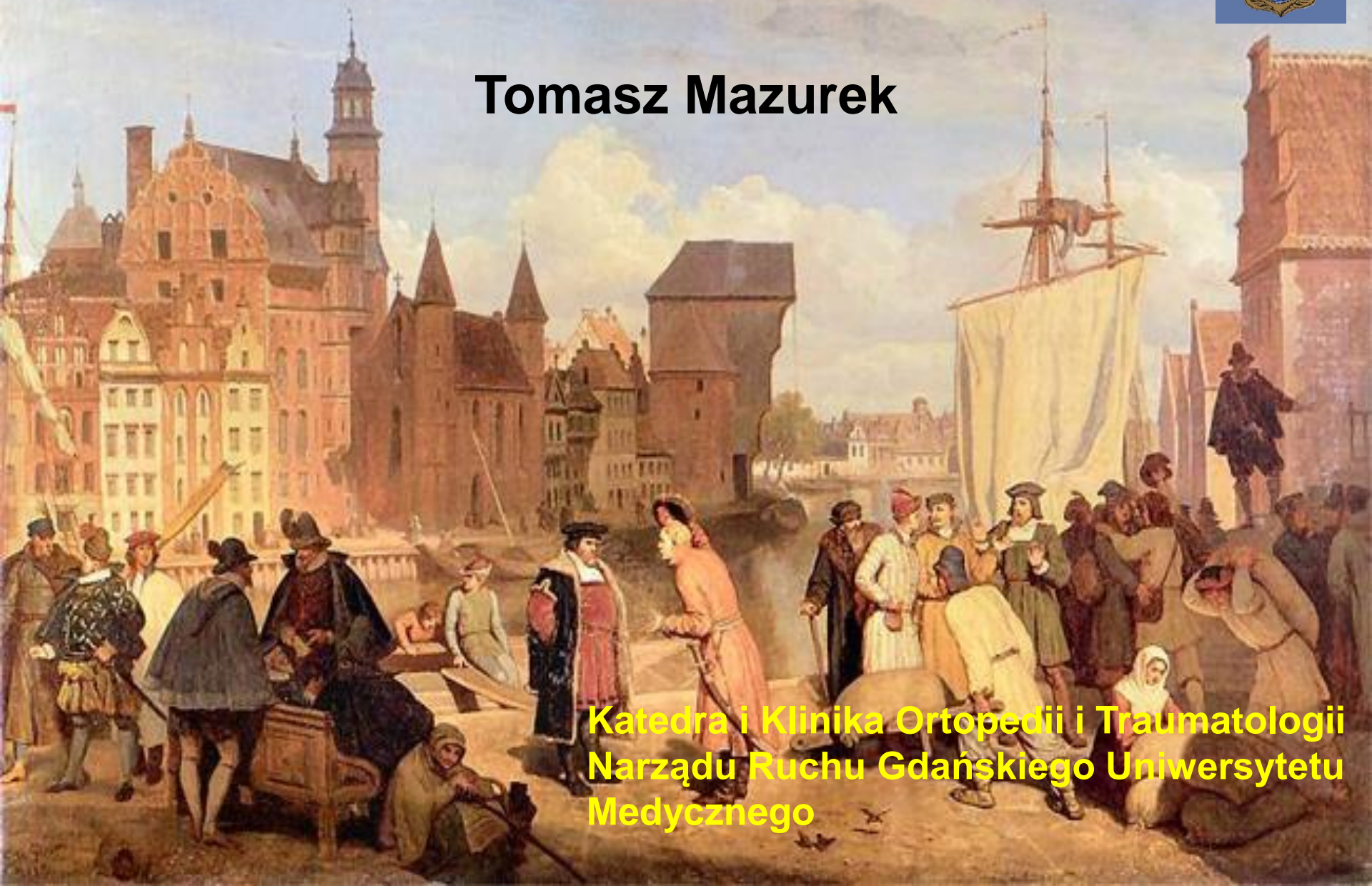


Two-stage reconstruction of the flexor tendons



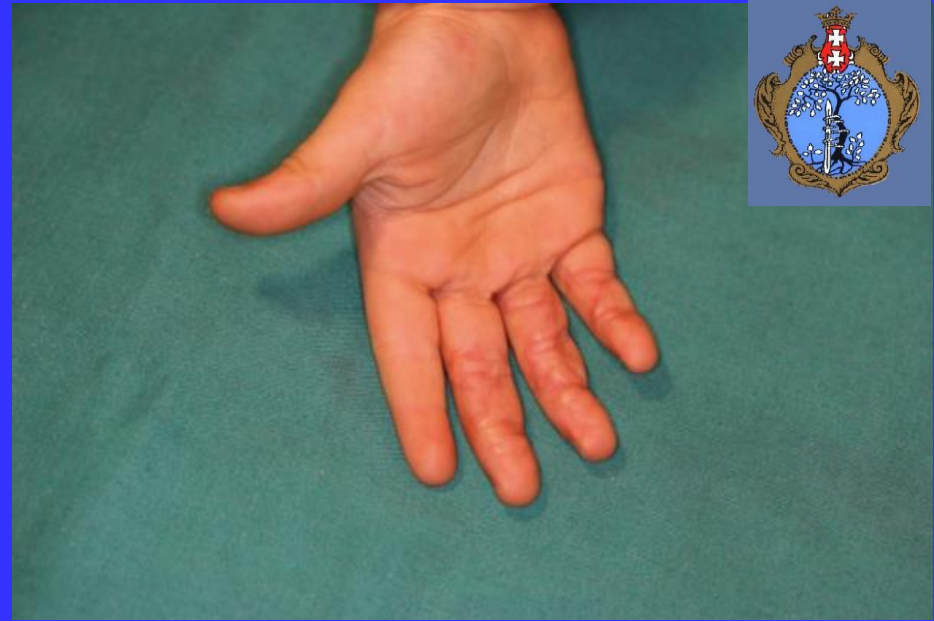Tomasz Mazurek



**Katedra i Klinika Ortopedii i Traumatologii
Narządu Ruchu Gdańskiego Uniwersytetu
Medycznego**



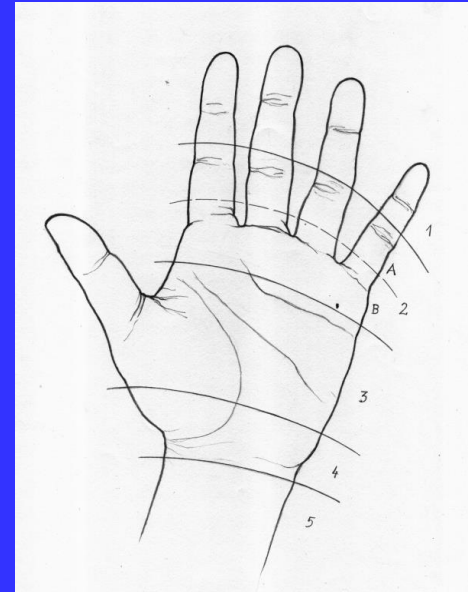
Causes of failures of flexor tendons injuries:



- negligence and oversight of the primary damage
- failure of the primary procedure: separation of the anastomosis, scar formation between the anastomosis and surrounding tissue
- the lack of primary possibility of reconstruction because of ripping of tendon fragment or inflammatory process in the wound
- the lack of primary possibility of reconstruction because of other injuries or general illnesses




1. Distal to the tendon sheath
2. Tendon sheath – no man's land
3. Midcarpal
4. Wrist
5. Antebrachium



Kleinert's and Nigst's zones

- anatomical specifics – e.g. presence of the tendon sheath in zone 2
- the ways of repair



The ways of reconstruction:



- do nothing - in patients who are uninterested in procedures and with local or general difficulties in performing of the procedure
- tenolysis – after primary repair with continuity of the anastomosis and adhesions – usg or operative estimation
- one stage reconstruction – 1,2 zones (only skin, small scar) – small damage, to grade 2 Boyes scale, the lack of tendon prosthesis
- two stage reconstruction - 1,2 zones – serious damage, above grade 2 Boyes scale
- simple suture – 3,4,5 zones – suture without tension
- tendon transfer – 3,4,5 zones - suture is impossible without tension



The idea of two stage flexor tendon reconstruction

Two stage flexor tendon reconstruction is dedicated for damage of the flexor tendon in tendon sheath – zone 2 – poor vascularity of the tendon and serious scar and adhesion formation



Zone 2 = tendon sheath zone = no man's land – Sterling Bunnell's term



No man's land




No man's land – Bunnell's idea of bypass zone 2 in primary and secondary flexor tendon repair – the idea of using tendon graft and doing suture outside of the tendon sheath

No man's land in history:

- the land on the border of London in the Middle Ages when execution was performed- the land without owner
- commonly associated with the First World War to describe the area of land between two enemy trench systems





The poor results of the one stage procedure in reconstruction led to investigations of tendon prosthesis for rebuilding of the wall of the tendon sheath

Thatcher H. H.: Use of stainless steel rods to canalize flexor tendon sheaths. Southern Med. J, 1939, 32, 13-18.

The turning point – 1965 J. Hunter

Introducing of silicone-dacrone reinforced gliding prosthesis and two-stage flexor tendon reconstruction

Hunter J. M.: Artificial tendons. Early development and application. 1965, Am. J. Surg. 109, 325-338.

Hunter, J.M., Salisbury, R.E.: Flexor tendon reconstruction in severely damaged hands. A two-stage procedure using a silicone-dacron reinforced gliding prosthesis prior to tendon grafting. J. Bone Joint Surg. 1971, 53A, 829–858.

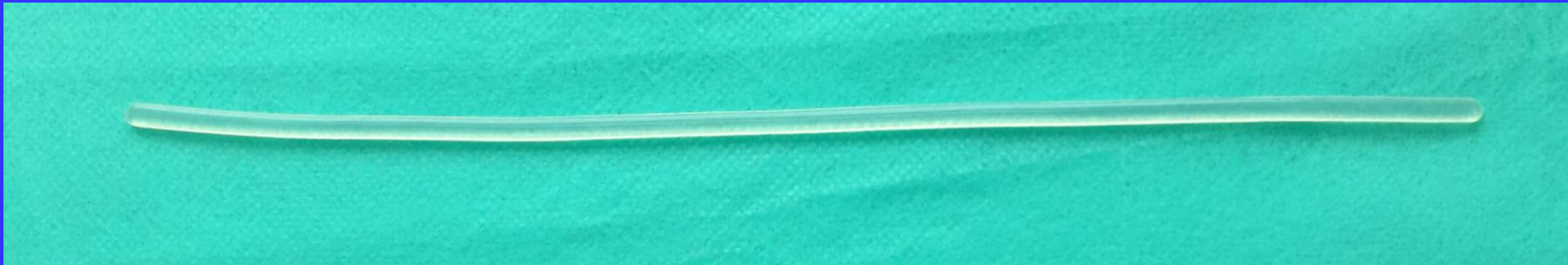Flexor tendon prosthesis



-passive

-Active

Most commonly passive silicone rods in oval shape, the width of 2.5, 3.5, 4.5, 6 mm and the length of 24 cm are used.

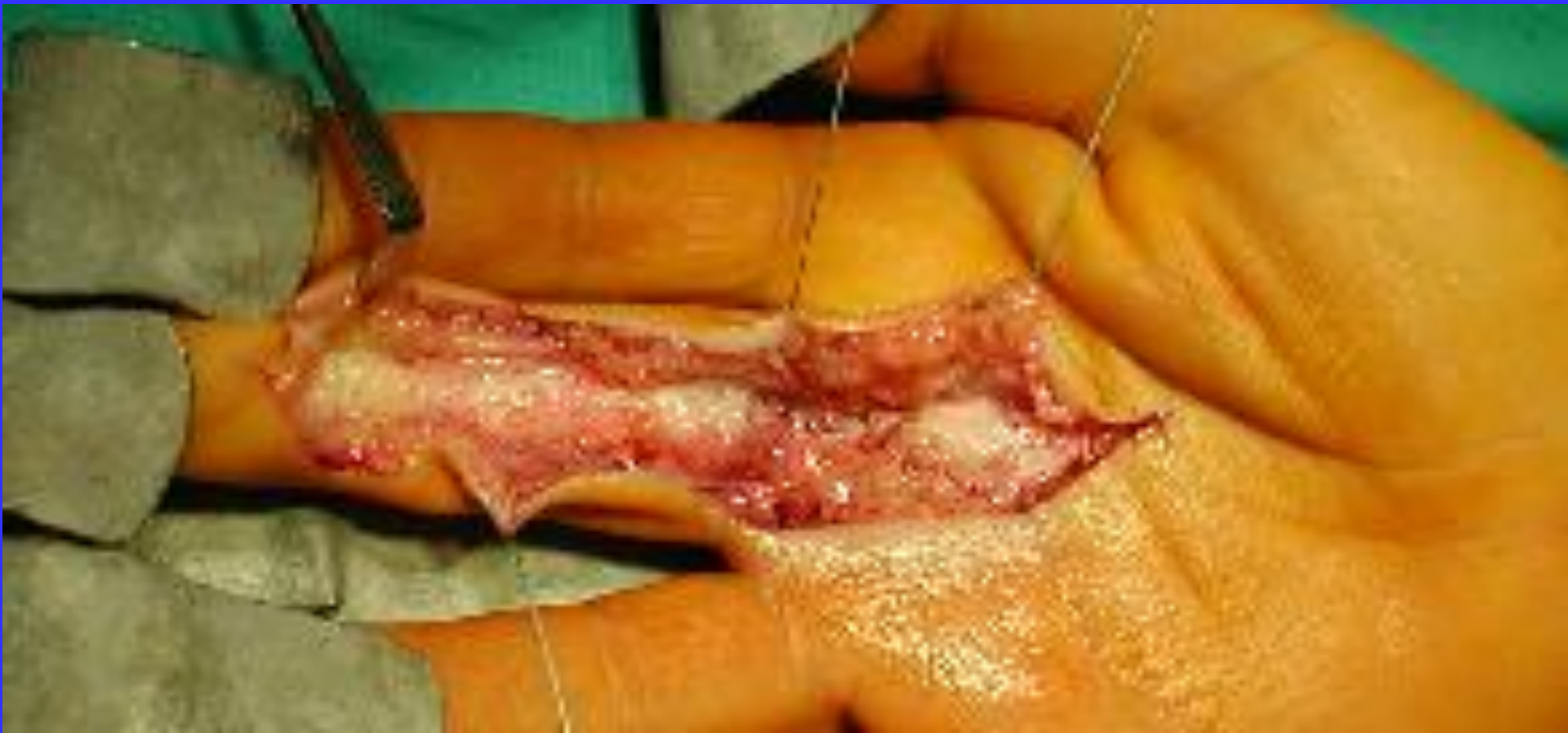

Silicon prosthesis : high physical requirements data

- hardness $53 \pm 5^{\circ}$ Shore'a A
- tensile strenght not less than $7\text{N}/\text{mm}^2$
- elongation at break not less than 360%.

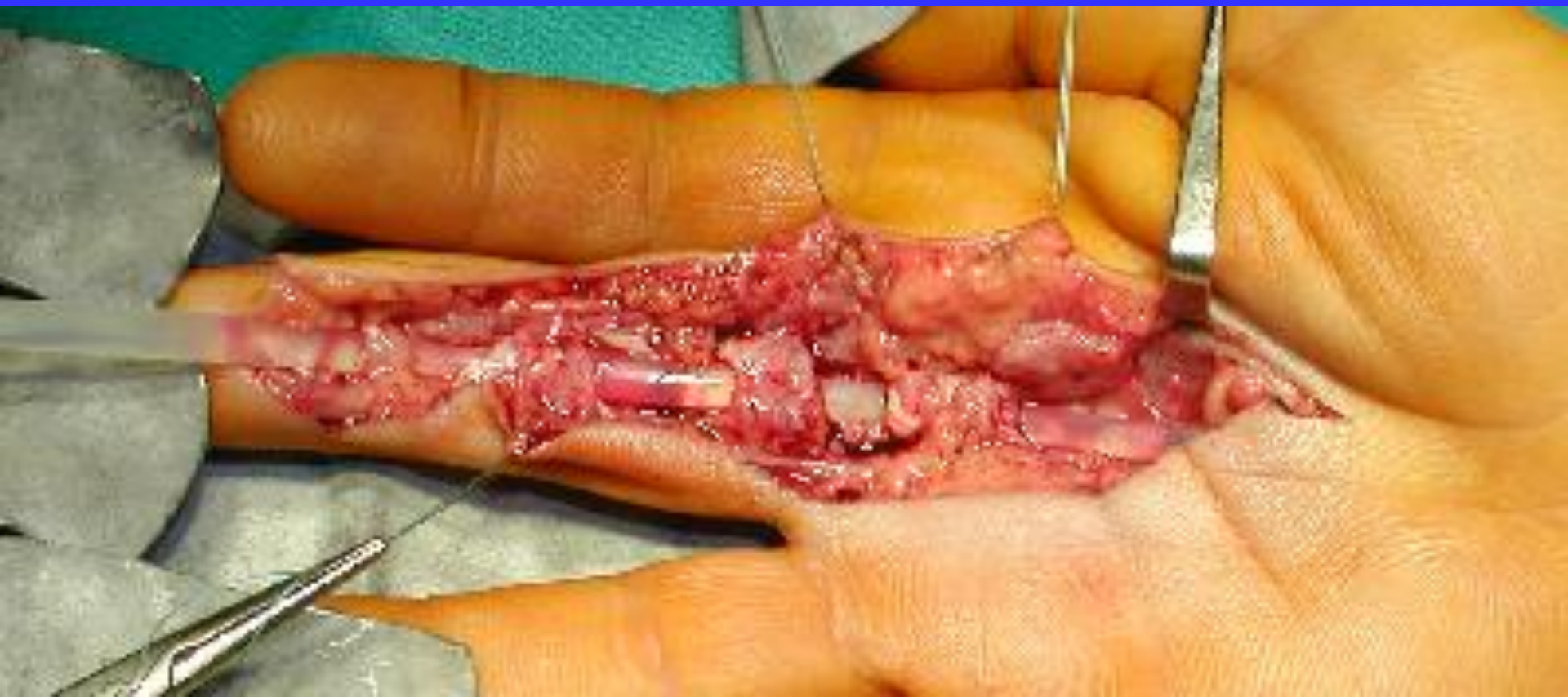First Stage

- removing of the destroyed tendons and tendon sheath
- restoration of the pulley, particularly A2 and A4
- introducing of the tendon prosthesis
- repair of the nerves, joints (capsulotomy) and skin (scars)



First Stage

- removing of the destroying tendons
- restoration of the pulley, particularly A2 and A4
- introducing of the tendon prosthesis
- repair of the nerves, joints (capsulotomy) and skin scars (plasty)



Second stage



Crucial is preparing all parts of the procedure in the way that allows active rehabilitation protocol

Proximal juncture

- using strong weave suture (Pulvertaft) in connection of the proximal stump and tendon graft

Tendon graft

- using intrasynovial and large size graft, FDS is better than PI and Pt



Distal attachment to bony phalanx

- using the strong connection between tendon graft and phalanx

Proximal juncture – the choice of the method



Weave suture (Pulvertaft)



Mazurek T., Strankowski M., Ceynowa M, Ročławski M.: Tensile strength of a weave tendon suture using tendons of different sizes.

Clin. Biomech. 2011, 26, 415-418.

Proximal juncture – the choice of the method



In connections of the tendons in flexor tendons reconstruction we use:

FDS/FDP – flexor digitorum superficialis/profundus


PI – palmaris longus

Pt – plantaris

Connection FDS/FDP-FDS/FDP or FDS/FDP – PI
is above the strength for active rehabilitation protocol



Connection FDS/FDP – Pt
is below the strength for active rehabilitation protocol



Mazurek T., Strankowski M., Ceynowa M, Ročlawski M.: Tensile strength of a weave tendon suture using tendons of different sizes.

Clin. Biomech. 2011, 26, 415-418.



Tendon graft – the choice of the tendon

Using intra-synovial and large tendon graft (FDS) is better than extra-synovial and small tendons (PI, Pt)

- healing without necrosis and adhesion

Gelberman R. H., Siegel D. B., Woo S. L.: Healing of digital flexor tendons: Importance of the interval from injury to repair: A biomechanical, biochemical, and morphological study in dogs.

J. Bone Joint. Surg. Am. 1991, 73, 66-75.

- strong biomechanical properties of FDS in comparison to PI, Pt allows active rehabilitation protocol

Mazurek T., Strankowski M., Ceynowa M, Ročławski M.: Tensile strength of a weave tendon suture using tendons of different sizes.

Clin. Biomech. 2011, 26, 415-418.

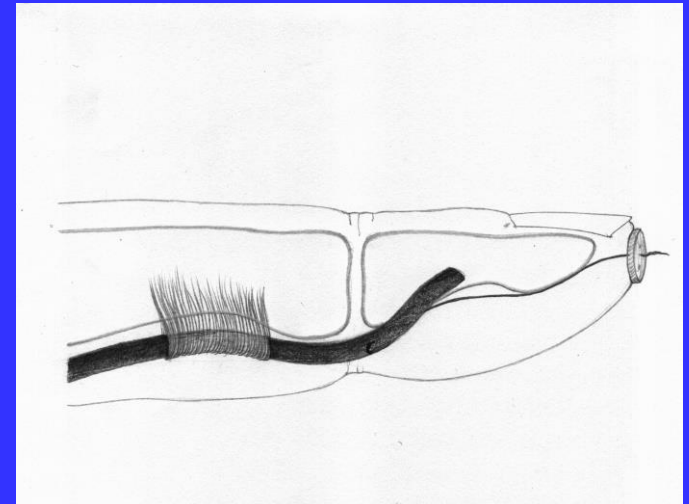
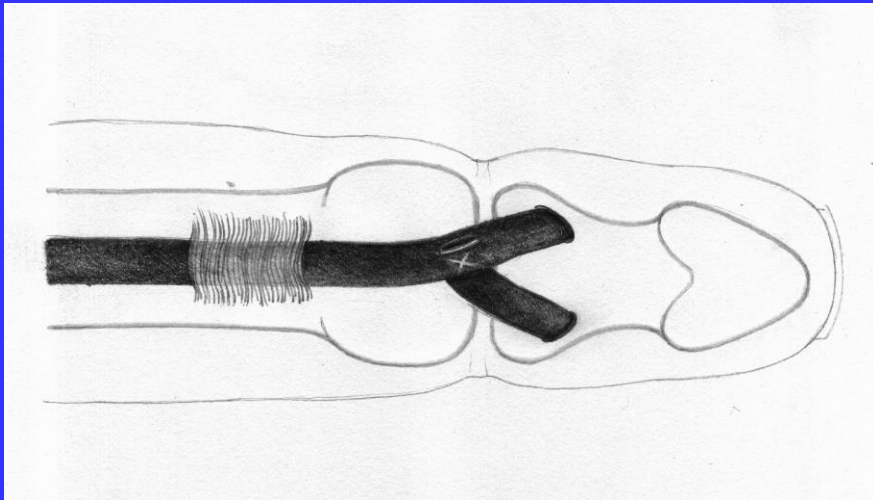


Distal attachment – the choice of the method

There are a lot of ideas of connection

tendon graft - bony phalanx

Part of them is good looking on the paper but is very difficult in practice or causes soft tissue damage - were excluded in our investigations



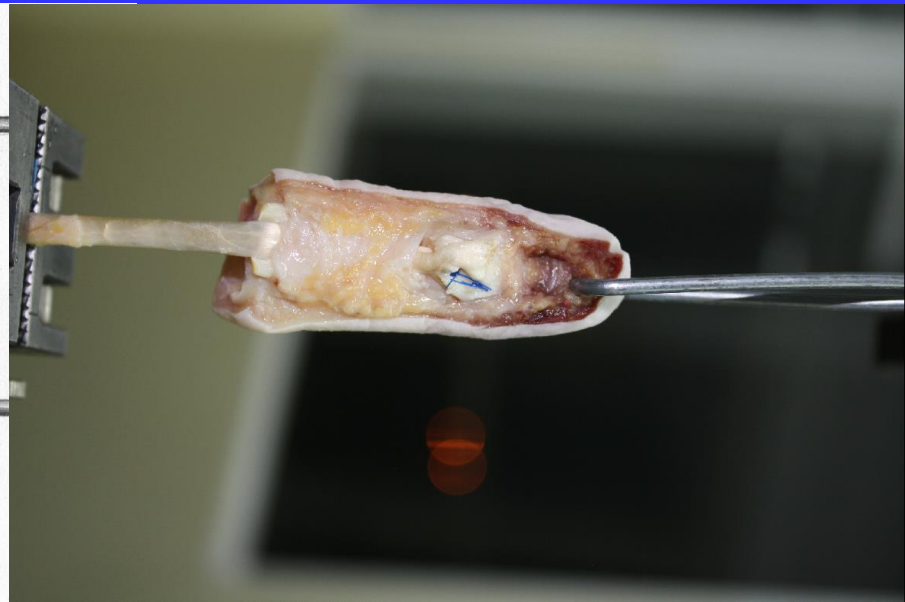
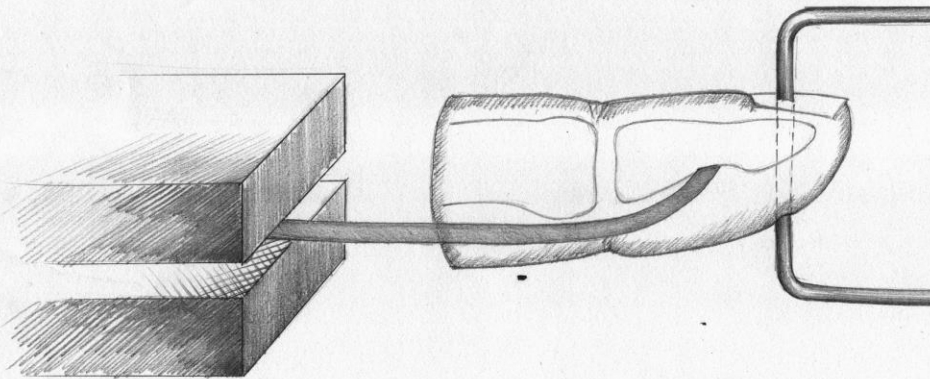
The aim of the study:

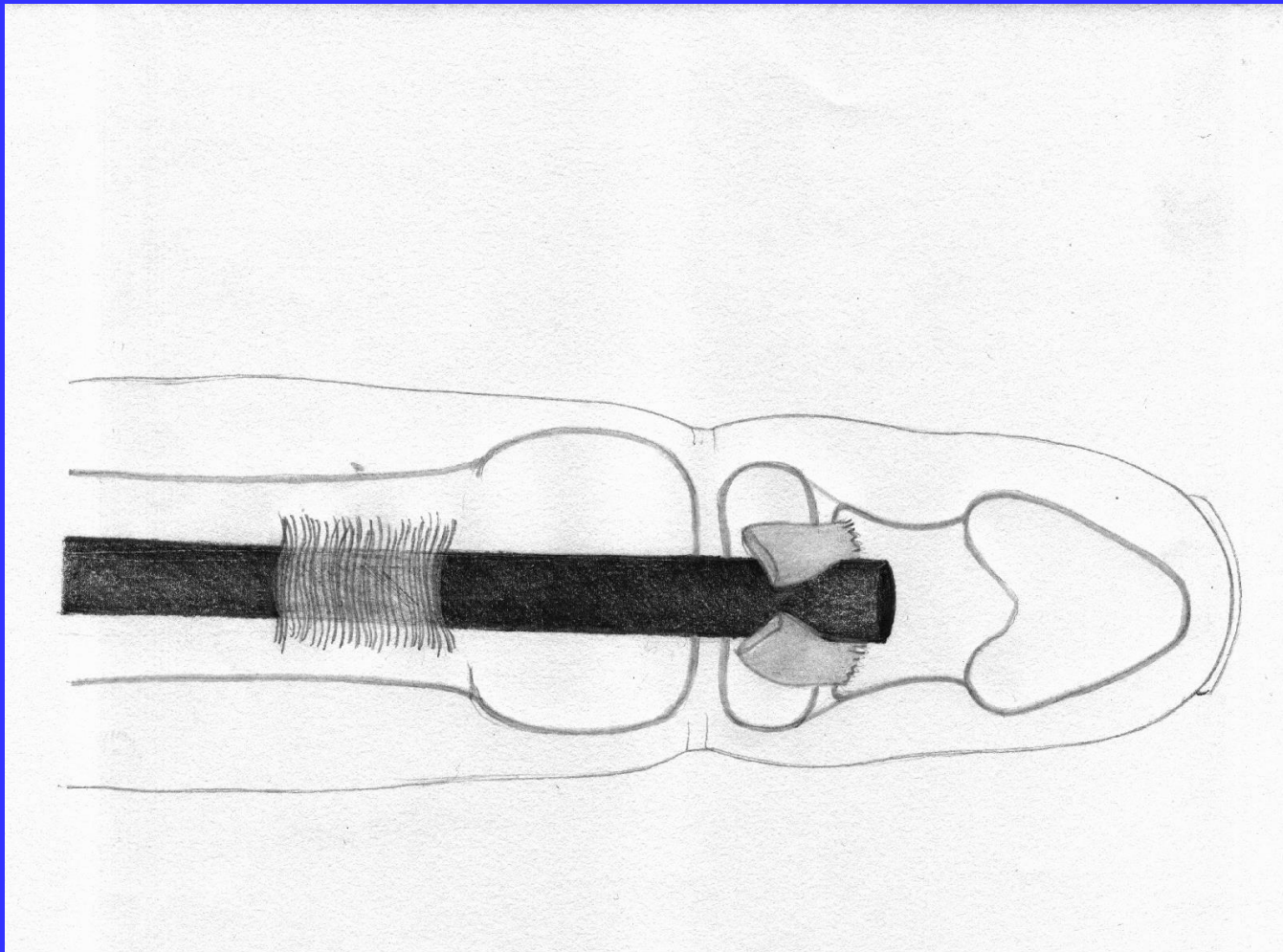


Tensile strength of tendon graft fixation to bony phalanx of the hand in different methods in adults and children.

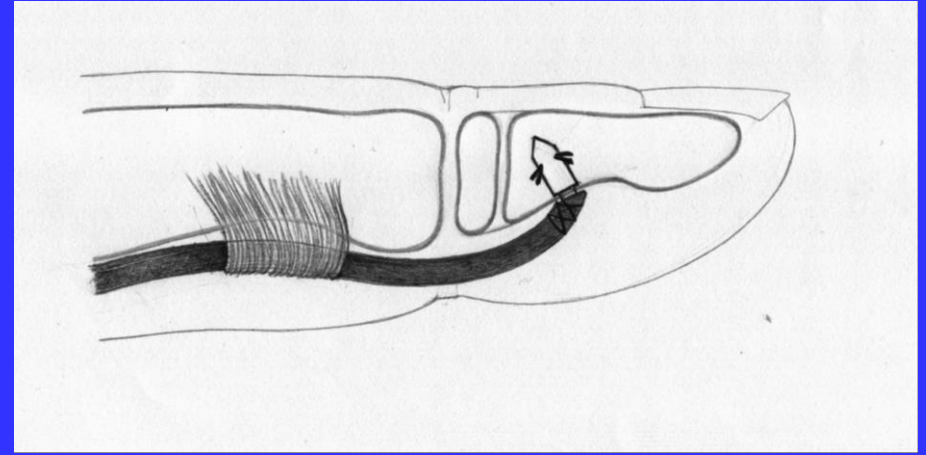
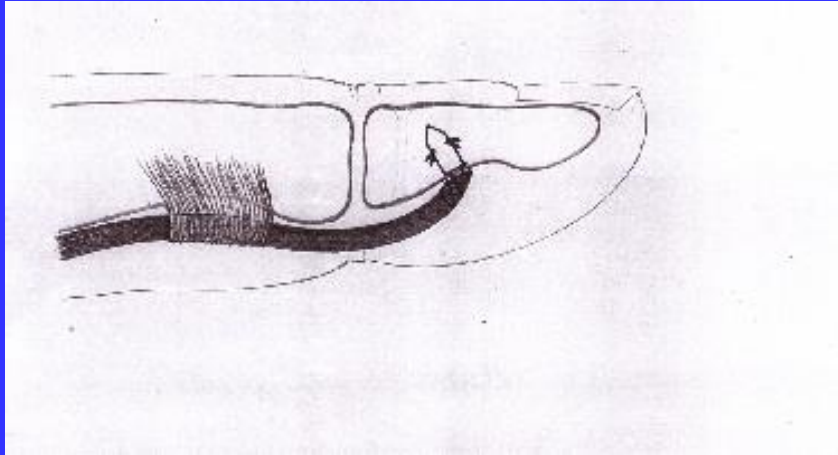
Assessment of indications for active rehabilitation.

Idea and the test machine:

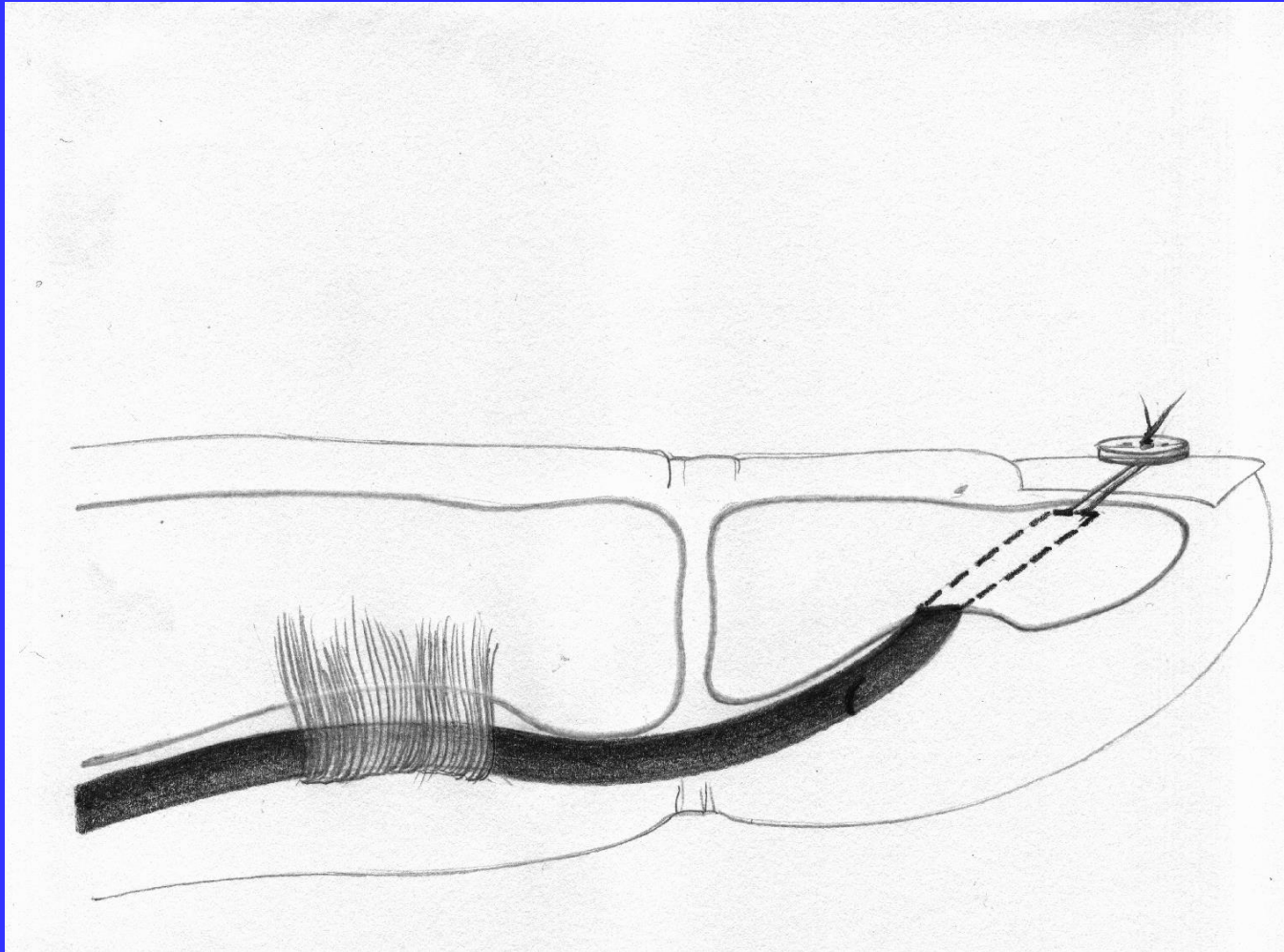




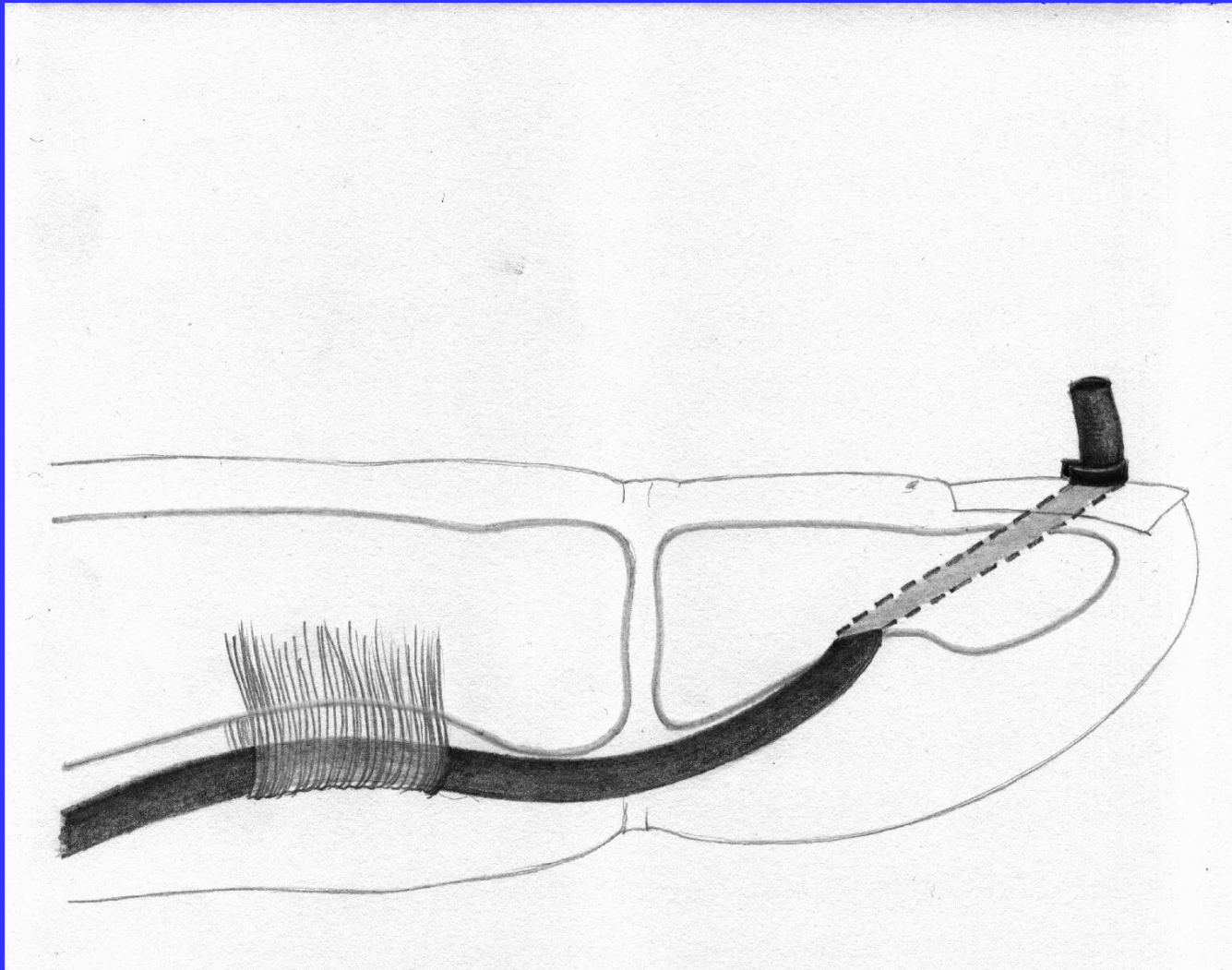
The connection of tendon graft to the FDP stump possible in adults and children (suture)



**The connection of the tendon graft to the bony phalanx using an anchor
– possible in adults and children**



The Wilson technique of pulling out the tendon graft into the distal phalanx – possible only in adults

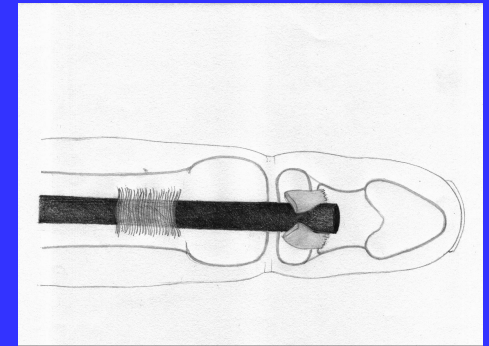
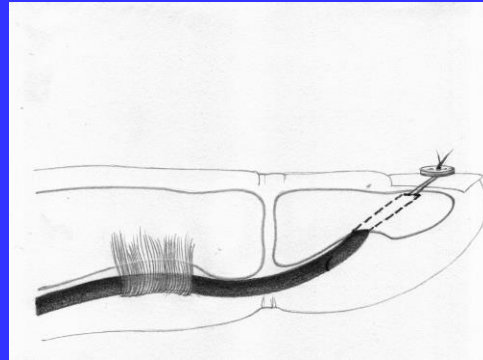
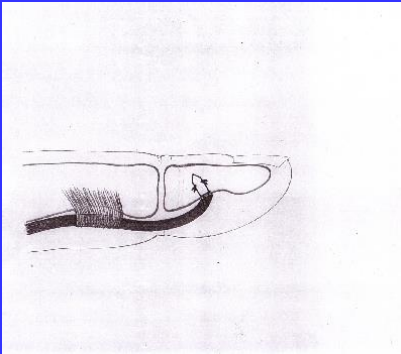


The Snow and Littler technique of pulling out the tendon graft out above the nail



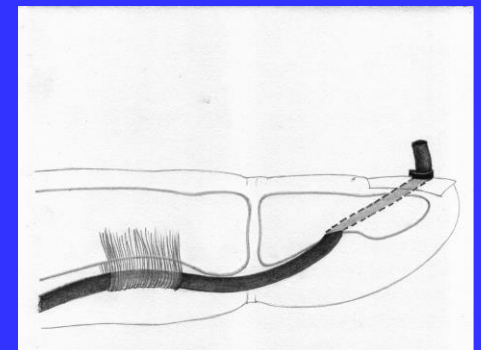
Adults - active rehabilitation protocol

- Tendon graft - anchor – 32 N the best
- Tendon graft - Wilson – 26 N
- Tendon graft – suture – 20 N



Passive rehabilitation protocol

- Tendon graft – Snow – 9 N

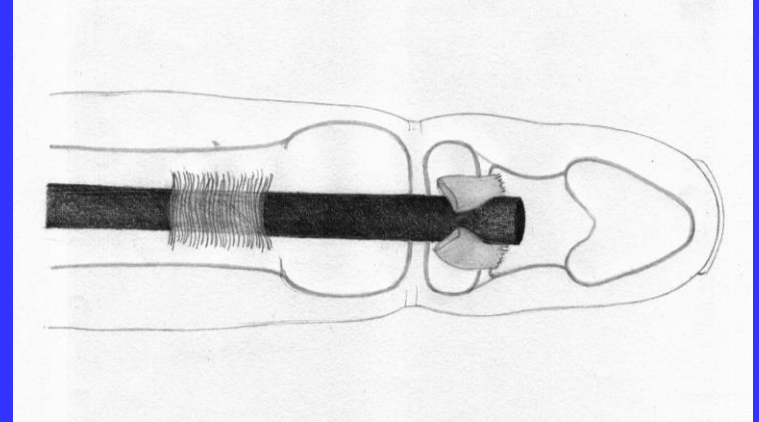


Children



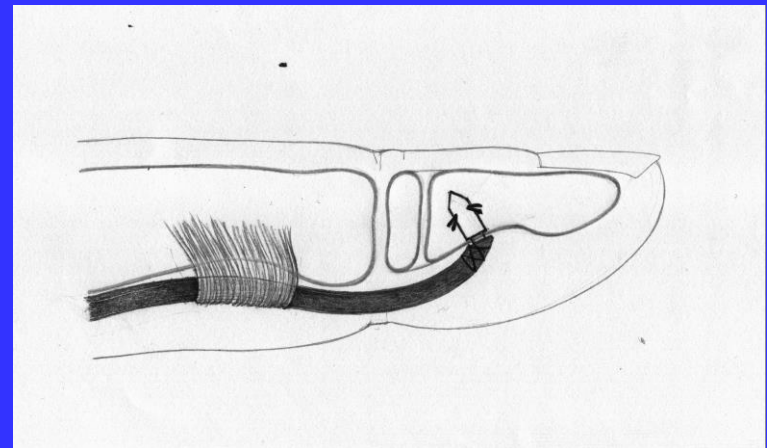
Active rehabilitation protocol
- Tendon graft – suture

– 30 N



Passive rehabilitation protocol
- Tendon graft - anchor
(too soft bone in children)

– 17 N

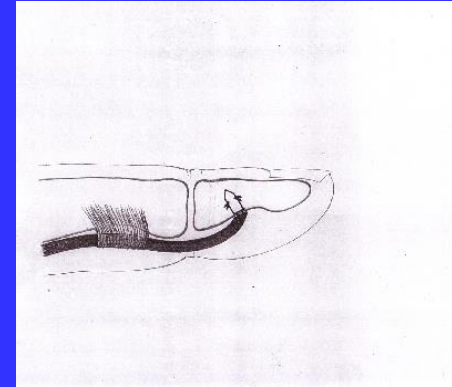


Conclusions



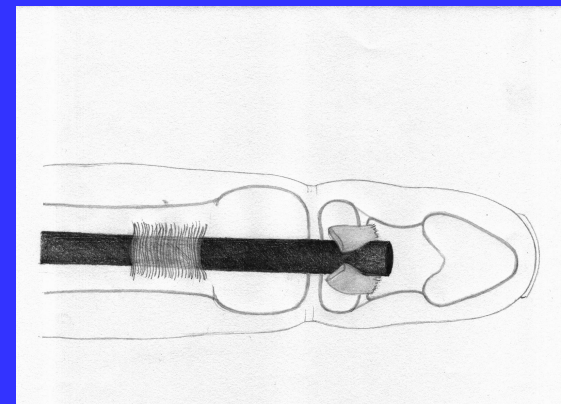
The best biomechanically connection in adults is achieved by using the anchor

Tendon graft – anchor



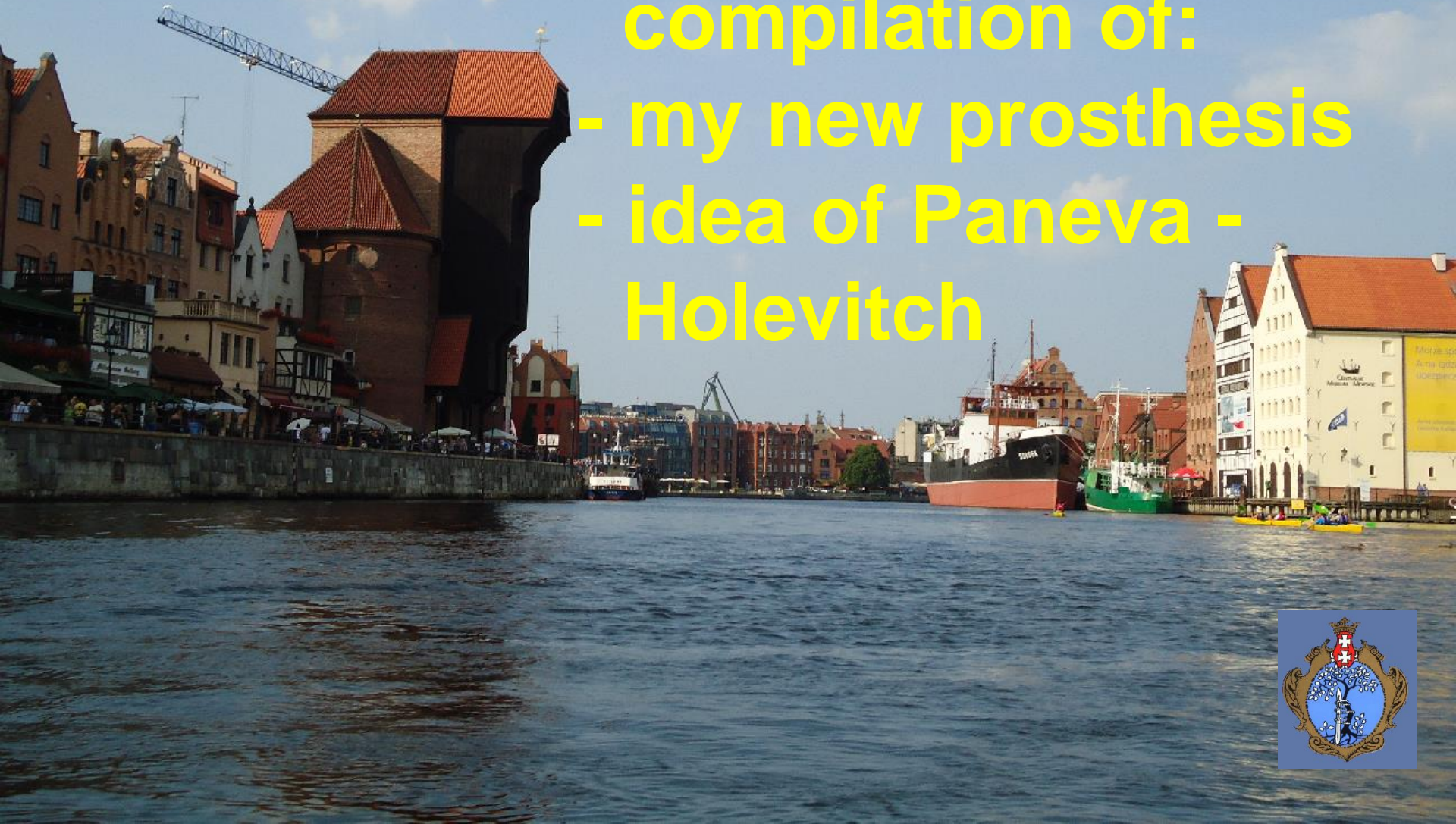The best biomechanically connection in children is achieved by using the suture

Tendon graft – FDP stump




My preferred two-stage technique of flexor tendon reconstruction is a compilation of:

- my new prosthesis
- idea of Paneva - Holevitch





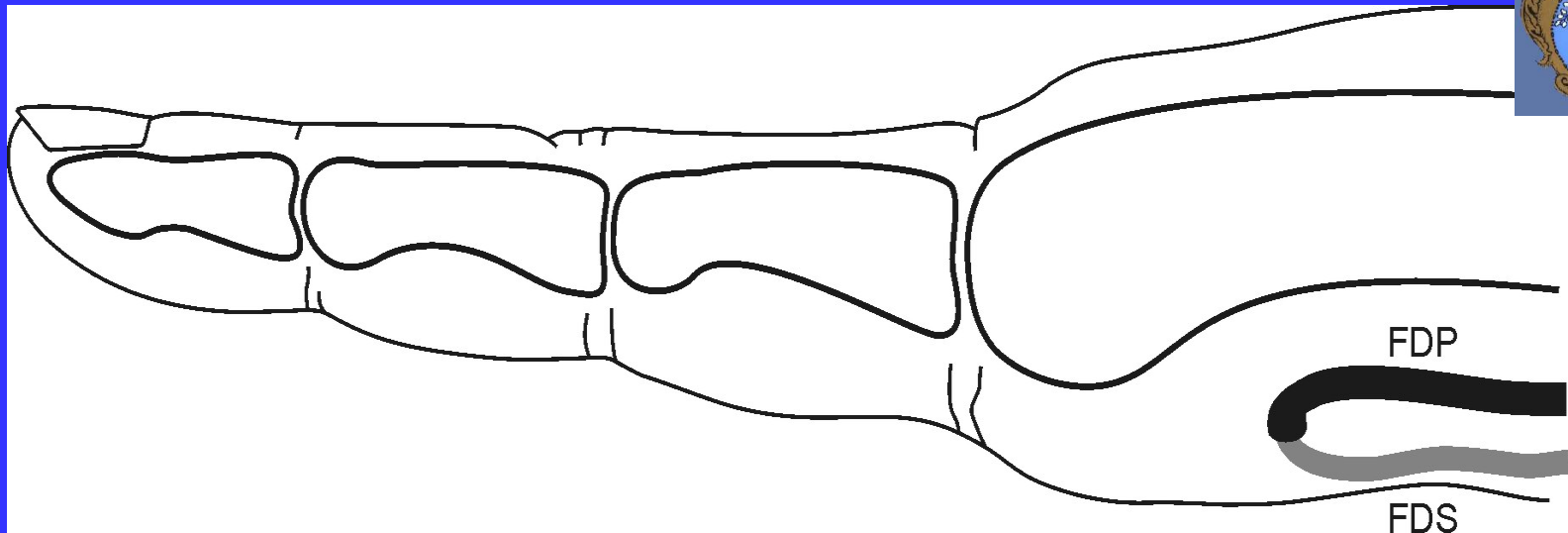
Author' s original tendon prosthesis



Author's original tendon prosthesis

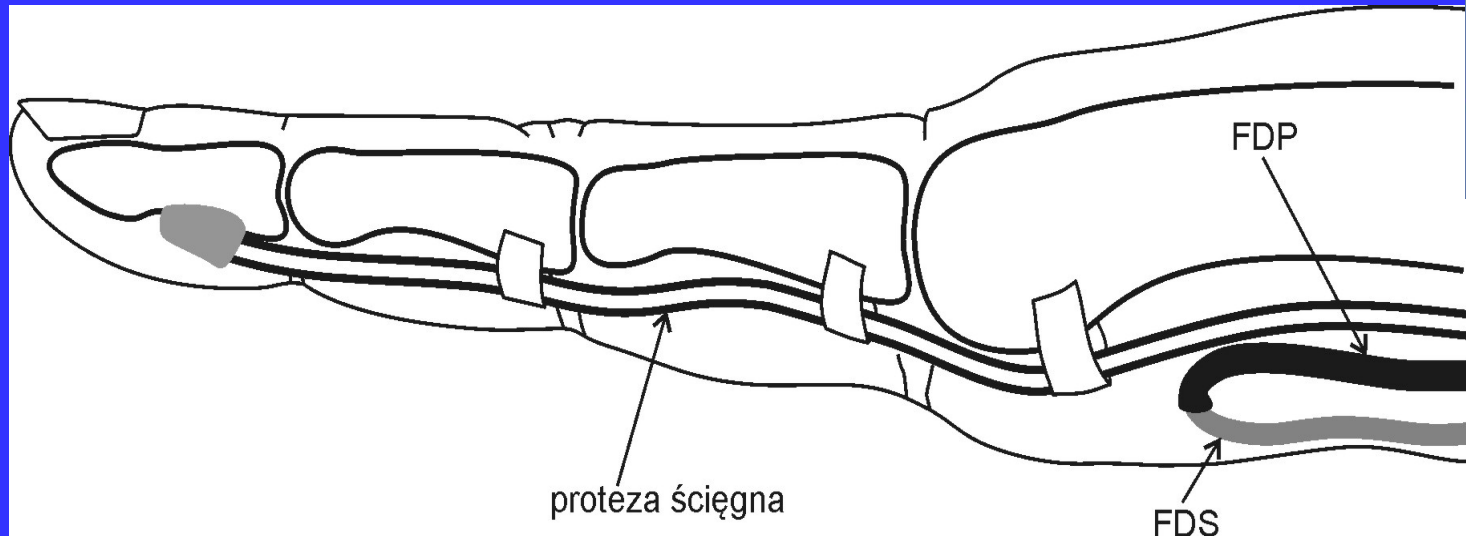
1 – the loop of the prosthesis,

2 – the shaft of prosthesis




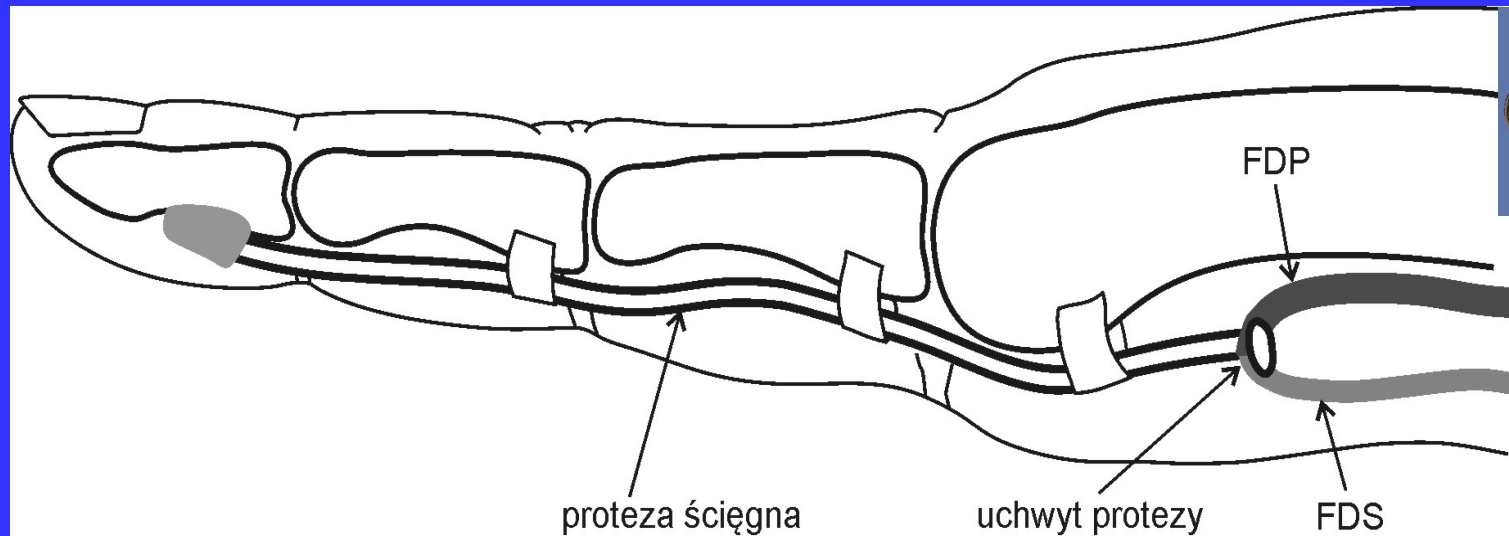
The idea of FDP/FDS tenotomy and loop connection according to Paneva-Holevitch - 1965

Paneva – Cholevitch E.: Two – stage plasty in flexor tendon injuries of the fingers within the digital synovial sheath. (Report). Acta Chir. Plast., 1965, 7, 112 – 124.



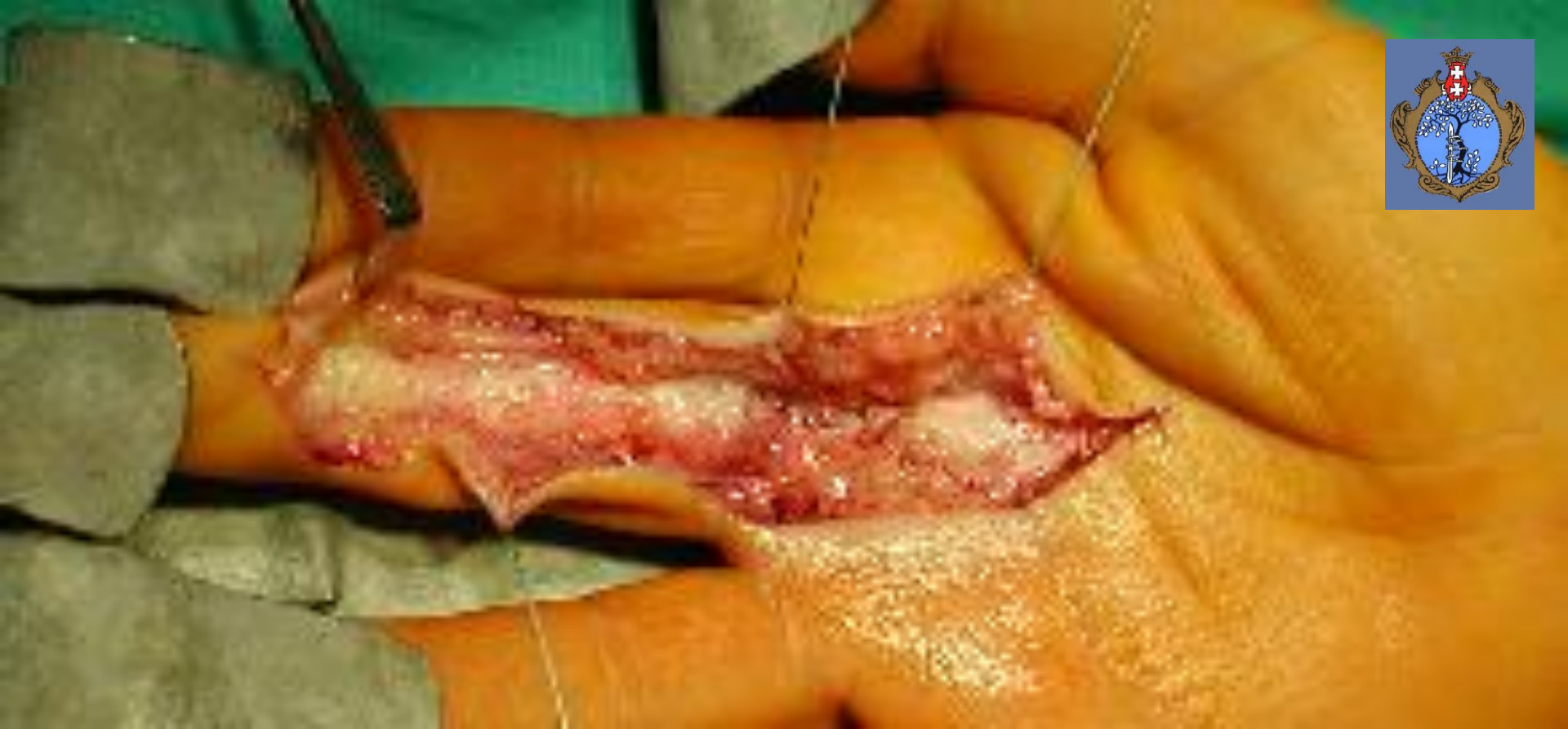
The idea of FDP/FDS tenotomy and loop suture using tendon prosthesis according to Kessler - 1972

Kessler F. B.: Use of a pedicled tendon transfer with a silicone rod in complicated secondary flexor tendon repairs. J. Plast. Reconstr. Surg., 1972, 49, 439 – 443.

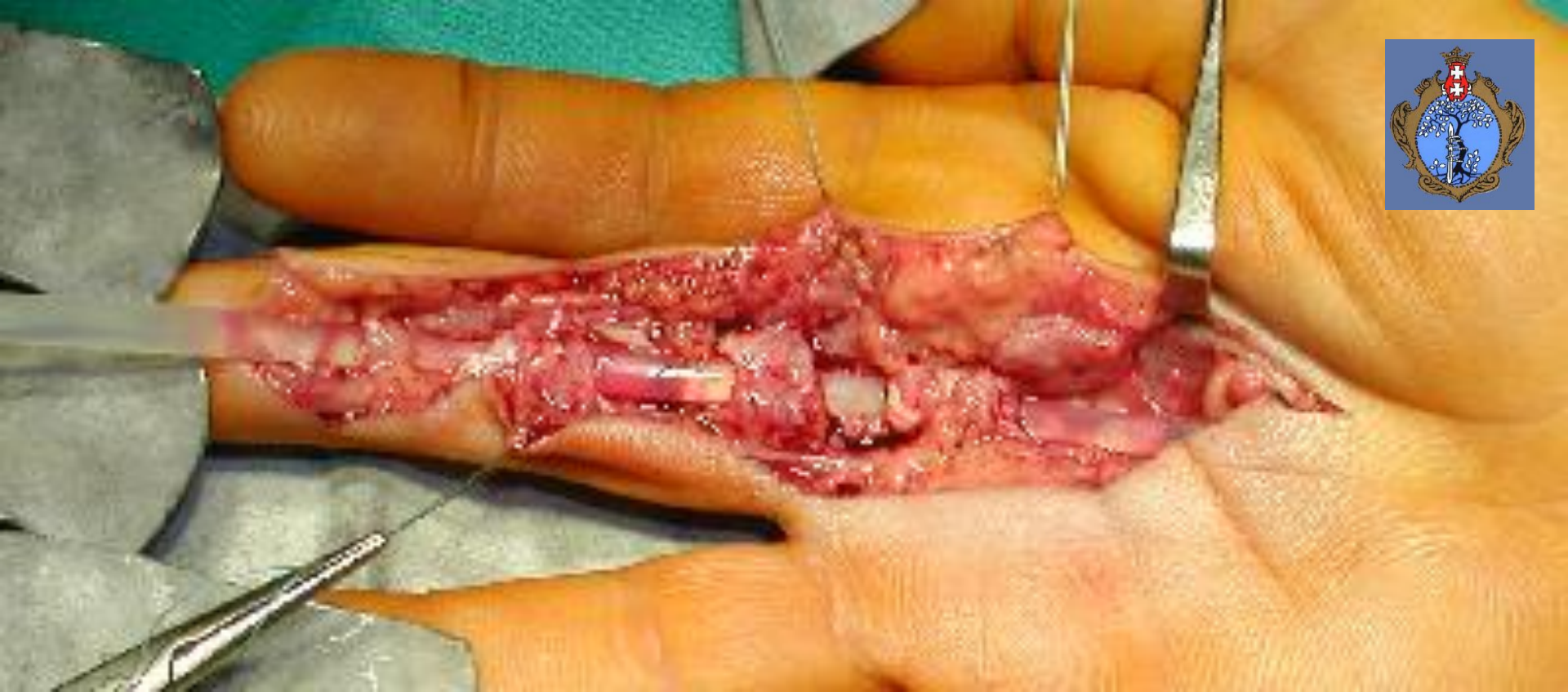

The idea of FDP/FDS tenotomy and loop connection using author's original tendon prosthesis – 2008

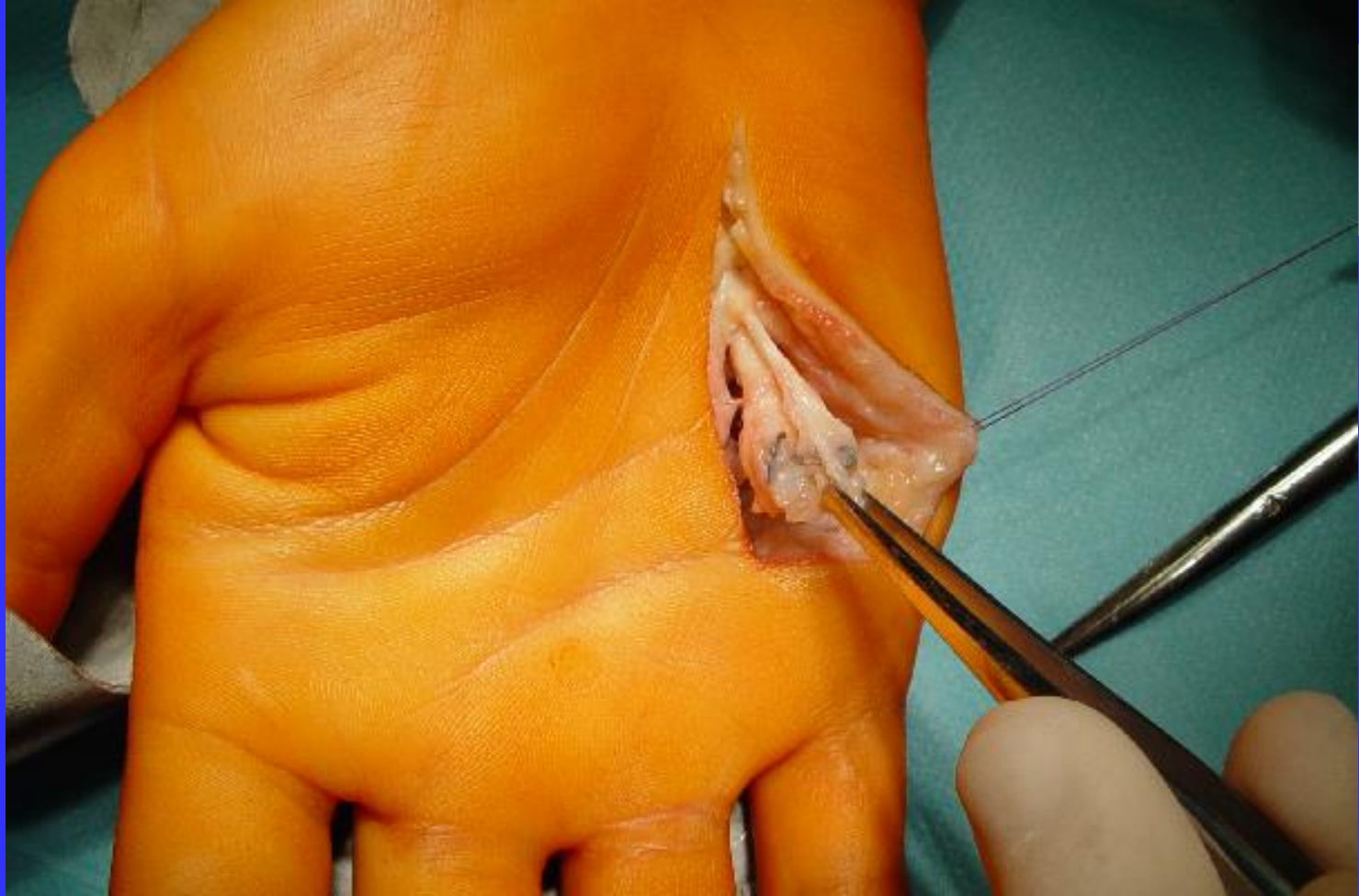

Mazurek T., Lorczyński A., Łabuć A.: Use of superficial flexor muscle of fingers as a transplant for reconstruction of inveterate damage of deep flexor muscle of fingers using tendon prosthesis – preliminary report. J. Orthop. Trauma Surg. Rel. Res. 2008, 11, 3, 32-36.



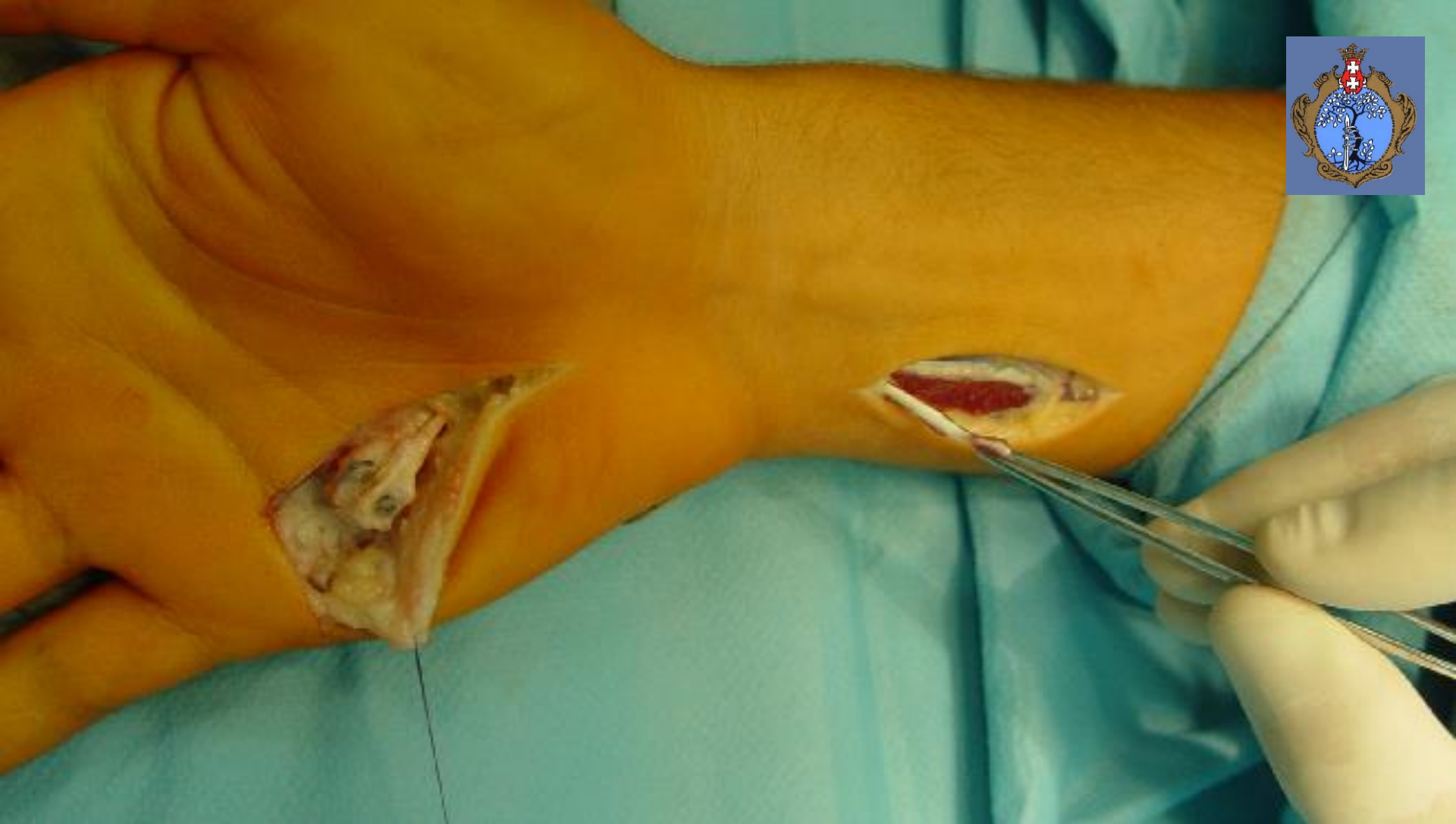First Stage - the Bruner approach to tendon's sheath



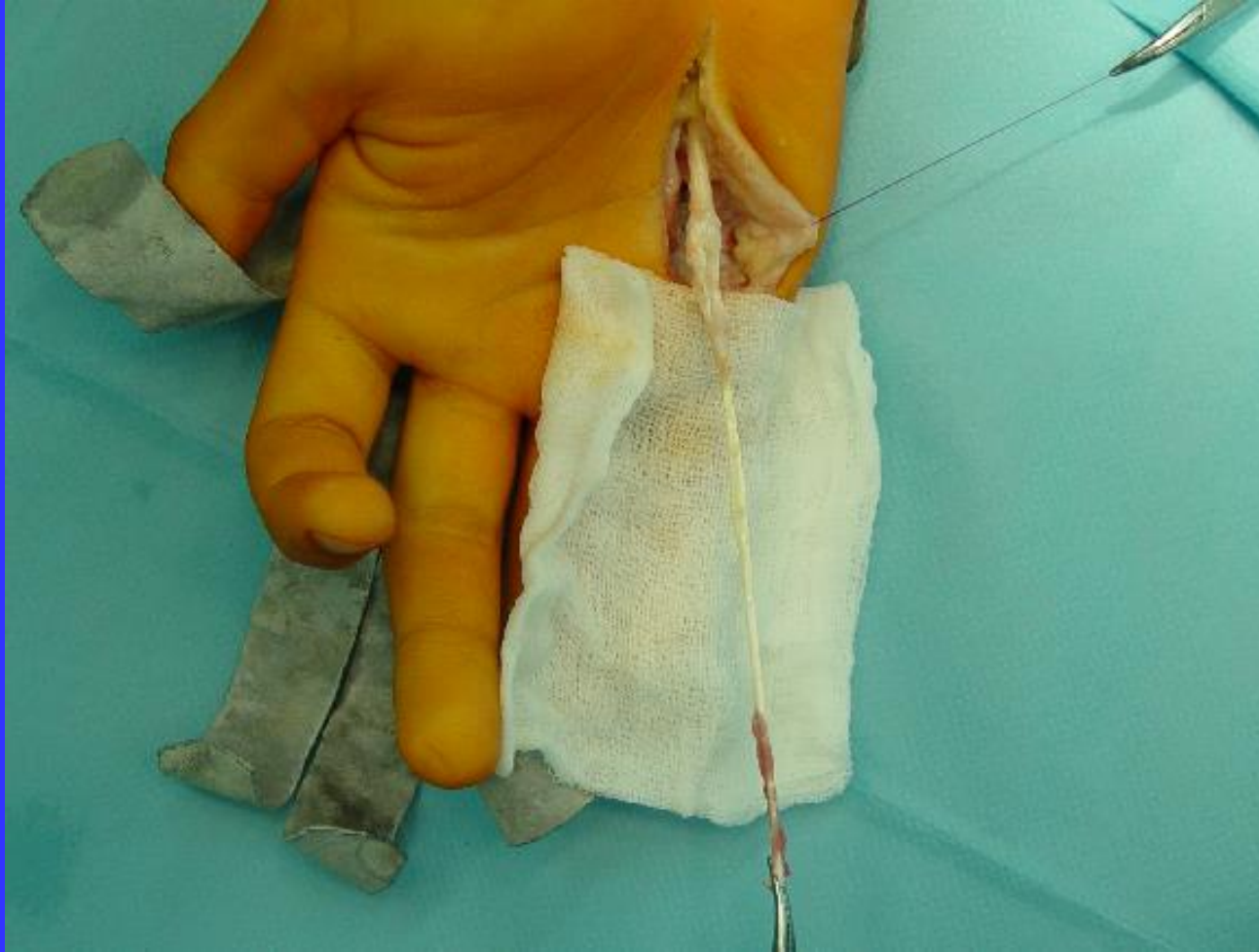
First stage - the introduction of tendon prosthesis preserving the A2 and A4 annular ligaments and creating the FDS/FDP connection on the loop's prosthesis



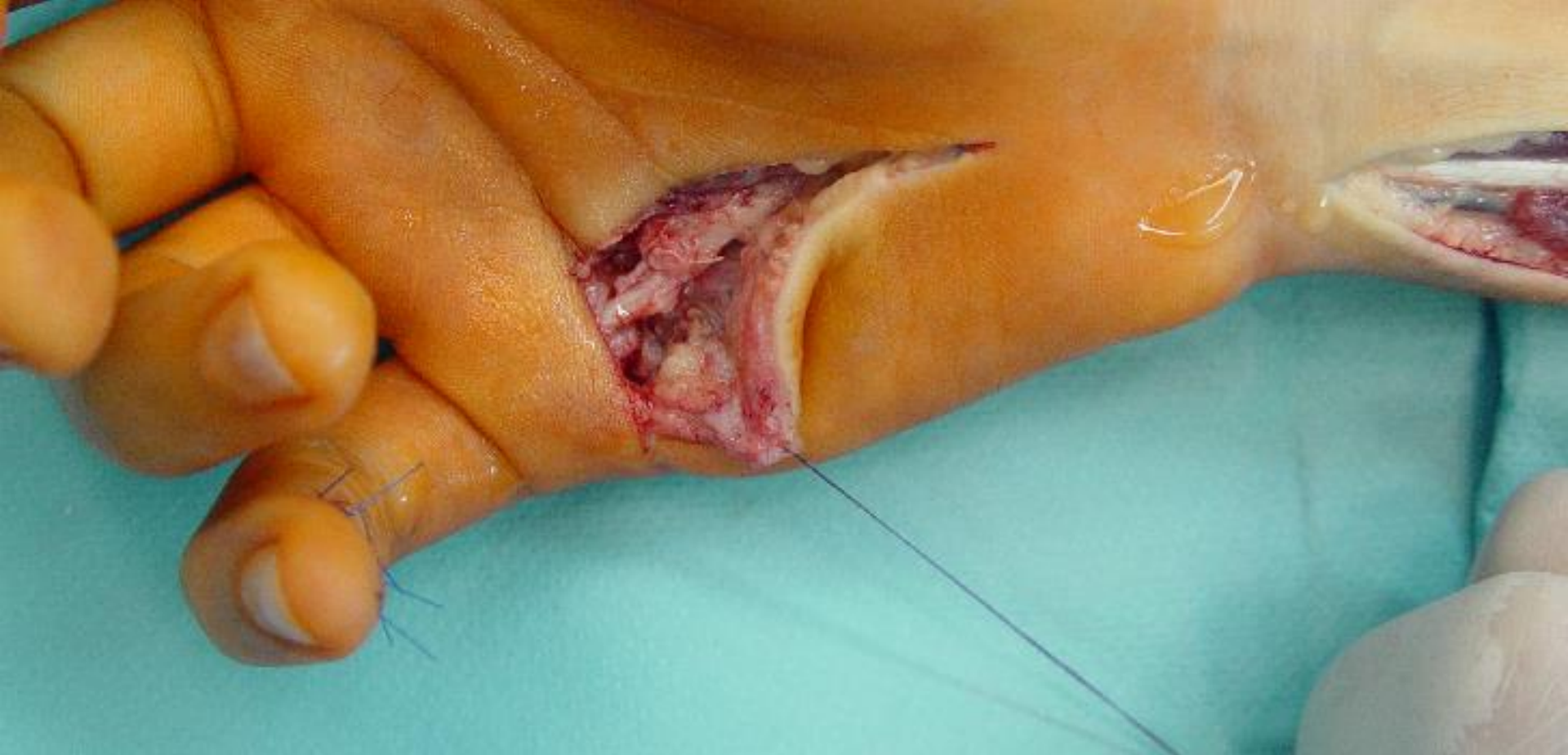**Second stage - dissecting the FDP/FDS connection
and the prosthesis loop**



Second stage - the FDS tenotomy on the forearm



Second stage - the FDS/FDP connection ready to use as a tendon graft



The completed second stage reconstruction procedure before skin closure



Advantages of the author's original tendon prosthesis

1. Using intra-synovial tendon graft (FDS) is better than extra-synovial tendons (PI, Pt)

- healing without necrosis

Gelberman R. H., Siegel D. B., Woo S. L.: Healing of digital flexor tendons: Importance of the interval from injury to repair: A biomechanical, biochemical, and morphological study in dogs. J. Bone Joint. Surg. Am. 1991, 73, 66-75.

- strong biomechanical properties of FDS in comparison to PI, Pt allows active rehabilitation protocol

Mazurek T., Strankowski M., Ceynowa M, Ročlawski M.: Tensile strength of a weave tendon suture using tendons of different sizes. Clin. Biomech. 2011, 26, 415-418.

Advantages of the author's original tendon prosthesis

2. Use of the loop for FDS /FDP connection allows

- „mobilization” of the prosthesis
- tension of the FDS/FDP muscles
- modelling of the FDS/FDP connection

Mazurek T., Lorczyński A., Łabuć A.: Use of superficial flexor muscle of fingers as a transplant for reconstruction of inveterate damage of deep flexor muscle of fingers using tendon prosthesis – preliminary report. J. Orthop. Trauma Surg. Rel. Res. 2008, 11, 3, 32-36.

Study group – 17 patients



Range of motion of finger –
Buck Gramco, TAM, Strickland scale

Results


The mean total active motion - (TAM) - 196,6°
The mean total extension deficit - 35°
The mean total active flexion - 231,6°



Results - Nerve function

- two points discrimination


14 patients - excellent
2 patients - satisfactory
2 patients - poor



- Semmes-Weinstein

monofilament

14 patients - 2.83
1 patient - 3.61
2 patients - 4.31
1 patient - 6.65





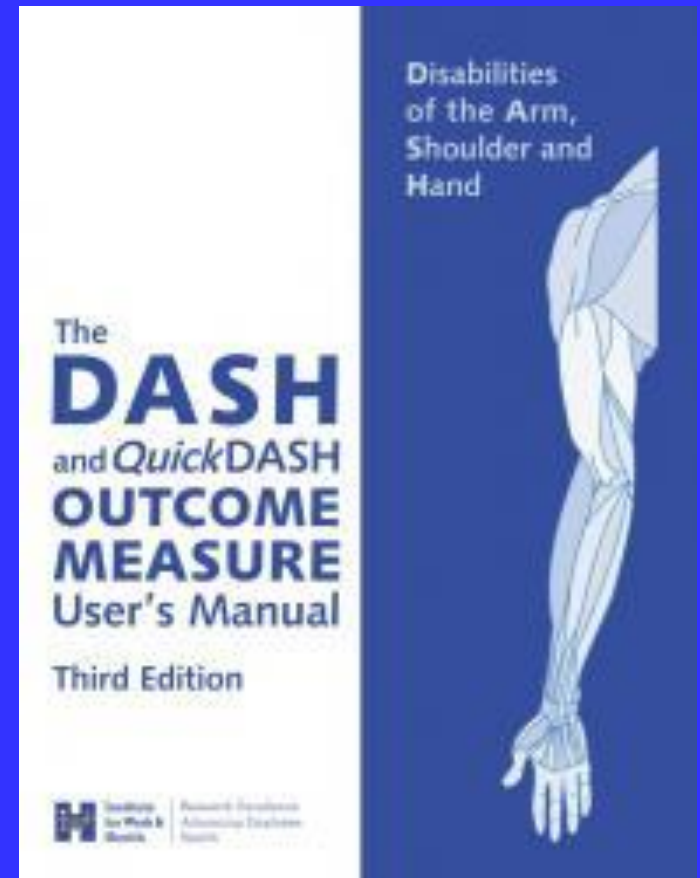
DASH questionnaire Results

From 3 to 33

16/18 patients from 3 to 11

1 patients - 27

1 patients - 33





Conclusions

- 1. The obtained results encourage the use of original flexor tendon prosthesis**
- 2. Nerve lesion that accompanies the initial tendon lesion worsens the treatment results even after a long follow-up period**
- 3. The DASH questionnaire shows that a decreased function of the reconstructed tendon is seldom the cause of major patient's complaints**

VIII Zjazd Polskiego Towarzystwa Chirurgii Ręki

10-12 września 2015 Gdańsk
www.chirurgiareki2015.pl



- Polska Filharmonia Bałtycka im. Fryderyka Chopina *w Gdańsku*
- Sala Koncertowa na 950 osób
- Sala Kameralna Zielona na 200 osób
- Sala Konferencyjna Jazzowa na 180 osób
- Sala Konferencyjna Dębowa na 100 osób
- Sala Prasowa na 45 osób
- Sala Nad Motławą na 60 osób



