

CARPAL DISLOCATIONS AND FRACTURES

A.I. Volotovski

A.V. Martinovich, Y.R. Mikhnovich

***Belarusian State Medical University
Republican Centre of Hand Surgery, Clinic #6
Minsk, Belarus***

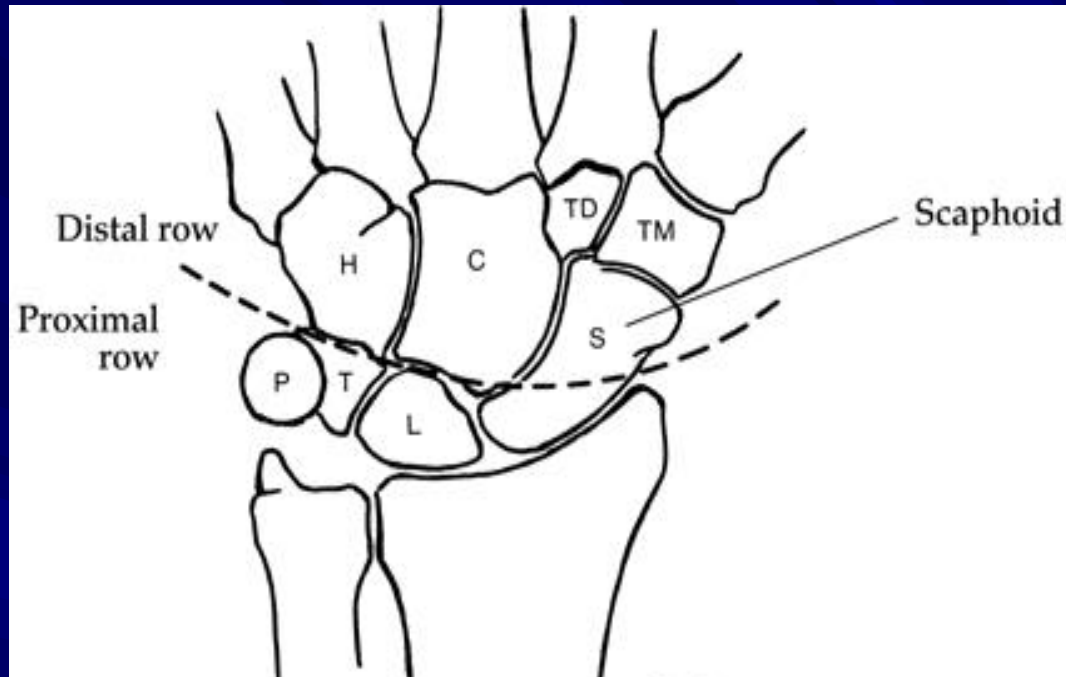
March 13, 2015, Poznan

Introduction

- Of all carpal dislocations, perilunar dislocations make as much as 90%
- Perilunate dislocations are comparatively uncommon and account for only about 10% of all carpal injuries
- Carpal dislocations combined with the wrist bones fractures represent a clinical problem which is the most difficult to diagnose and treat
- Results of treatment of acute carpal dislocations are satisfactory if the patient is seen early

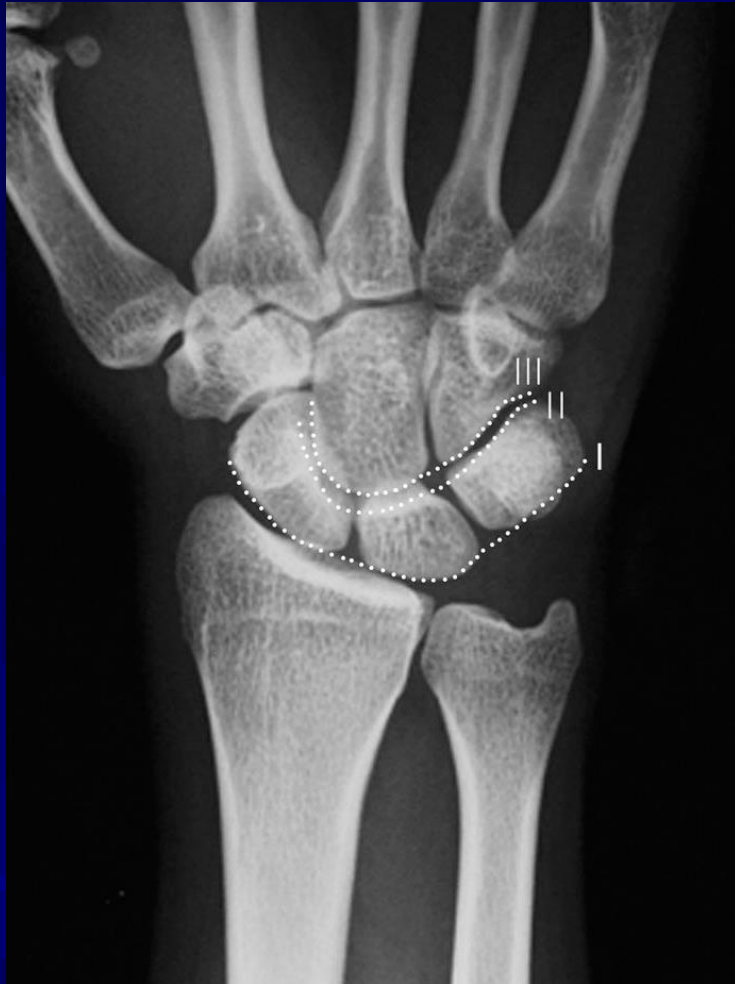*Dobyns and Linscheid, 1984; Inoue and Imaeda, 1997;
Inoue and Kuwahata, 1997*

Basic Architecture of the Wrist



- The carpal complex is divided into a proximal and a distal row of carpal bones
- The scaphoid is half in the proximal and half in the distal row of carpals, thus serving as a link between them
- The lunate of the proximal row of carpal bones is most strongly associated with the powerful combination of the radius

Basic Architecture of the Wrist



Gilula sign - three normal carpal arcs on a posteroanterior view - are normally smooth and congruent

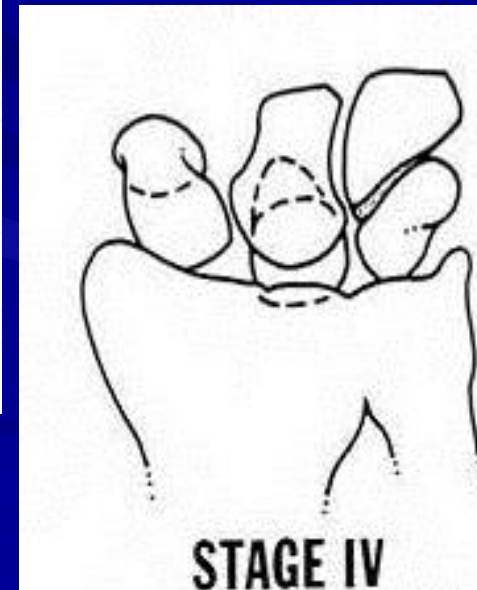
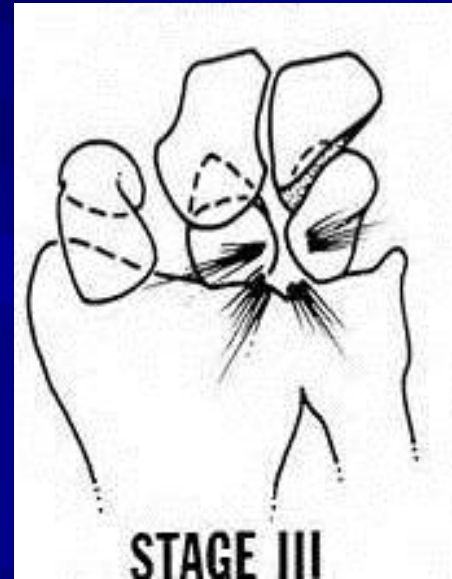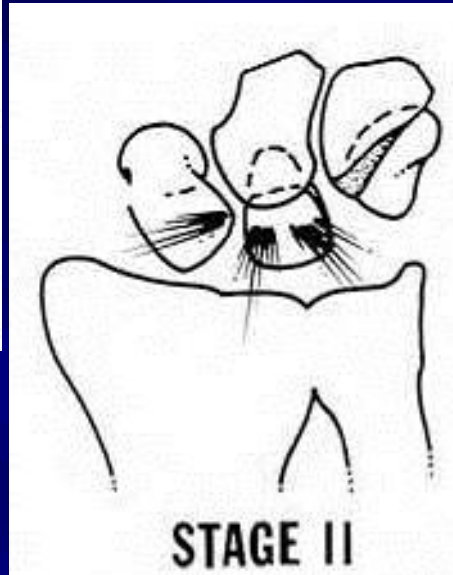
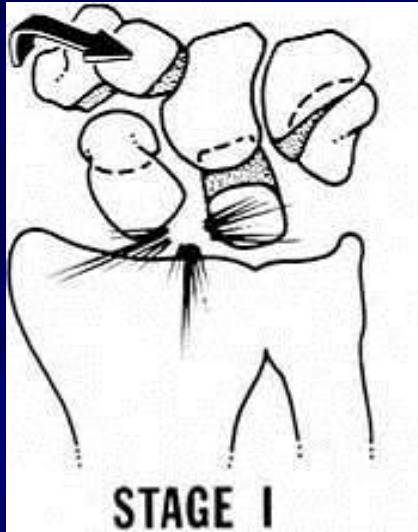
- Arc I is the proximal convex curvature of the proximal carpal row
- Arc II is the distal concave curvature of the proximal carpal row
- Arc III is the proximal convex curvature of the capitate and hamate

A disrupted or broken arc may indicate ligamentous injury, dislocation of the carpal bones, or a carpal bone fracture

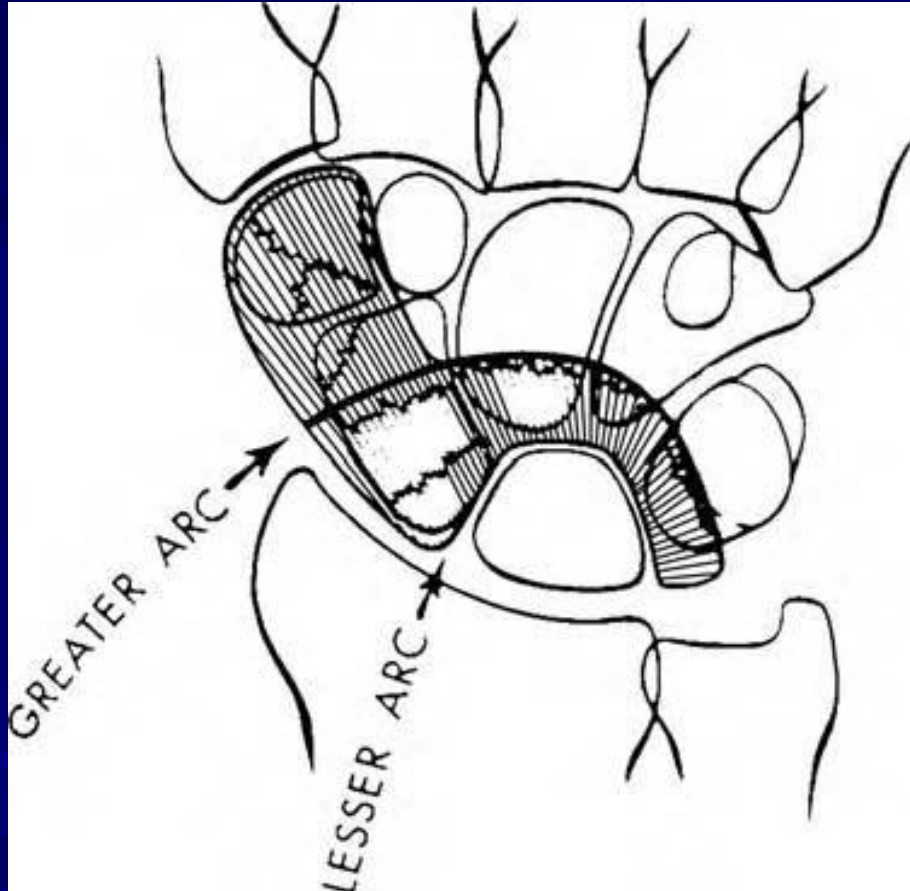
Epidemiology and Mechanism of Injury

- Occurs in young patients with strong bone that are involved in relatively high-energy injuries
- Occurs with forceful wrist hyperextension, ulnar deviation and intercarpal supination
- A disruption of ligamentous connections between the lunate and other carpal bones and the radius, is the most common form of carpal dislocation
- The spectrum of injury observed reflects the injury forces and failure through ligament or bone at each anatomical area

Mayfield's stages



Classification by Mayfield



- Lesser arc injuries
- Greater arc injuries
- Variant injuries
- Radiocarpal dislocations and fracture dislocations

Classification by Watson and Jeffrey

- Perilunate dislocation,
- Radiocarpal dislocation,
- Midcarpal dislocation
- Axial-carpal dislocation
- Isolated carpal injuries

Classification by Cooney and colleagues

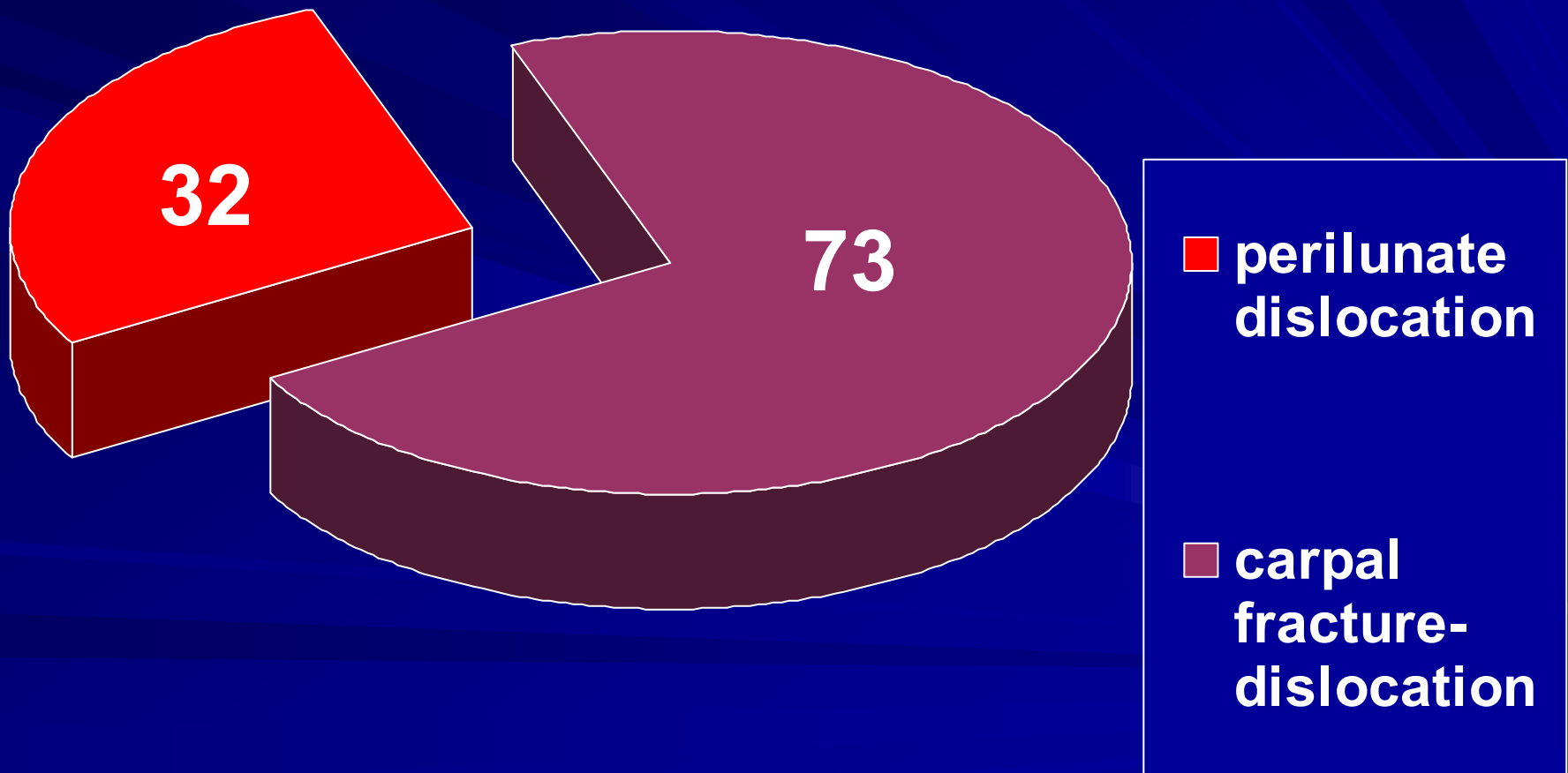
- Dorsal perilunate dislocations, or lesser arc injuries
- Transcarpal fracture dislocations, or greater arc injuries
- Radiocarpal dislocations
- Longitudinal or axial dislocations
- Isolated carpal bone dislocations

Aim of study

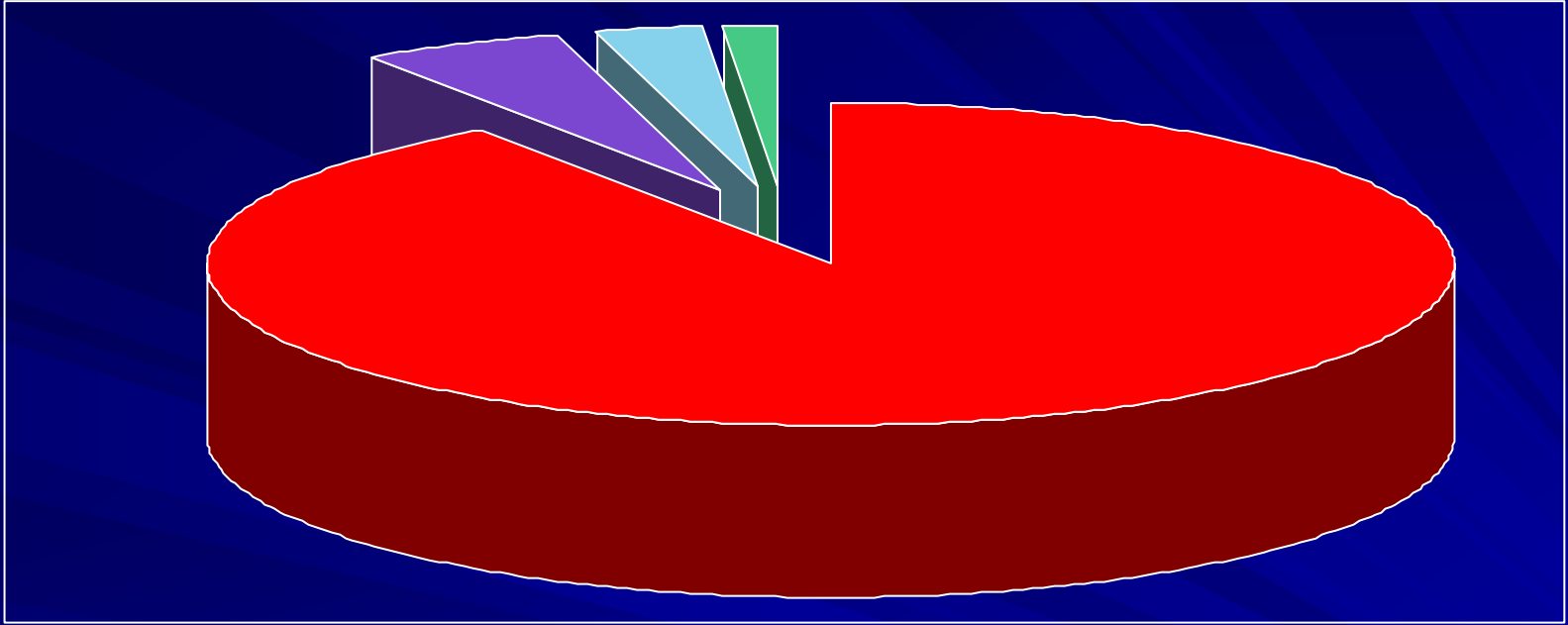
- To present features of current methods to diagnose carpal dislocations combined with the wrist bones fractures, as well as to reflect the most rational treatment approaches depending on the type and remoteness of injury

Patients and Methods

Subdivision of carpal dislocations:



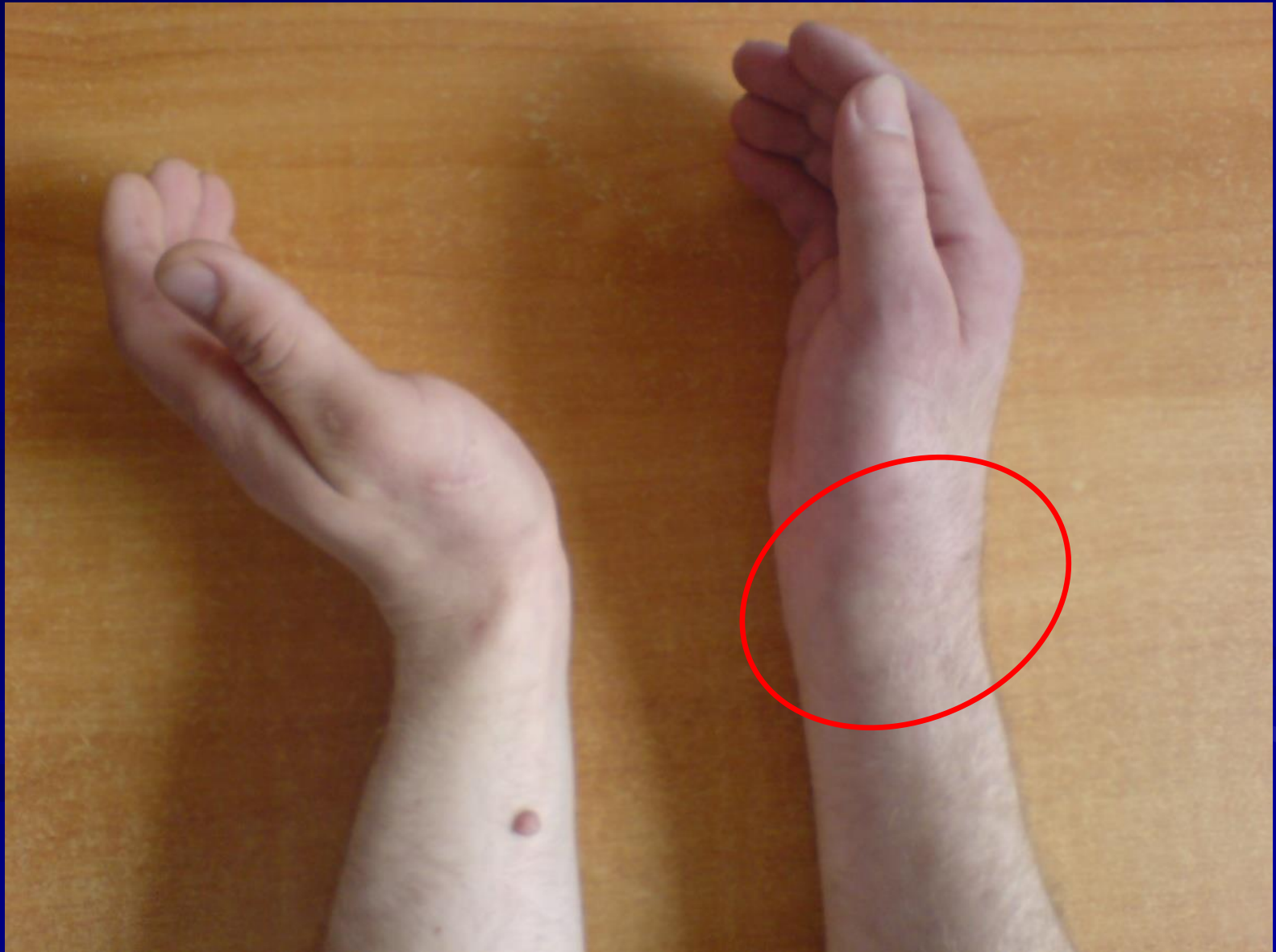4 2 1



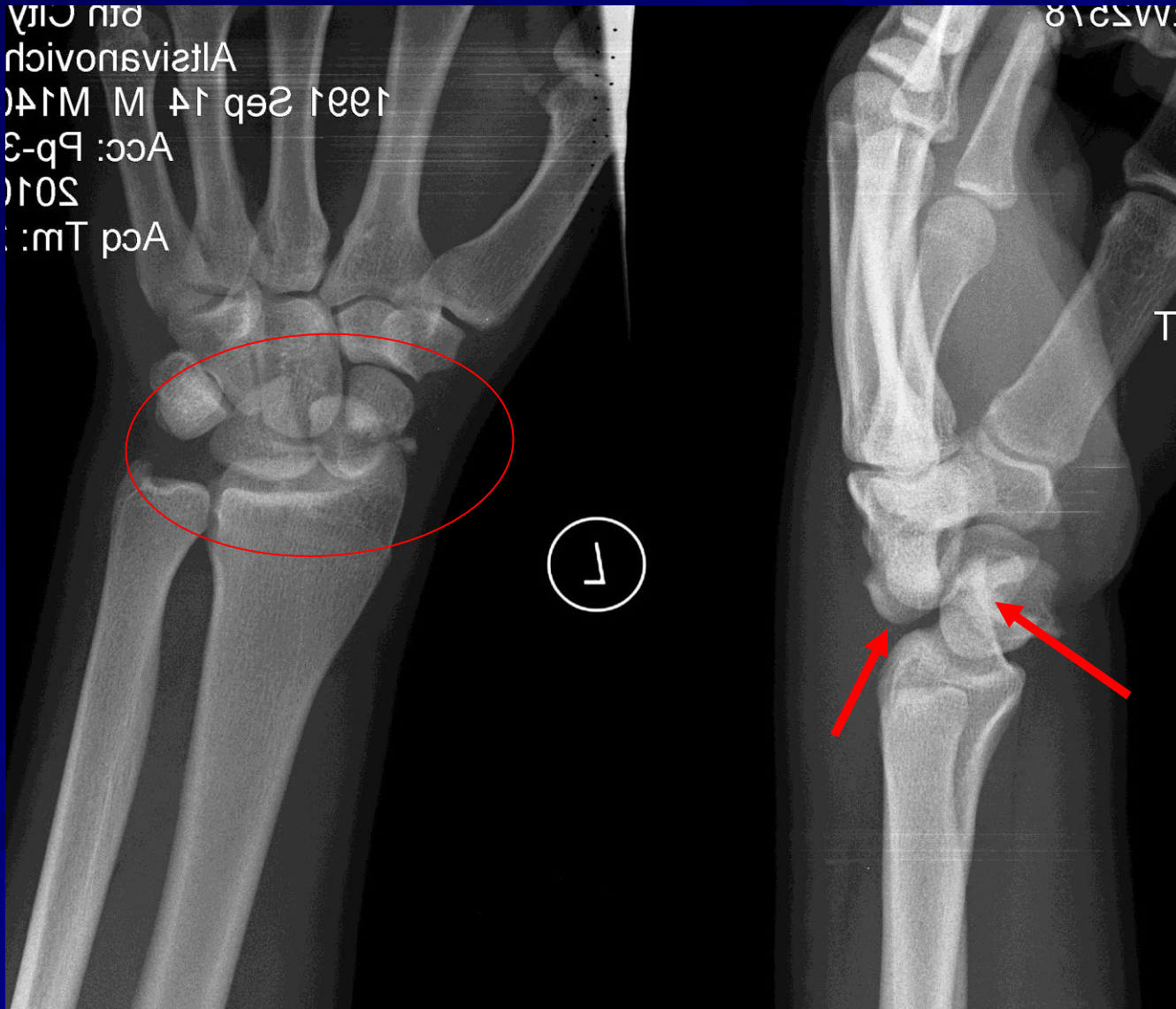
67

- Scaphoid
- Triquetrous
- Lunate
- Capitate

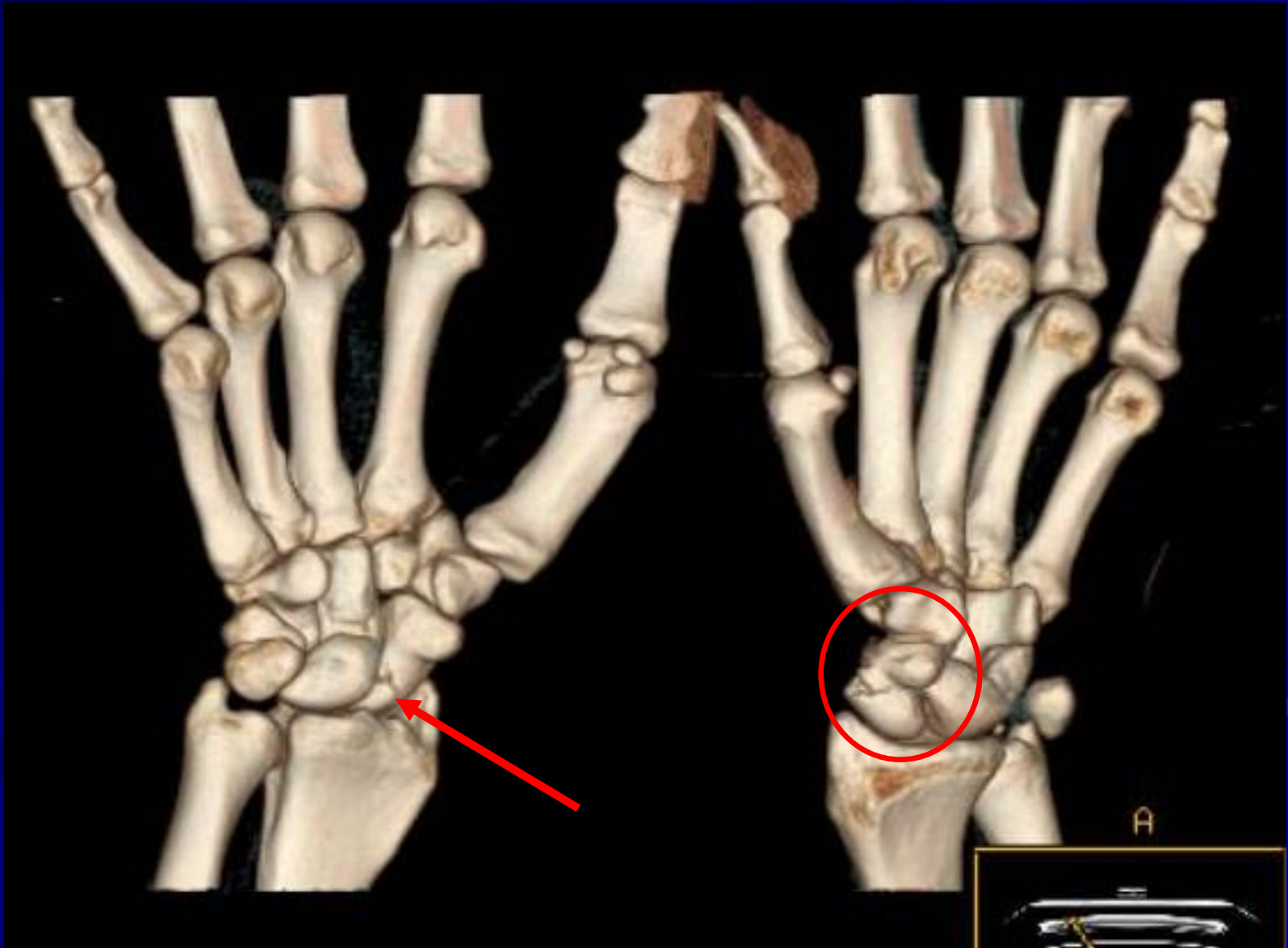
Clinical examination



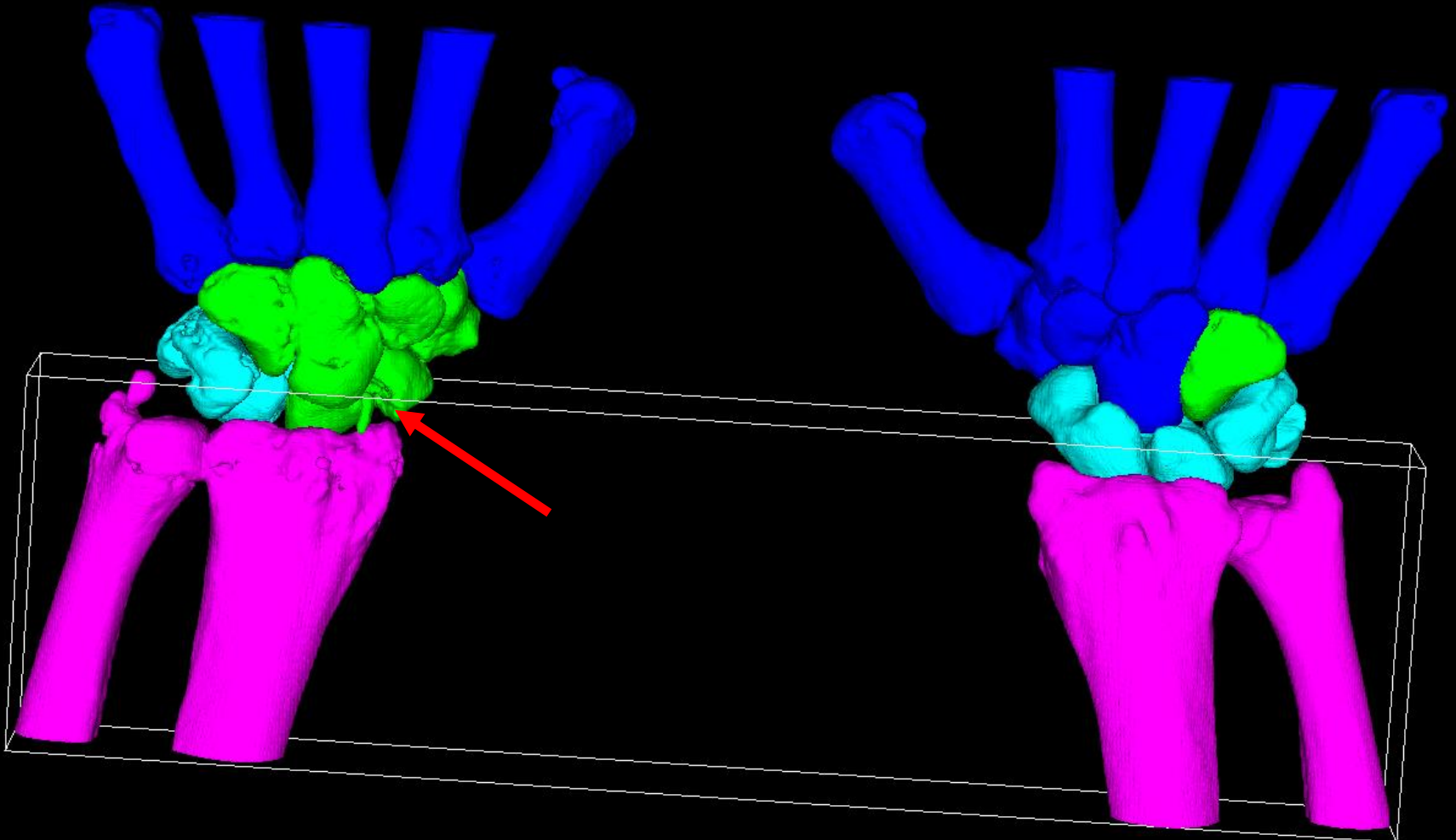
Standard views

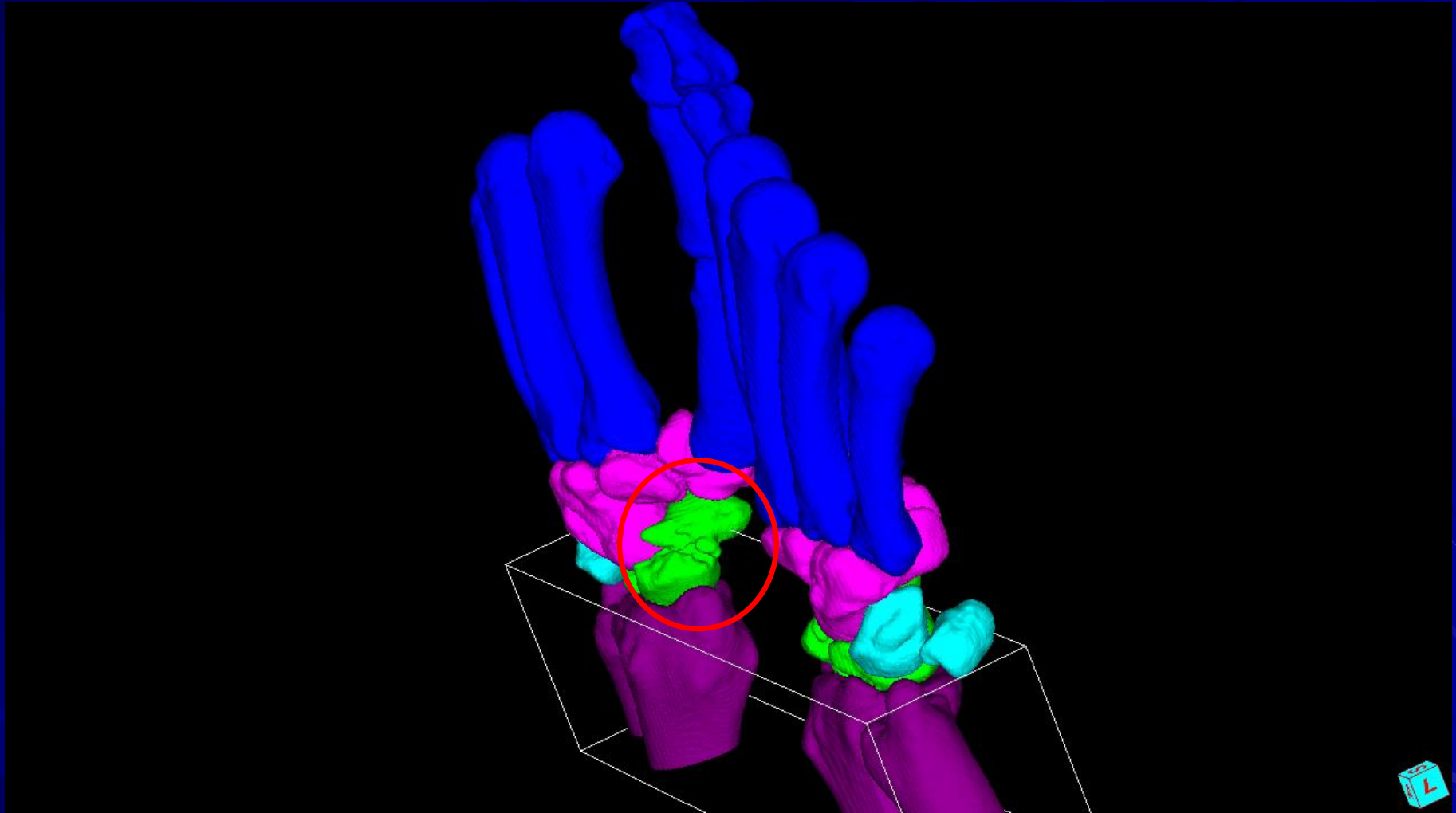


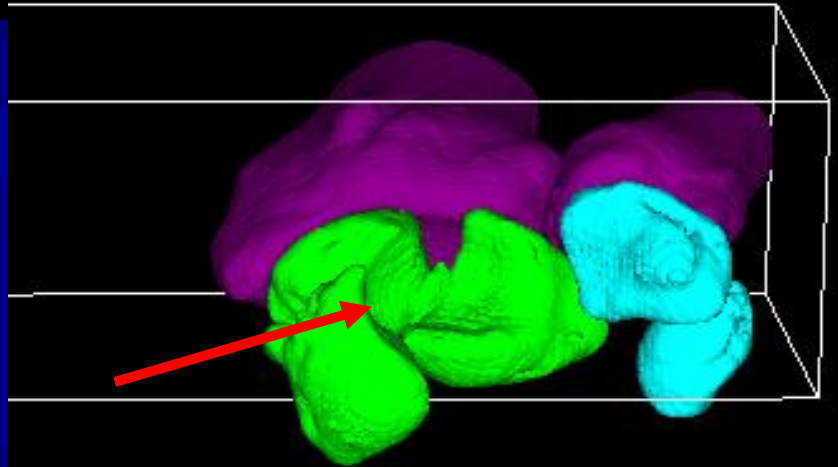
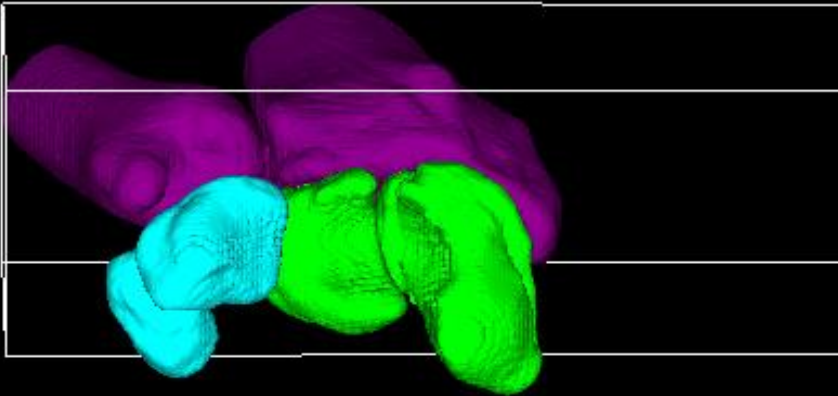
CT 3D-reconstruction



Computer program of visualization







Treatment

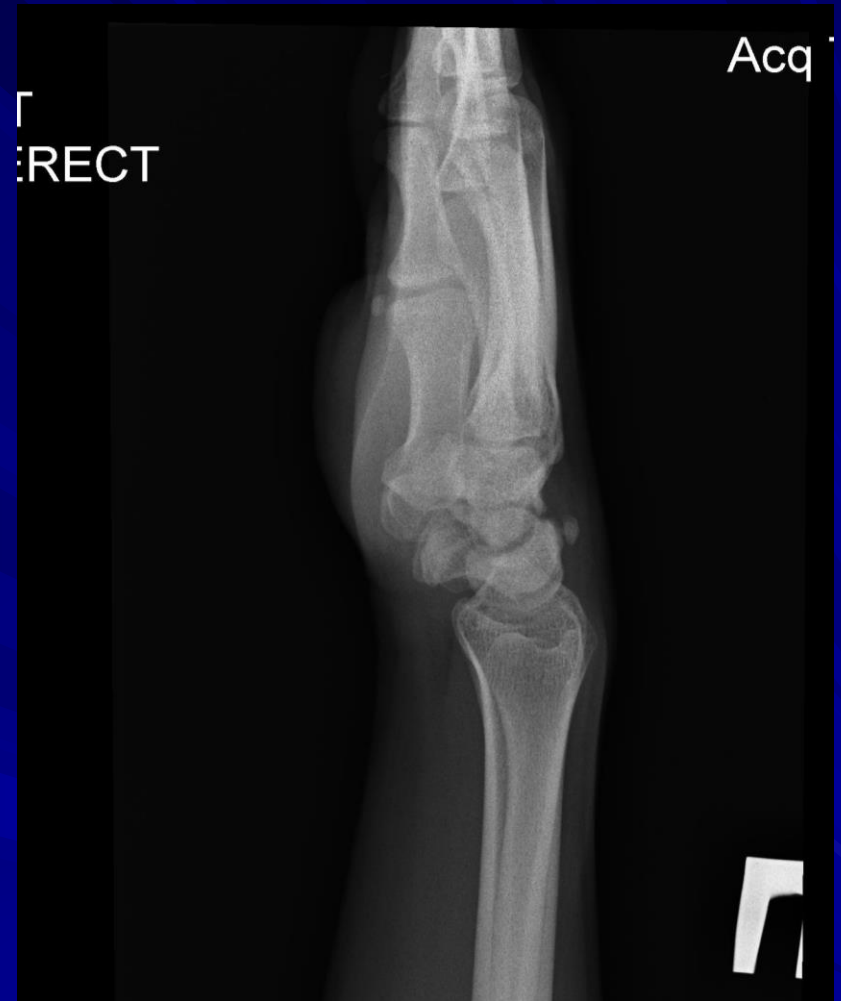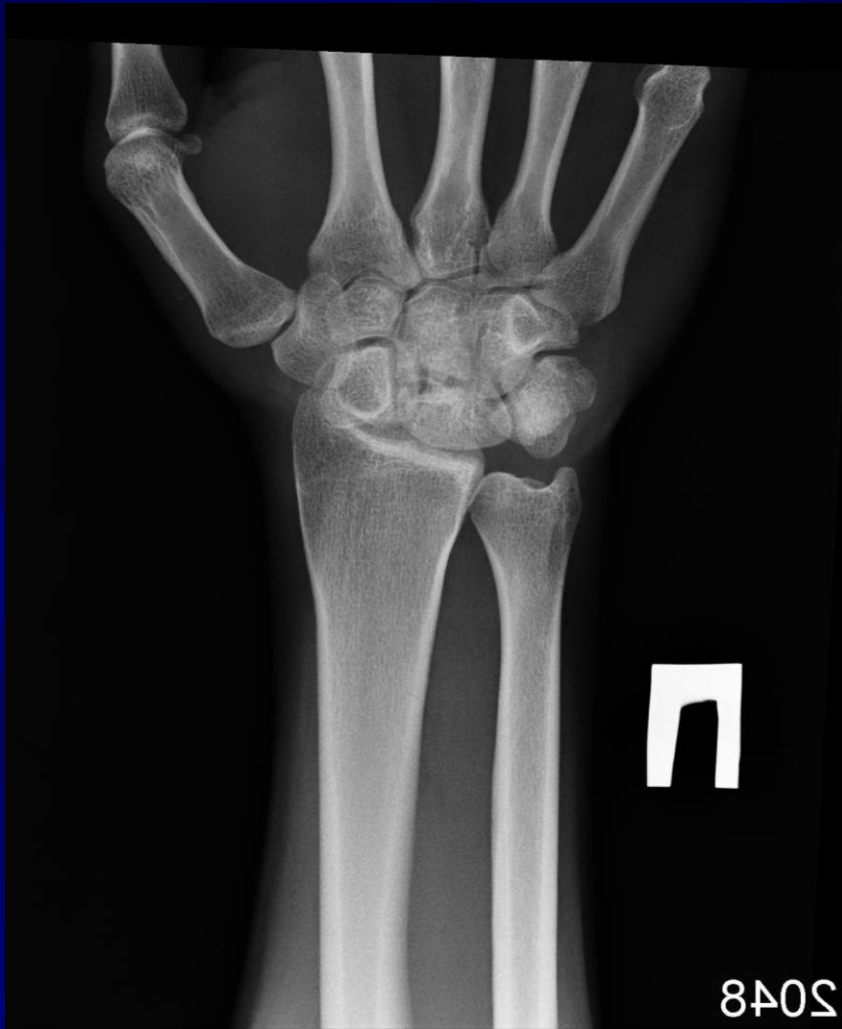- Surgery was the main method of treatment in most patients with carpal dislocations
- The selection of the method of operating on the carpal dislocations with fractures depends on components of the injury, its localization and terms after the injury
- Immobilization with a plaster of Paris bandage from 4 to 6 and more weeks in the postoperative period

Treatment tactics

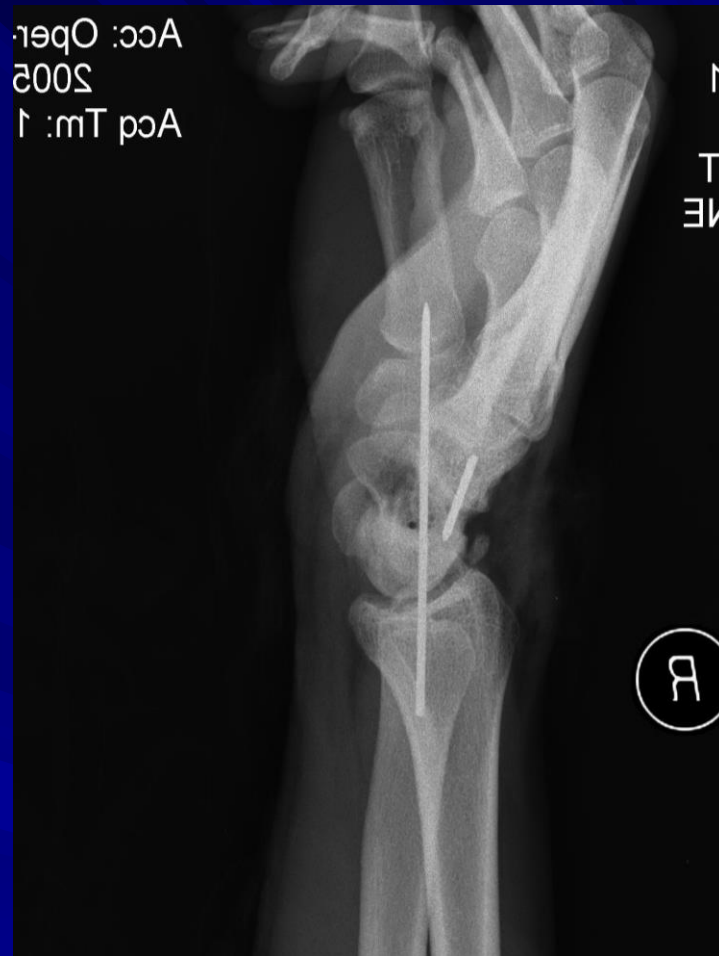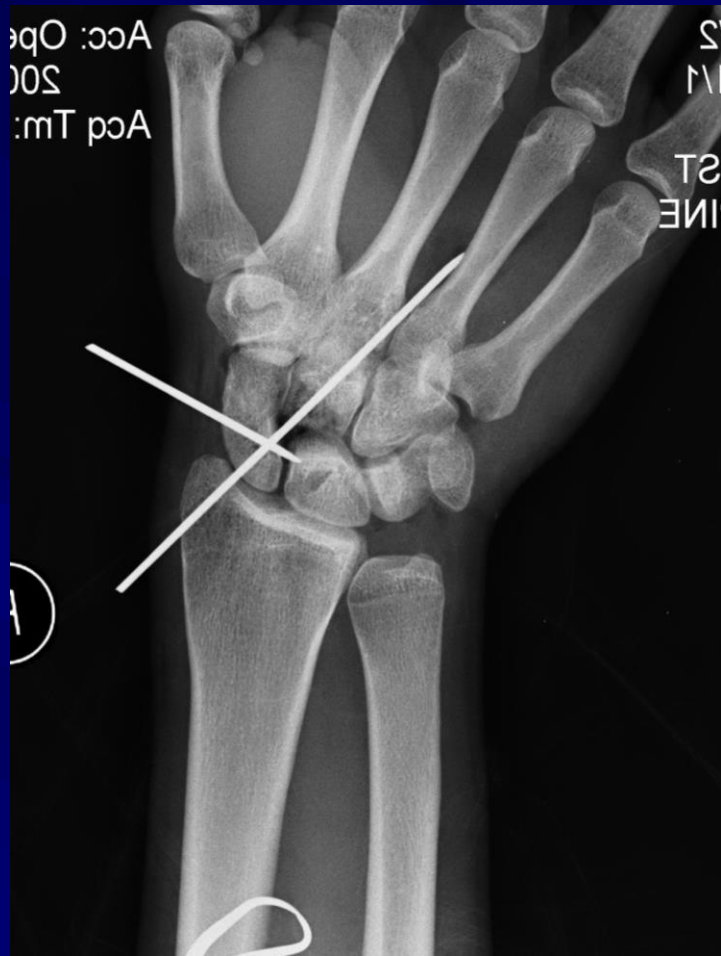
- We adhere to the idea of using the principles of treating intraarticular injuries
- In case there was no effect of a closed elimination of the fresh and nonfresh carpal injury we use a delayed operative intervention

One-step surgical treatment

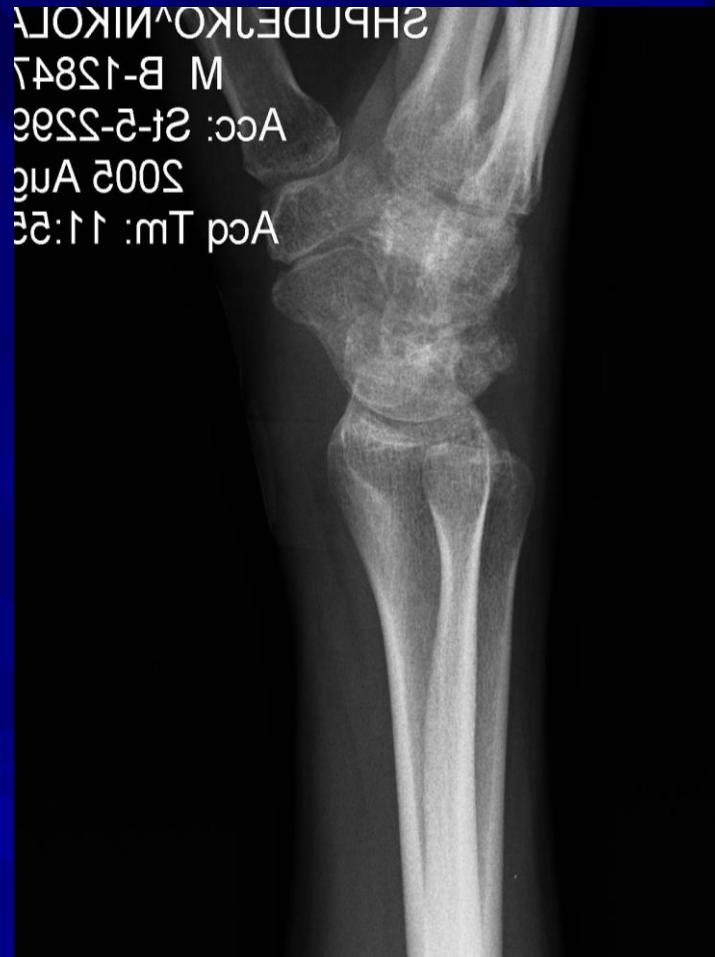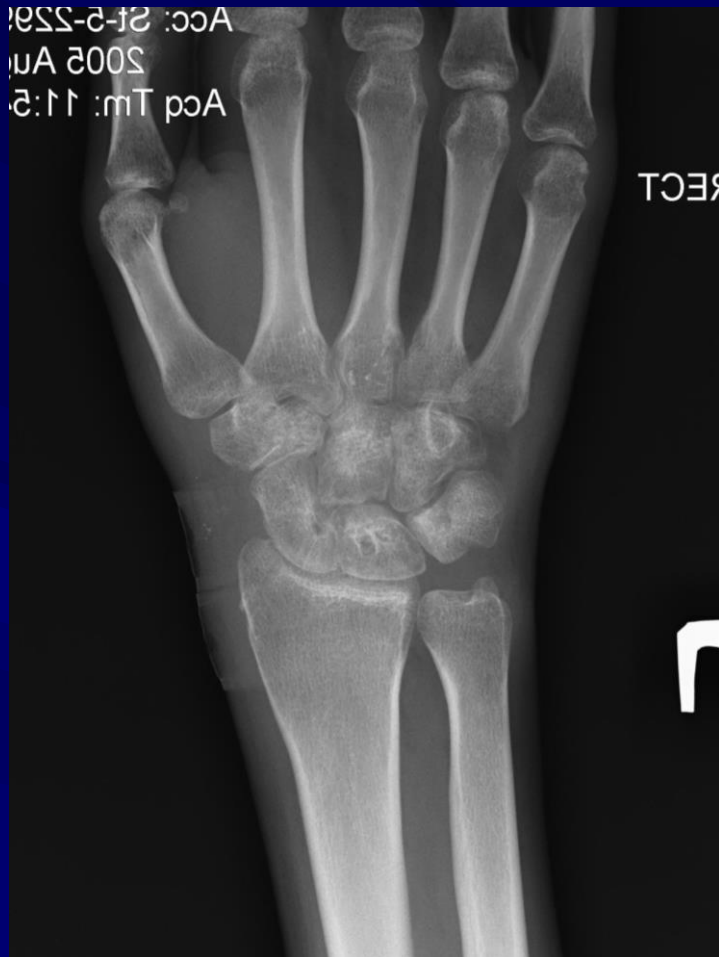- In the early period after injury we use a one-moment open reduction of the dislocation; if necessary, we use an open reposition of bone fragments osteosynthesis with metal constructions. If indicated, we restore the injured ligaments stabilizing the wrist elements.



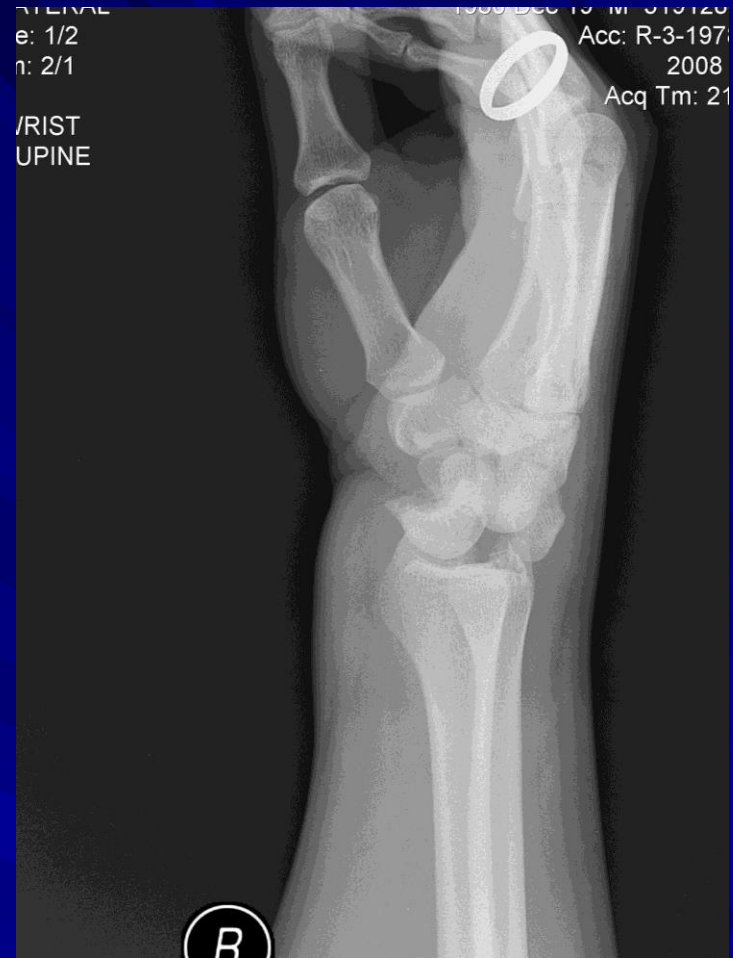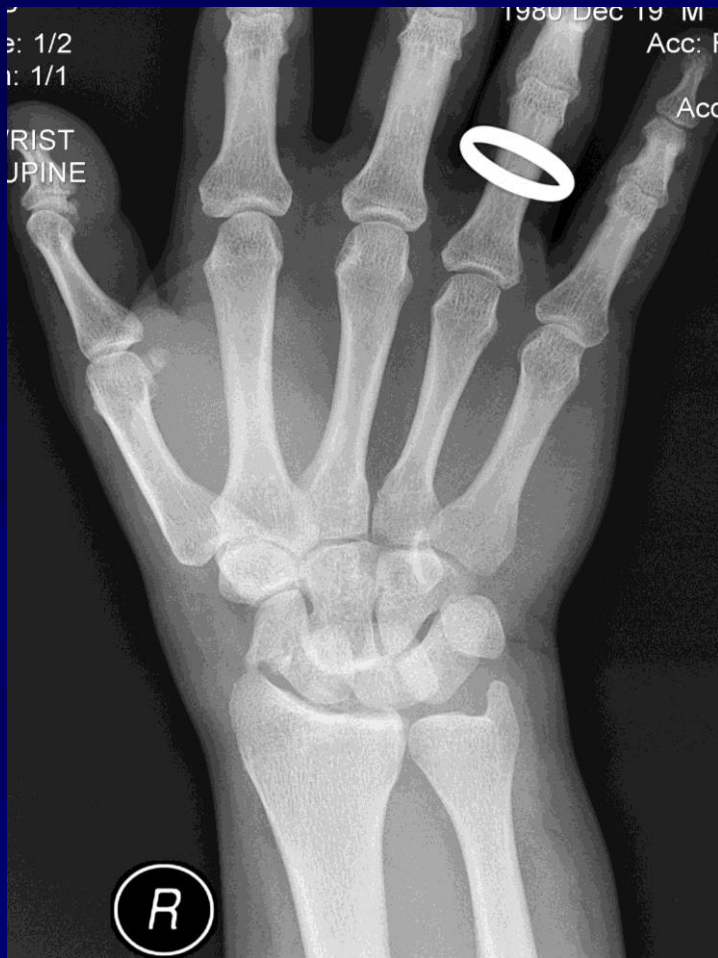Patient S., 19 years old, student, transcapitate perilunate fracture-dislocation of the wrist



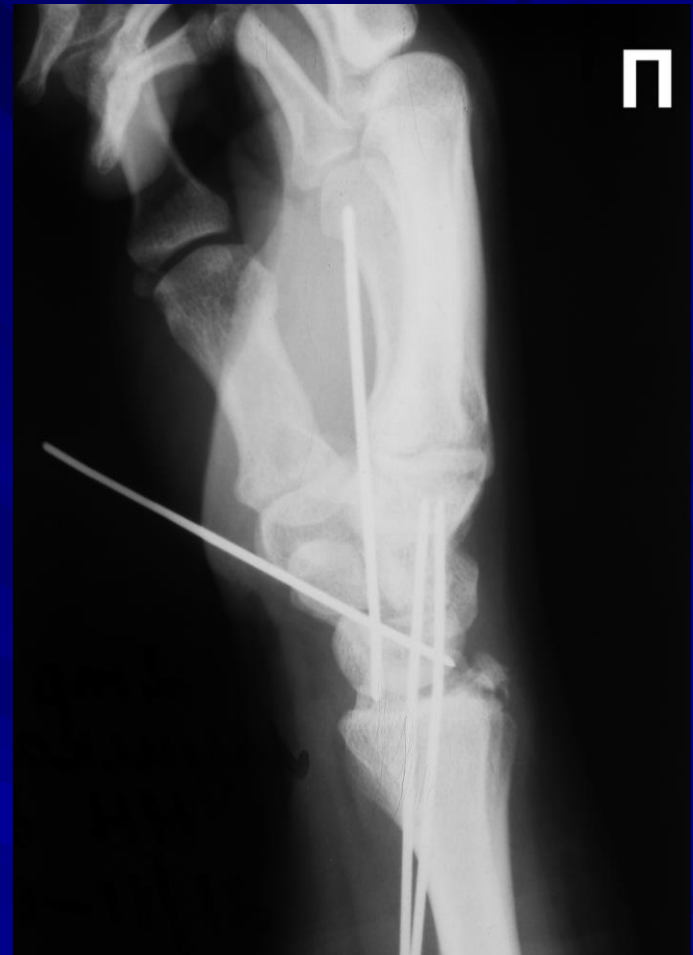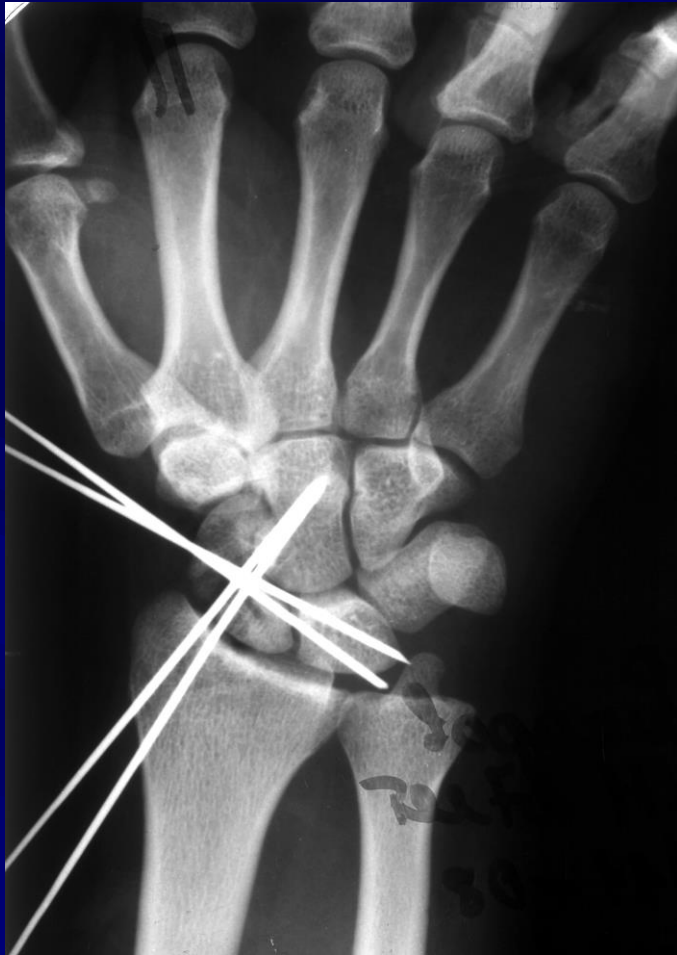After open reduction and scapho-lunate reconstruction



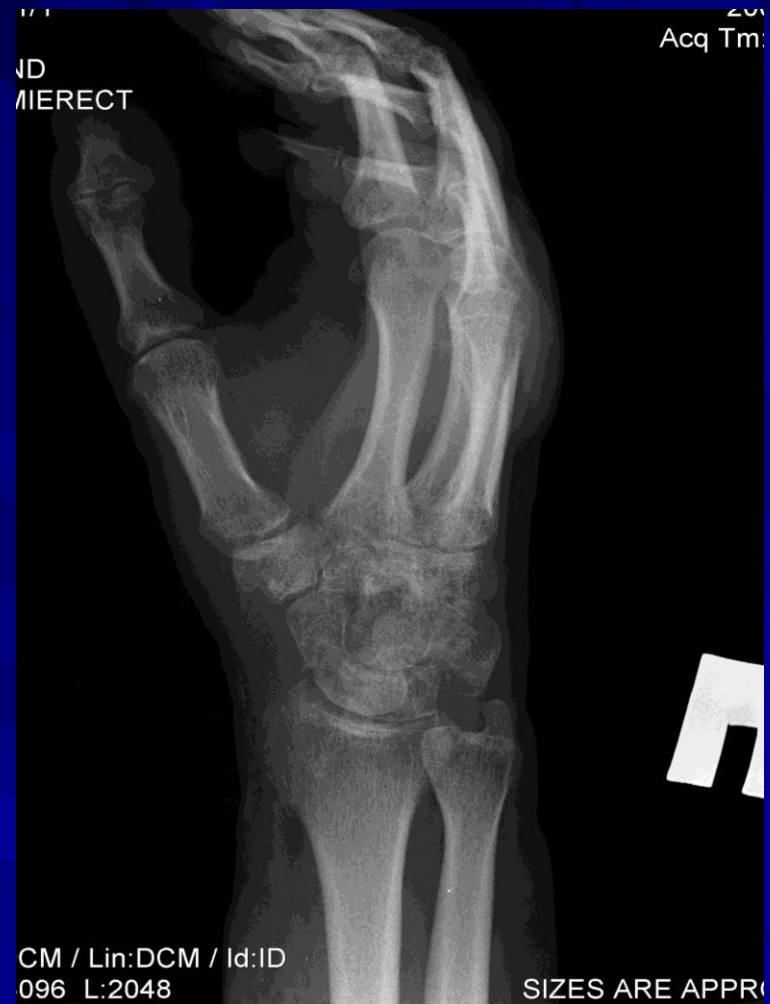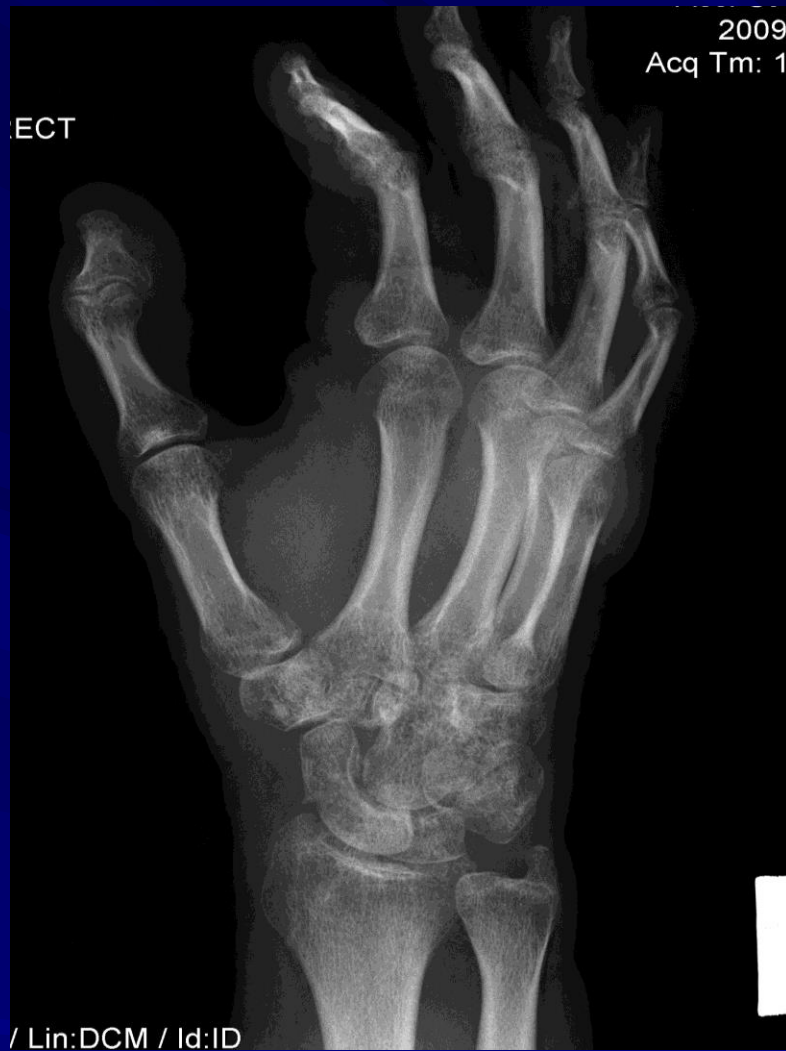Result 2 months after operation



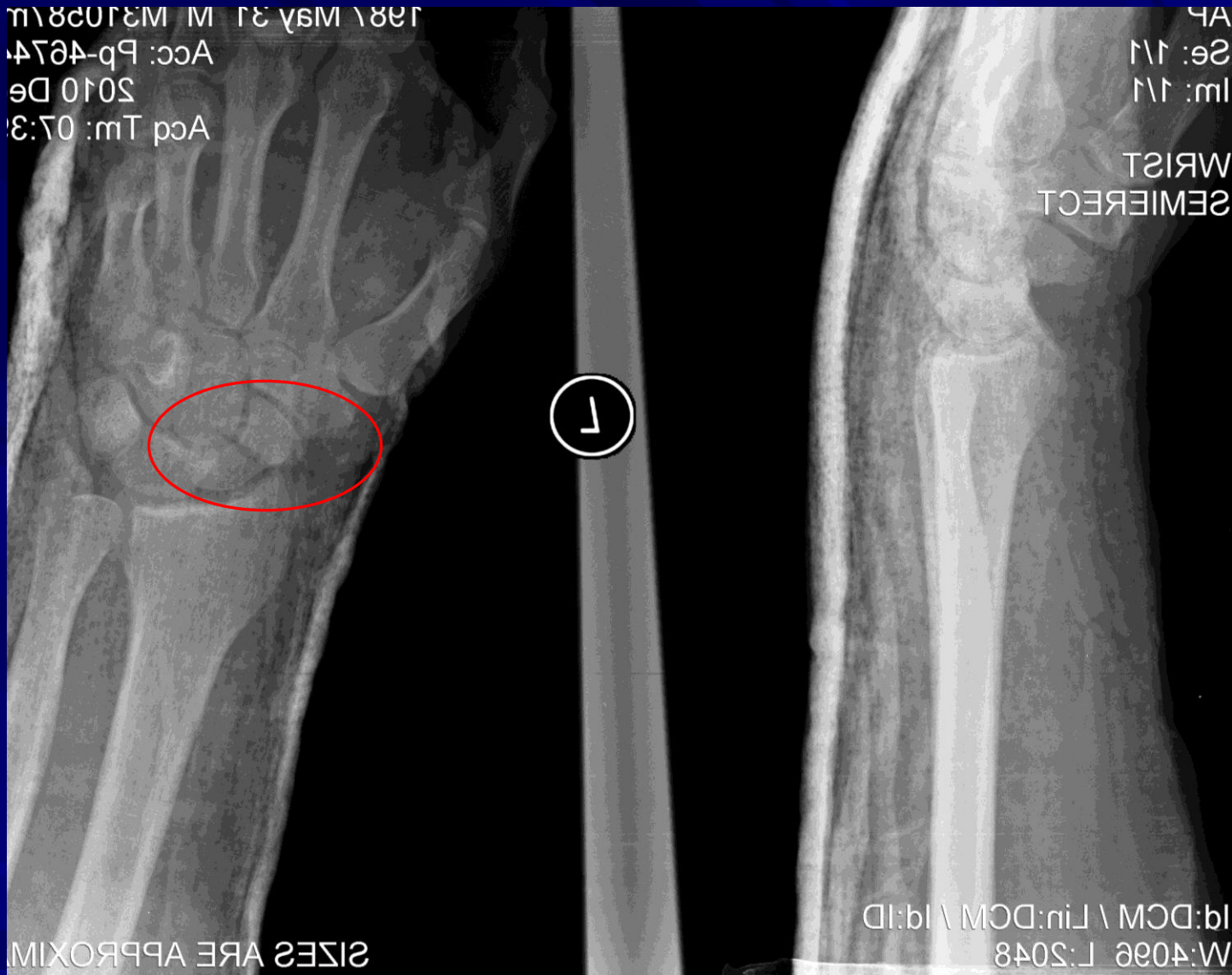
Patient M., 28 years old, officer, the transscaphoid perilunate fracture-dislocation



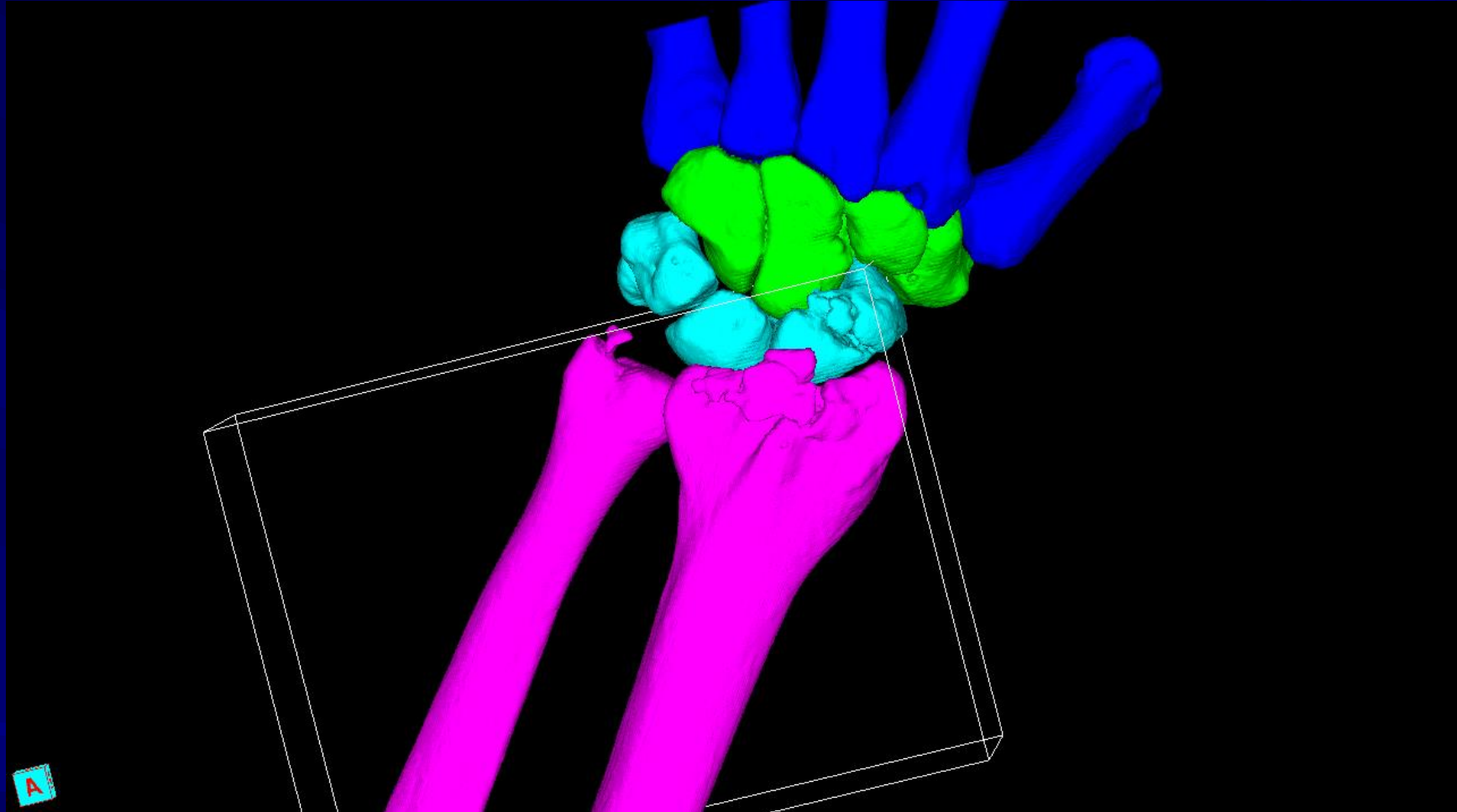
After open reduction of carpal dislocation
and of the scaphoid fragments

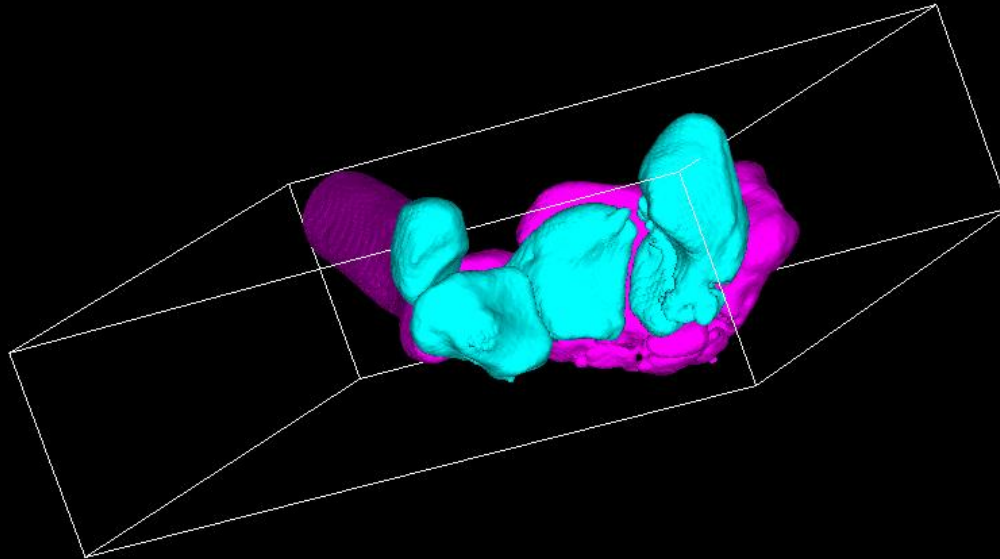


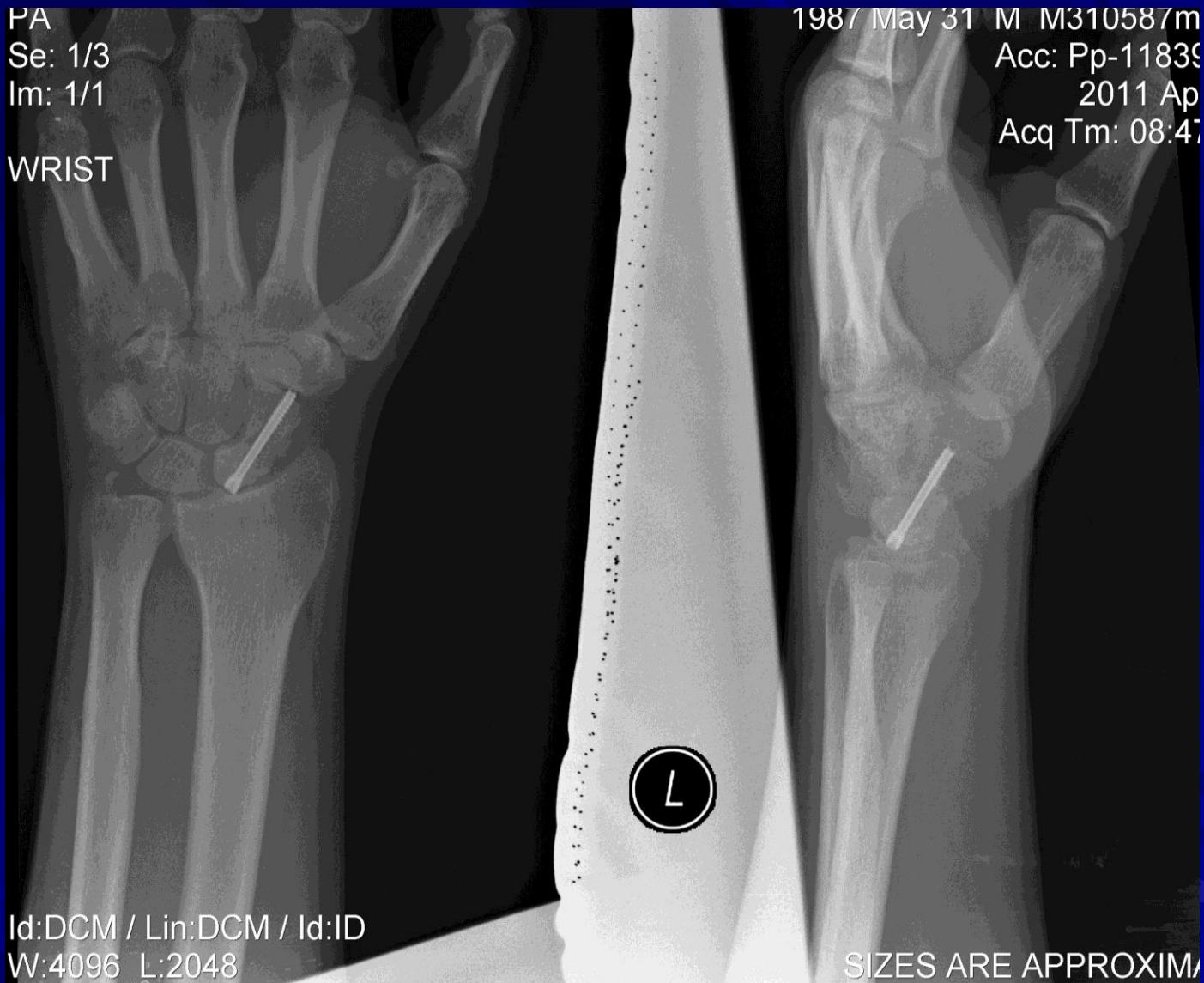Result 3 months after operation



Patient M, 24 years old, employee, remaining dislocation of the scaphoid fragments





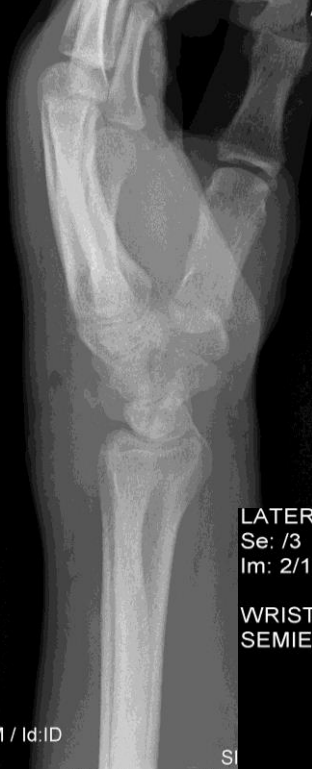

2 months after antegrade canulated osteosynthesis , signs of the fragments consolidation

Se: /3

Im: 1/1
WRIST
SEMIERECT

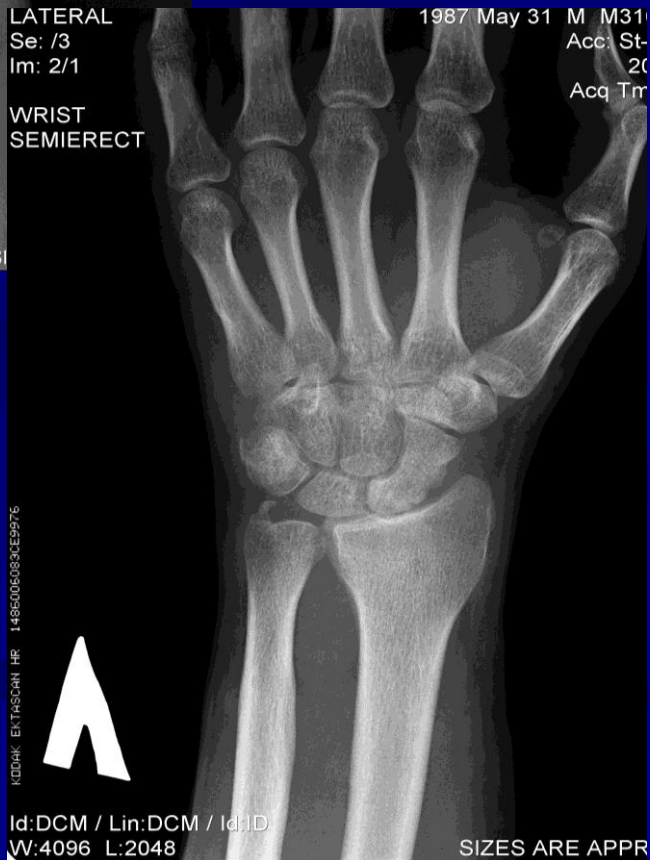Acc: St-5-177
2011 A
Acq Tm: 13:00



Id:DCM / Lin:DCM / Id:ID
W:4096 L:2048

LATERAL
Se: /3
Im: 2/1
1987 May 31 M M31
Acc: St-
20
Acq Tm

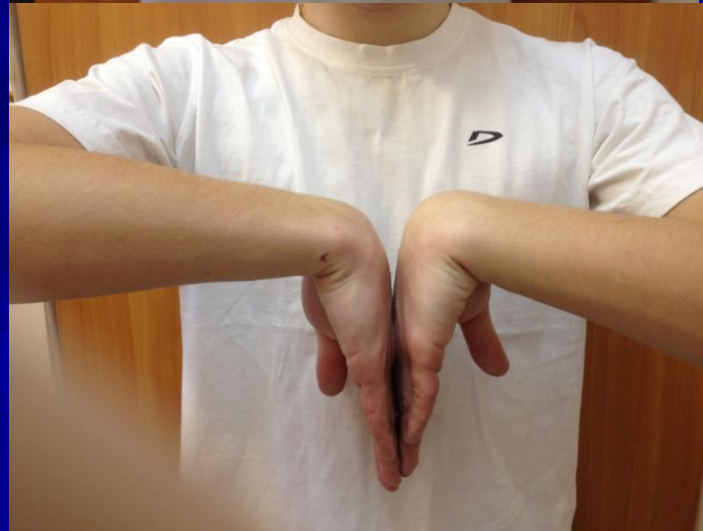WRIST
SEMIERECT



Id:DCM / Lin:DCM / Id:ID
W:4096 L:2048

SIZES ARE APPR

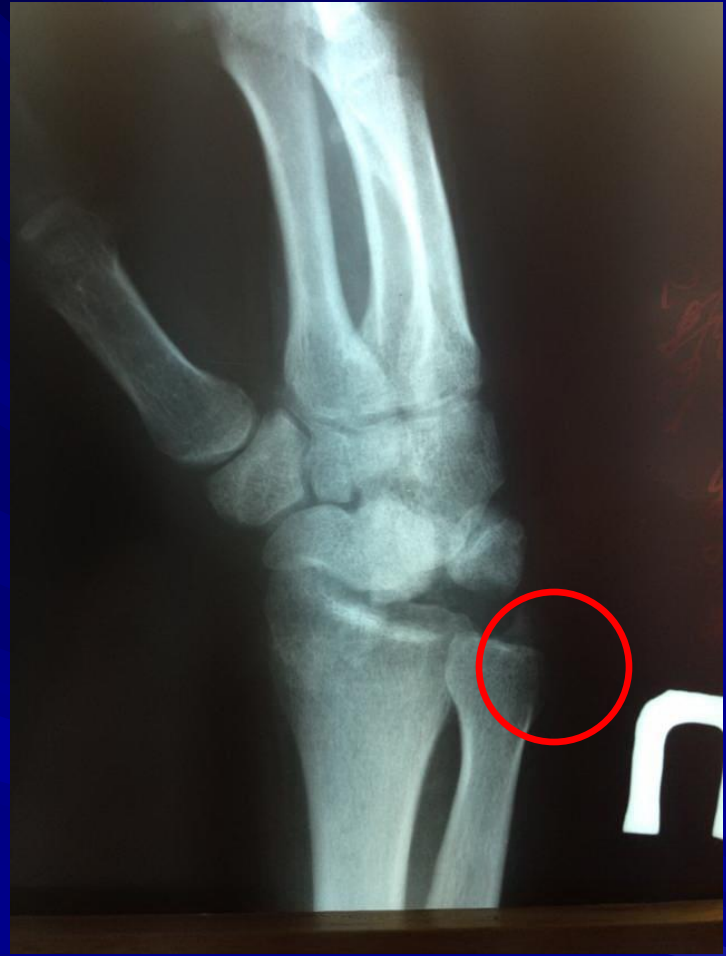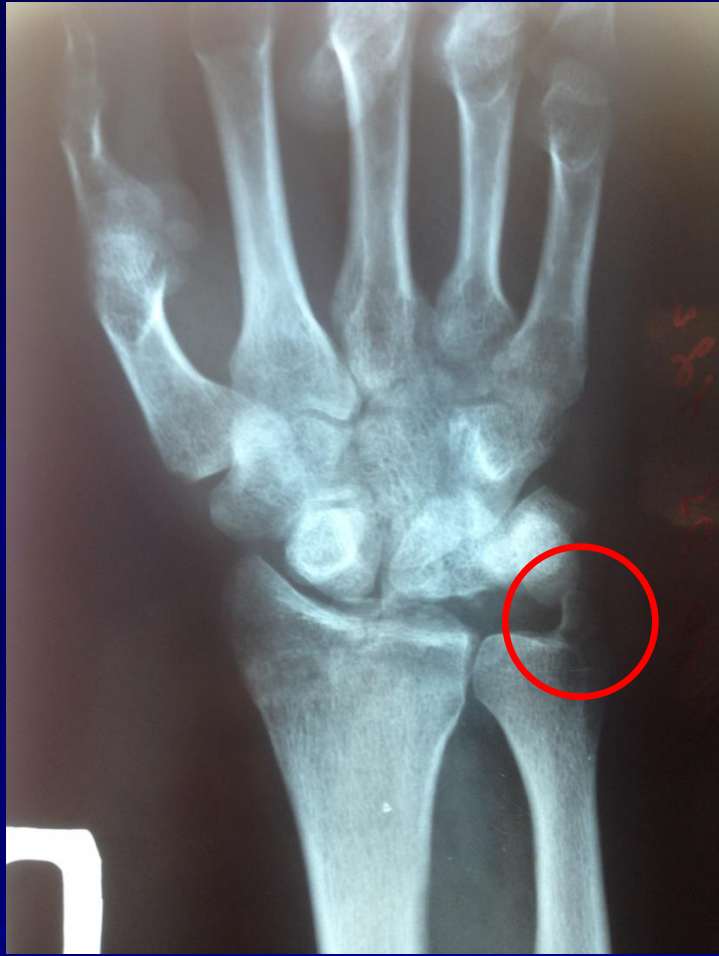KODAK EKTASCAN HR 14960060830CE976



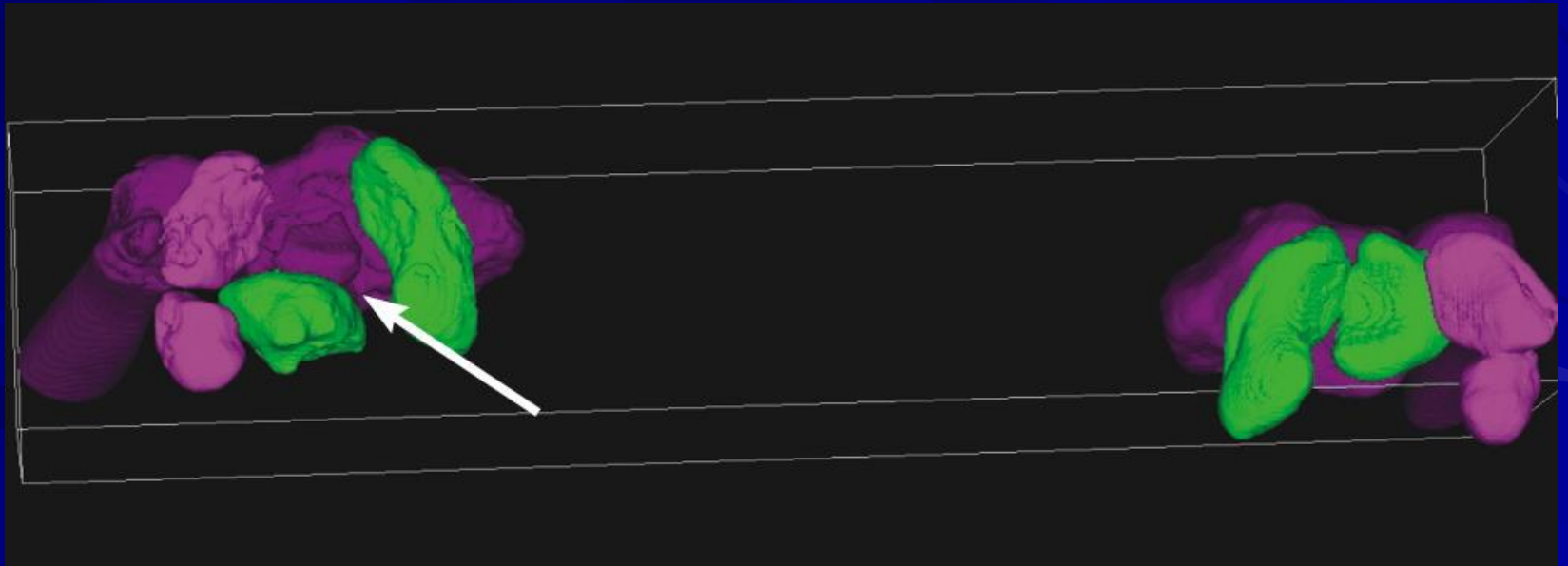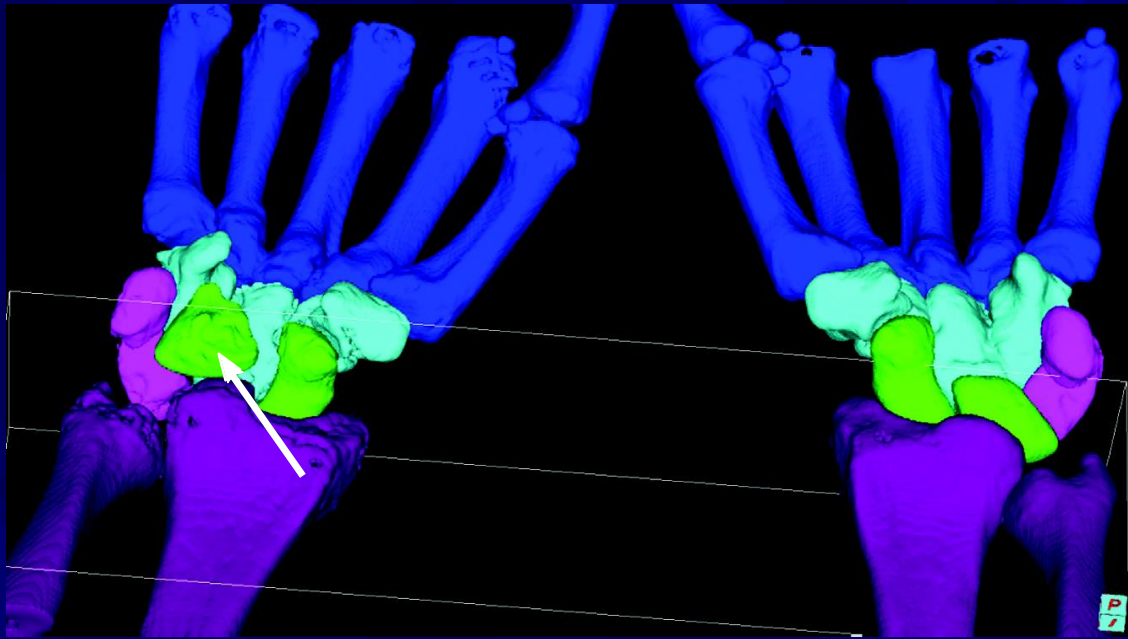
Functional result
11 months
after operation

Two-step Surgical Treatment

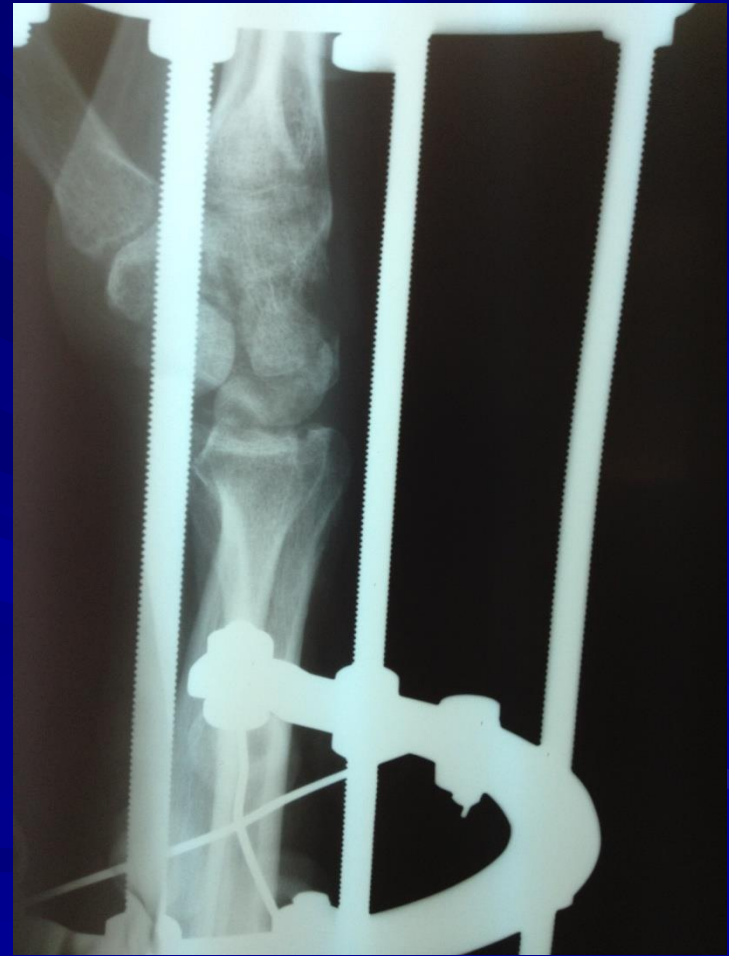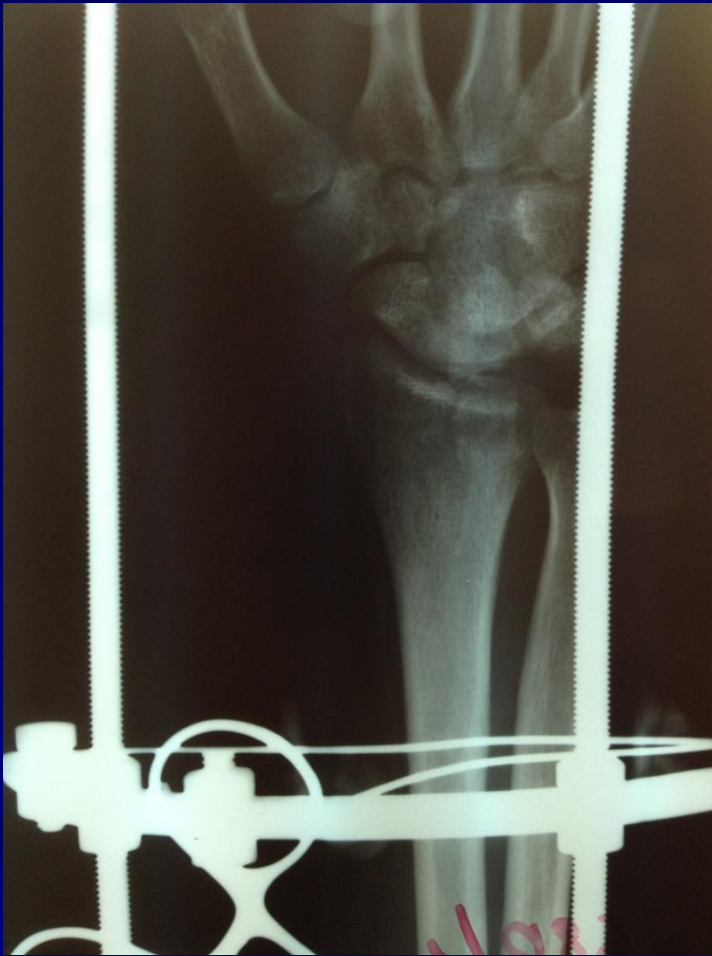- We gave up using additional closed manipulations in old cases; we also stopped using an open one-moment elimination; instead, we use a two-step method of surgical treatment:
- 1st step - ligamentotensia in Ilizarov's apparatus
- 2nd step - an open reconstruction of the injured anatomical elements of the wrist



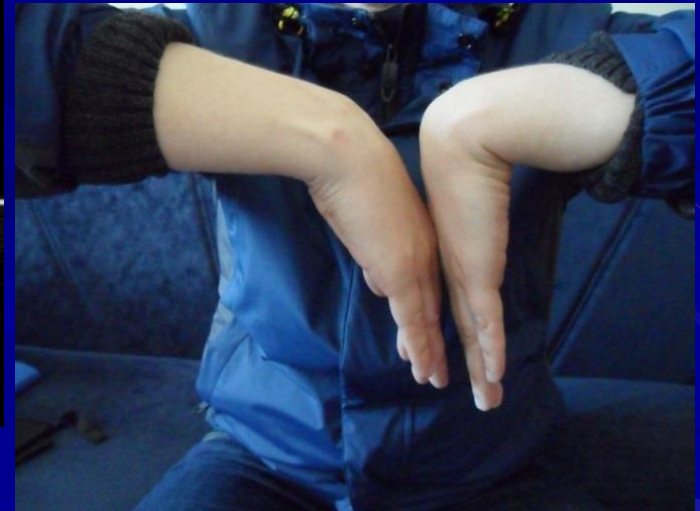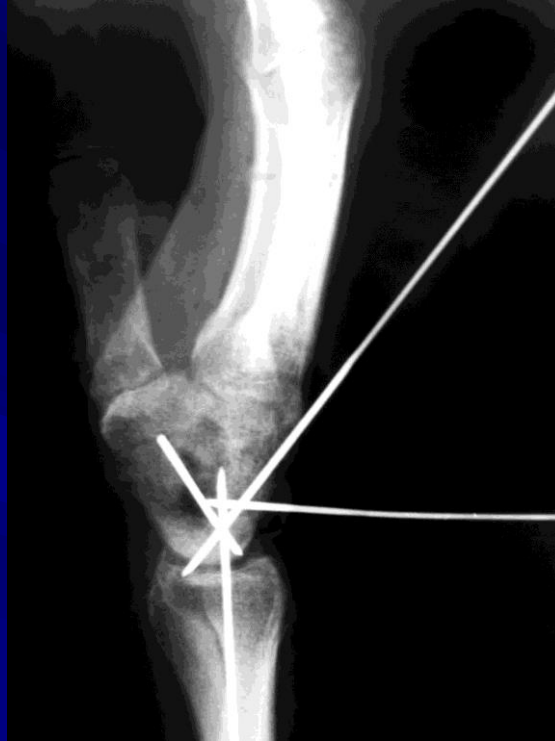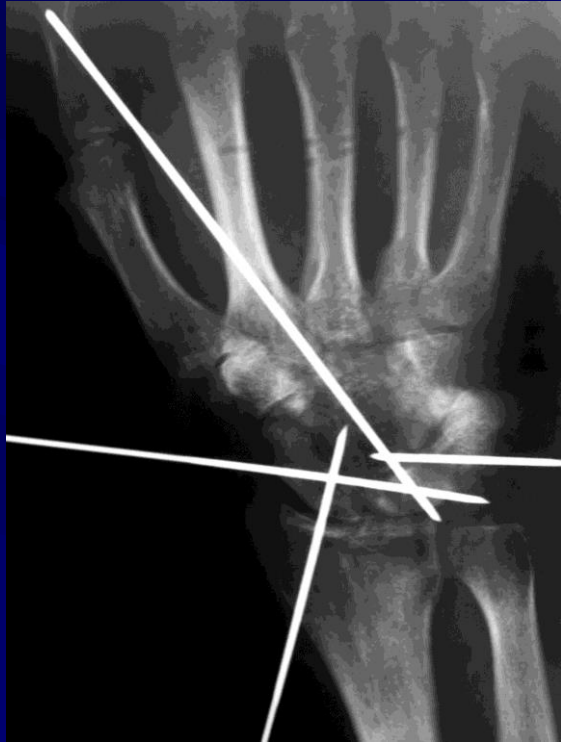Patient D, 24 years old, worker



1st step of surgical treatment



2nd step of surgical treatment



Results

- In most patients the short-term results were favourable
- The long-term results were estimated according to the Mayo Clinic modified estimation scale and DASH questionnaire
- The estimation median according to the Mayo Clinic scale was 90 (80-90) ($p < 0.001$)
- The score according to the DASH questionnaire was 5.8 (2.5-9.6) ($p < 0.01$)

Conclusions:

- Patients with signs of injury and a marked posttraumatic inflammatory syndrome require an additional complex examination including computer-based techniques: computer-based tomography and a 3D visualization; preoperative computerized modeling
- Using computer-based techniques provides an accurate verification of the carpal dislocation and creates conditions for an efficient preoperative planning;

Conclusions:

- Selecting the technique of rendering specialized traumatological aid must be strictly differentiated according to the injury type and its duration;
- Preoperative planning followed by a miniinvasive and gentle surgical technique is the basis of an efficient prevention of posttraumatic osteoarthritis of the wrist joint

Thank you for attention!

